

Review Article

Alexandros Poutoglidis takes responsibility for the integrity of the content of the paper

Cite this article: Poutoglidis A, Forozidou E, Fyrmipas G, Vlachtsis K, Karamitsou P. The indications, surgical techniques, and complications of transoral robotic surgery in total laryngectomy: a systematic review. *J Laryngol Otol* 2024;1–6. <https://doi.org/10.1017/S0022215124000641>

Received: 14 December 2023

Revised: 3 February 2024

Accepted: 25 February 2024



Keywords:

Surgical oncology; robotic surgical procedures; laryngectomy; cutaneous fistula

Corresponding author:

Alexandros Poutoglidis;
Email: xilouris21@gmail.com

The indications, surgical techniques, and complications of transoral robotic surgery in total laryngectomy: a systematic review

Alexandros Poutoglidis¹ , Evropi Forozidou², Georgios Fyrmipas³,
Konstantinos Vlachtsis⁴ and Paraskevi Karamitsou² 

¹Department of Anatomy and Surgical Anatomy, Faculty of Health Sciences, Medical School, Aristotle University of Thessaloniki, Thessaloniki, Greece, ²Department of Otorhinolaryngology–Head and Neck Surgery, ‘G. Papanikolaou’ General Hospital, Thessaloniki, Greece, ³Department of Otorhinolaryngology–Head and Neck Surgery, Medical School, Democritus University of Thrace, Alexandroupoli, Greece and ⁴Department of Otorhinolaryngology–Head and Neck Surgery, ‘G. Gennimatas’ General Hospital, Thessaloniki, Greece

Abstract

Objective. Transoral robotic surgery total laryngectomy is a promising procedure. We conducted a systematic review to study the indications, surgical techniques and complications of this procedure.

Methods. We followed the guidelines outlined in the Preferred Reporting Items for Systematic Reviews and Meta-Analysis statement.

Results. We concluded with 5 studies and 27 surgeries. The main indications of transoral robotic surgery total laryngectomy were selected recurrent laryngeal squamous cell carcinomas, dysfunctional larynx, and specific primary non-squamous cell carcinoma laryngeal cancers. The rate of pharyngocutaneous fistula was 20 per cent overall. In every reported cancer case, the specimen was excised within negative surgical margins. The average time of the procedure was 282.6 minutes.

Conclusion. Transoral robotic surgery total laryngectomy is a safe procedure of high value. The preservation of strap muscles and hyoid bone as well as the sacrifice of less mucosa compared to the traditional technique reduces the risk of certain complications and improves the swallowing outcome.

Introduction

Laryngeal cancer is one of the most common head and neck cancers, accounting for over 150,000 new cases per year globally.¹ The vast majority of cases are squamous cell carcinomas (SCCs) and often patients present in advanced disease stage with severe obstruction and dyspnea.²

Advanced laryngeal cancer is mainly treated surgically. Total laryngectomy is strongly recommended for salvage cases or Stage IV locally advanced laryngeal SCC.² In addition, laryngeal sarcomas or salivary gland tumours of the larynx are treated surgically even in their early stages.³ The loss of the larynx is considered a major disability with implications for the quality of life. Therefore, a variety of minimally invasive procedures such as partial laryngectomies (when oncologically sound) have been developed to avoid aphonia (which may be restored partially with a speaking valve, oesophageal speech, or electrolarynx) and permanent tracheostomy.⁴ Preservation of part of the laryngeal apparatus may be beneficial for the patient, reducing the negative effect on their quality of life. However, total laryngectomy is often inevitable for oncological or functional purposes. Post-radiation larynges often have to be sacrificed because of chondronecrosis even in cases with no recurrent or residual disease. Organ preservation strategies with concomitant chemoradiation have also been suggested,⁵ but they should not be considered safe for Stage IV SCC, as they negatively affect survival outcome.⁶

Advances in technology have been integrated into laryngeal surgery. Transoral laser microsurgery is considered for cordectomies and partial laryngectomies with excellent results.⁷ Transoral robotic surgery offers even more advantages in laryngeal cancer. Wristed instruments and flexible endoscopes allow better exposure, magnification and visualization of the field than transoral laser microsurgery, and enhance the dexterity of the surgeons and filtrate their tremor when present.⁸ Transoral excision of the larynx is not the future but the present for a minor patient group with certain indications. Our systematic review aims to shed light on the current outcomes of transoral robotic surgery total laryngectomy, assessing its value and demonstrating its limitations.

Materials and methods

We examined patients who underwent total laryngectomy (population) with the assistance of transoral robotic surgery (exposure) for their indications, the surgical techniques and

complications (outcome).⁹ We conducted this systematic review according to the statement of the Preferred Reporting Items for Systematic Reviews and Meta-Analysis ('PRISMA') and as recommended by the Cochrane Collaboration. Case series of patients who underwent robotic total laryngectomy were identified. Searching did not include language or time restrictions.

A comprehensive electronic search of MEDLINE, Google Scholar, and Cochrane Library electronic databases was performed from 1 September 2023 to 30 September 2023 to identify publications relevant to the research question. The reference list of every relevant original study about robotic or robotic-assisted total laryngectomy and all full-text articles detected for inclusion were also meticulously searched and evaluated for relevance to increase the sensitivity of our study. Informed consent and ethical approval from our institution was not required because of the nature of our study (systematic review).

Two authors conducted the literature search separately. The free-text terms used for the MEDLINE, Google Scholar, and Cochrane Library databases search were:

(total laryngectomy) OR (salvage laryngectomy) OR (primary laryngectomy) OR (laryngeal cancer) OR (functional laryngectomy) AND (TORS) OR (robotic surgery)

The inclusion of each study was decided independently by the two authors, and in case of any disagreement, the solution was achieved after consensus. Inclusion and exclusion criteria were determined before searching the literature as the recommended guidelines. The inclusion criteria were: (1) studies reporting transoral robotic surgery laryngectomy and (2)

studies reporting transoral robotic surgery-assisting laryngectomy. Exclusion criteria were: (1) cadaveric studies, (2) animal studies, and (3) studies with insufficient data.

All identified case series were evaluated separately for eligibility by the reviewers according to the selected criteria for inclusion or exclusion. Every eligible original article was retrieved. An extraction sheet was employed to record the following characteristics of the included data: demographic characteristics, first author, year of publication, country of the study, indications, surgical techniques and time of surgery, staging in cases of cancer, comorbidities, indications, surgical techniques and time of surgery, outcome, complications, hospital stay, and follow-up information.

Indications, surgical techniques, and complications were the primary outcomes to evaluate the role of transoral robotic surgery in total laryngectomy. The Murad *et al.*¹⁰ assessment tool was used to assess the methodology of the included case series.¹⁰ After consensus and analysis, studies were evaluated for their potential risk of bias.

Results

The initial literature search of our systematic review resulted in a total of 5854 articles. After excluding the duplicates (859), the remaining articles (4995) were evaluated for eligibility according to their title and abstract. After meticulous screening, 4850 articles were excluded because they were irrelevant to our pre-determined inclusion criteria or belonged to our exclusion criteria. One hundred forty-five studies were selected for extraction, but four of them could not be retrieved. The full

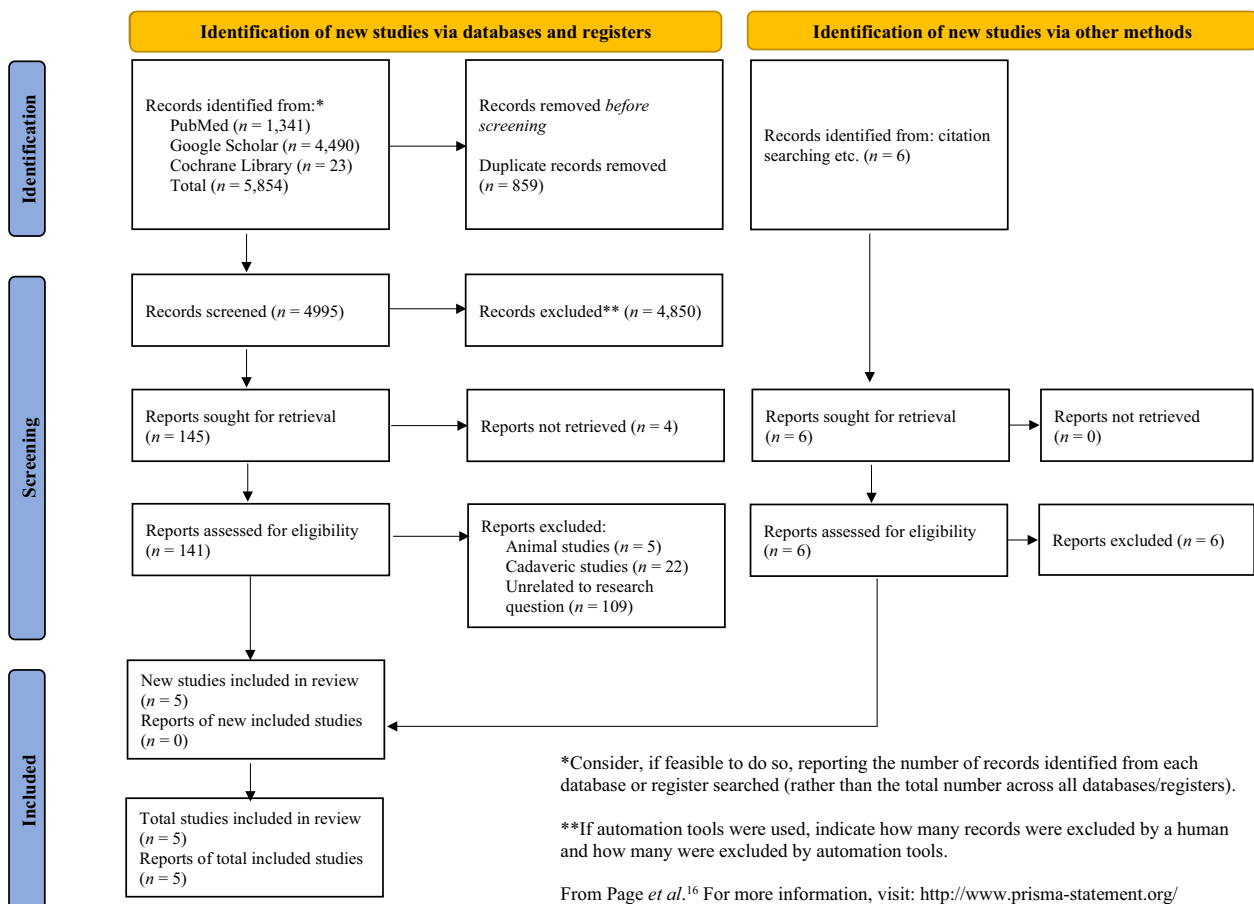


Figure 1. Preferred Reporting Items for Systematic Reviews and Meta-Analysis ('PRISMA') 2020 flow diagram for updated systematic reviews which included searches of databases, registers and other sources.

Table 1. Demographic characteristics of the included studies

Authors	Year	Country	n	Mean age years (range)	Gender (male/female)
Dowthwaite <i>et al.</i> ¹¹	2013	Canada	3	55.3 (38–65)	2/1
Smith <i>et al.</i> ¹²	2013	USA	7	61.9 (38–79)	6/1
Krishnan and Krishnan ¹³	2017	Australia	5	54 (22–80)	3/2
Lawson <i>et al.</i> ¹⁴	2018	Belgium	2	N/R	N/R
Hans <i>et al.</i> ¹⁵	2021	France	10	62.2 (48–70)	8/2
Total	—	—	27	59.6 (22–80)	19/6

n = population size; N/R = not reported

texts of the remaining 141 studies were evaluated and finally, 5 eligible publications were chosen. In addition, six studies were detected through the reference lists of the retrieved studies but none of them was finally deemed for inclusion. Figure 1 depicts the flow chart of our systematic review which ended with five selected articles.^{11–15}

The studies were performed in America, Europe, and Oceania and published between 2013 and 2021. The population of transoral robotic surgery total laryngectomies ranged from 2 to 10. The overall number of laryngectomies was 27. The largest study included 10 cases and was performed by Hans *et al.* in 2021.¹⁵ The average age of patients who underwent a transoral robotic surgery total laryngectomy was 59.6 years and ranged from 22 to 80 years. The male-to-female ratio was 19:6. The demographic characteristics of the study are shown in Table 1.

The most common indication for transoral robotic surgery total laryngectomy was the recurrence of a laryngeal SCC (salvage laryngectomy) (44.4 per cent), followed by laryngeal dysfunction after conservative treatment (33.3 per cent), and laryngeal non-SCC (adenoid cystic carcinoma or chondrosarcoma) (22.2 per cent). All cases were presented with clinically

negative neck and 46.2 per cent of them were staged as T3, followed by T2 (38.4 per cent), T1 (7.7 per cent), and T4a (7.7 per cent). Sixty-eight per cent of patients had no comorbidities while 32 per cent of patients had either pathologic comorbidities or a second primary. Table 2 shows the preoperative characteristics of the included studies.

Total laryngectomies were primary in 37 per cent of cases and salvage in 62.3 per cent. Three out of 27 cases were converted to open procedures because of inadequate exposure. The mean time of surgery was 282.6 minutes and ranged from 226 to 370 minutes. The histopathology (when reported) demonstrated in all cases negative resection margins. Table 3 lists the perioperative characteristics of the studies.

The surgical incision was always shorter than 5 cm. Exposure was mainly achieved with a Feyh–Kastenbauer retractor. Crow–Davies and Maryland retractors were also used. In four out of five studies, the strap muscles were preserved (the only exception was the study of Krishnan and Krishnan.¹³) Three studies^{12,14,15} reported formal intra-oral ligation of the superior laryngeal artery while the other two studies^{11,13} did not report how they dealt with the artery. Larynges were designed to be delivered intra-orally in every study except the Krishnan and Krishnan cases.¹³ Pharyngeal closure was performed intra-orally, mostly with 3-0 Vicryl sutures (Ethicon, Bridgewater, New Jersey, USA). The unique

Table 2. Individual characteristics of cases

Gender	Mean age years (range)
– Male	59.8 (41–80)
– Female	50 (22–65)
Indication	n (%)
– Recurrent SCC	12 (44.4)
– Dysfunctional larynx	9 (33.3)
– Non-SCC laryngeal cancer	6 (22.2)
Clinical staging (SCC or AdCC)	
– T1N0M0	1 (7.7)
– T2N0M0	5 (38.4)
– T3N0M0	6 (46.2)
– T4aN0M0	1 (7.7)
Comorbidities	
– Hepatic	2 (8.0)
– Pulmonary	3 (12.0)
– Diabetes	1 (4.0)
– Neurologic	1 (4.0)
– Second primary	1 (4.0)
– No	17 (68.0)

*n = population size; SCC = squamous cell carcinoma; AdCC = adenoid cystic carcinoma

Table 3. Treatment modalities

Prior therapy	n (%)
– No	10 (37.0)
– Radiation	6 (22.2)
– Chemoradiation	11 (40.7)
Conversion to open surgery	
– Yes	3 (11.1)
– No	24 (88.9)
Time of procedure	Minutes
– Mean	282.6
– Range	226–370
Type of surgery	
– Primary	10 (37.0)
– Salvage	17 (62.3)
Surgical margins (in case of cancer)	
– Negative	17 (100.0)
– Positive	0 (0.0)

n = population size

Table 4. Surgical techniques of transoral robotic surgery total laryngectomy

Authors	Cervical incision	Retractors	Strap muscles	SLA	Laryngeal delivery	Pharyngotomy closure
Dowthwaite <i>et al.</i> ¹¹	5-cm stomal incision	FK	Preserved	N/R	Intra-orally	T-shaped transoral 3-0 Vicryl
Smith <i>et al.</i> ¹² Hans <i>et al.</i> ¹⁵	Small incision between cricoid cartilage and suprasternal notch	FK or CD	Preserved	Intra-oral clipping	Intra-orally	Horizontal transoral 3-0 Vicryl
Krishnan & Krishnan ¹³	2-cm stomal incision	FK	Transected	N/R	Transcervically	Transoral 3-0 V-lock sutures
Lawson <i>et al.</i> ¹⁴	4-cm stomal incision	Maryland	Preserved	Intra-oral clipping	Intra-orally	Horizontal 3-0 braided sutures

*Smith *et al.*¹² and Hans *et al.*¹⁵ used the same technique; N/R = not reported; SLA = superior laryngeal artery; FK = Feyh-Kastenbauer; CD = Crow-Davis

surgical techniques of every transoral robotic surgery total laryngectomy are presented in Table 4.

The main serious complication of transoral robotic surgery total laryngectomy was the development of a pharyngocutaneous fistula in 20 per cent of cases. Pharyngocutaneous fistulas were presented with the same frequency in primary and salvage laryngectomies. Bleeding was reported in only 8 per cent of cases, and only 1 case needed surgical management. No patient needed a permanent gastrostomy, and the average hospital stay was 12.9 days. Table 5 lists the complications and postoperative characteristics of the included studies.

The Murad *et al.*¹⁰ evaluation tool was used to assess the reliability and quality of the included articles. Our evaluation tool indicated that four studies^{11–13,15} have a low risk of bias, while one study has an unclear risk of bias.¹⁴ Table 6 presents the evaluation of every included study.

Discussion

Classic total laryngectomy is a transcervical procedure requiring a large skin incision, transection of the strap muscles and excision of the hyoid bone. The location of the tumour determines the surgical steps used to save as much healthy tissue as possible. Therefore, open laryngeal surgery approaches the tumour from the “blind side” and, lacking the depth of information that can be extracted intra-operatively, the surgeon is not able to recognize the lesion until the late stages of the procedure.²

In contrast, transoral robotic surgery total laryngectomy provides immediate exposure of the tumour and helps the surgeon to save as much mucosa as possible. The strap muscles and hyoid bone are not violated. The field is magnified and tissues maintain a standard position. Theoretically speaking, all these modifications may lead to lower rates of pharyngocutaneous fistulas and better cosmetical and functional outcomes.^{12,15} It should be noted that narrow field total laryngectomy also does not violate the hyoid bone and the integrity of the strap muscles.

Neck involvement is often in laryngeal SCC, making neck dissection imperative in cases with cN1+ neck. In addition, almost every primary total laryngectomy for SCC should be accompanied by at least ipsilateral neck dissection, even in cN0 cases.² Therefore, the advantage of the short incision during transoral robotic surgery total laryngectomy cannot be exploited in cases requiring neck management. According to our systematic review, transoral robotic surgery total laryngectomy has never been performed in cases where neck management was mandatory. Indications of transoral robotic

surgery total laryngectomy include salvage cases for selected cT3 or less, N0M0, dysfunctional larynx after organ preservation strategies, and some rare laryngeal neoplasms of the larynx with very low regional metastatic potential such as low-grade adenoid cystic carcinomas and low-grade chondrosarcomas. Most T3 and almost all T4a tumours should not be considered for transoral robotic surgery total laryngectomy, because the infiltration of laryngeal cartilages, pre-epiglottic space invasion, and every extralaryngeal extension are absolute contradictions.^{11–15}

Surgical time is a major limitation in transoral robotic surgery total laryngectomy. The presented data report time ranges from 226 to 370 minutes.^{11–15} Classic open total laryngectomy without neck dissection is a much shorter procedure.¹⁷ However data should be interpreted carefully. The specimens of transoral robotic surgery total laryngectomy are much smaller than they are in classic open surgery.¹⁵ A smaller specimen limits the application of transoral robotic surgery to smaller tumours but offers the advantage that a prophylactic flap is not required. Preserved strap muscles consist of a natural enhancement of the neopharynx. Because most cases of transoral robotic surgery total laryngectomies are salvage cases or cases with a dysfunctional larynx after radiation failure, the time of a classic open procedure often included the routine use of a regional flap.¹⁸ Therefore, the time to harvest a prophylactic flap is saved.

Pharyngocutaneous fistula formation after total laryngectomy is a serious and dangerous complication with high

Table 5. Complications and postoperative outcomes

Complications	n (%)
– Pharyngocutaneous fistula	5 (20.0)
– Bleeding	2 (8.0)
– No	18 (72.0)
Pharyngocutaneous fistula per surgery	n (%)
– Primary	2 (20.0)
– Salvage	3 (20.0)
Permanent gastrostomy dependence	n (%)
– Yes	0 (0.00)
– No	25 (100.0)
Hospital stay	Days
– Mean	12.92

n = Population

Table 6. Quality assessment of the included studies

Authors	Selection	Ascertainment	Causality	Reporting	Overall risk of bias (low/high/unclear)
Dowthwaite <i>et al.</i> ¹¹	Yes	Yes	No	Yes	Low
Smith <i>et al.</i> ¹²	Yes	Yes	Unclear	Yes	Low
Krishnan & Krishnan ¹³	Yes	Yes	Yes	Yes	Low
Lawson <i>et al.</i> ¹⁴	Unclear	Yes	No	Unclear	Unclear
Hans <i>et al.</i> ¹⁵	Yes	Yes	Unclear	Yes	Low

Selection: (1) Does the patient represent the whole experience of the investigator (centre) or is the selection method unclear as to the extent that other patients with similar presentation may not have been reported?

Ascertainment: (2) Was the exposure adequately ascertained? (3) Was the outcome adequately ascertained?

Causality: (4) Were alternative causes that might have explained the observation ruled out? (5) Was there a challenge/rechallenge phenomenon? (6) Was there a dose-response effect? (7) Was follow up long enough for outcomes to occur?

Reporting: (8) Is the case described with sufficient details to allow other investigators to replicate the research or to allow practitioners to make inferences related to their own practice?

morbidity.¹⁹ It is related to multiple predisposing factors (prior radiation therapy, low haemoglobin levels, diabetes, positive surgical margins, tension in pharyngeal closure and/or T-closure of neopharynx). Intra-oral transoral robotic surgery total laryngectomy eliminates some of these predisposing factors by saving healthier mucosa than is done using traditional transcervical total laryngectomy. The strap muscles are preserved, and the pharyngeal closure is easier to be performed in a more horizontal fashion, limiting the tension in the neopharynx. According to the literature, the rate of pharyngocutaneous fistula formation is very high in salvage cases even when a prophylactic flap is recruited.^{20,21} Our results demonstrate a risk of 20 per cent in transoral robotic surgery salvage total laryngectomies, but the data are not adequate to draw safe conclusions. This percentage should be considered high if we have in mind that the procedure is indicated in a selected group and promises certain advantages.

The achievement of negative surgical margins of resection is the cornerstone of the surgical oncologic practice. Positive surgical margins are always associated with lower survival rates. Transoral robotic surgery total laryngectomy resulted in negative margins in every reported case. However, in the series of Hans *et al.*¹⁵, one patient developed a local recurrence of chondrosarcoma. This phenomenon was attributed to contamination of the field due to the close incision of the thyroid and cricoid cartilage.

- Transoral robotic surgery total laryngectomy is indicated in selected salvage cases of squamous cell carcinoma cancers, in dysfunctional larynges, and in rare primary carcinomas with low metastatic regional potential
- Transoral robotic surgery total laryngectomy necessitates more time than traditional total laryngectomy (median time 282.6 minutes); the larynx was delivered intraorally in most cases
- The rate of pharyngocutaneous fistula is 20 per cent and no other major complications have been reported
- The strap muscles and hyoid bone are preserved during transoral robotic surgery total laryngectomy, theoretically leading to a better swallowing outcome

Although there is much enthusiasm for the adaptation of transoral robotic surgery in head and neck procedures, there is still scepticism about the cost. The use of transoral robotic surgery is not free, and surgeons must be aware of this. According to a study by Dombree *et al.*,²² transoral robotic surgery total laryngectomies are significantly more expensive than the traditional open procedures. Specifically, the overall cost of a transoral robotic surgery total laryngectomy was calculated at approximately €6767 compared to €3581 for an

open approach. The authors stated that the cost is mainly affected by equipment purchase and maintenance.²²

Our systematic review has certain limitations. Firstly, the included studies are retrospective and present limited cases. Sparse data in the literature reflect the difficulty of transoral robotic surgery total laryngectomy and its restricted indications. The limited data make it difficult to compare transoral robotic surgery total laryngectomy results to those of large cohort studies of traditional total laryngectomies. In addition, the presented studies had significant differences in important surgical steps and therefore did not use the same technique to excise the larynx. These differences reduce the homogeneity of our data. Finally, the lack of information on swallowing outcome, follow-up status and voice rehabilitation restricts our conclusion regarding some very critical and interesting outcomes of this procedure.

Conclusion

Our systematic review demonstrated the value of transoral robotic surgery total laryngectomy as a minimally invasive technique with multiple advantages in oncological, functional and complication outcomes. The widespread use of transoral robotic surgery should be undertaken with caution because the indications are limited to selected recurrent SCC laryngeal cancer, dysfunctional larynges and primary non-SCC laryngeal cancer with low or no regional metastatic potential. Time of surgery should not be considered a main limitation because transoral robotic surgery surgery does not require flap reinforcement. Future research for swallowing and voice outcomes should be conducted to further assess the value of transoral robotic surgery total laryngectomy.

Data availability statement. This is a systematic review. The data were collected after downloading the included studies. We worked with these data using Excel. The data are available and can be provided upon request.

Competing interests. The authors declare no competing interests.

References

- 1 Ferlay J, Soerjomataram I, Dikshit R, Eser S, Mathers C, Rebelo M *et al.* Cancer incidence and mortality world- wide: sources, methods and major patterns in GLOBOCAN 2012. *Int J Cancer* 2015;**136**:359–86
- 2 Tsetsos N, Poutoglidis A, Vlachtsis K, Stavarakas M, Nikolaou A, Fyrmpas G. Twenty-year experience with salvage total laryngectomy: lessons learned. *J Laryngol Otol* 2021;**135**:729–36
- 3 Marchiano E, Chin OY, Fang CH, Park RC, Baredes S, Eloy JA. Laryngeal adenoid cystic carcinoma: a systematic review. *Otolaryngol Head Neck Surg* 2016;**154**:433–9

- 4 Succo G, Peretti G, Piazza C, Remacle M, Eckel HE, Chevalier D *et al.* Open partial horizontal laryngectomies: a proposal for classification by the working committee on nomenclature of the European Laryngological Society. *Eur Arch Otorhinolaryngol* 2014;**271**:2489–96
- 5 Department of Veterans Affairs Laryngeal Cancer Study Group; Wolf GT, Fisher SG, Hong WK, Hillman R, Spaulding M *et al.* Induction chemotherapy plus radiation compared with surgery plus radiation in patients with advanced laryngeal cancer. *N Engl J Med* 1991;**324**:1685–90
- 6 Tang ZX, Gong JL, Wang YH, Li ZH, He Y, Liu YX *et al.* Efficacy comparison between primary total laryngectomy and nonsurgical organ-preservation strategies in treatment of advanced stage laryngeal cancer: a meta-analysis. *Medicine (Baltimore)* 2018;**97**:e10625
- 7 Russo E, Costantino A, Veneroni MV, Festa BM, Pellini R, Campo F *et al.* Transoral laser microsurgery in recurrent laryngeal cancer: a systematic review and meta-analysis. *Laryngoscope* 2023;**133**:1425–33
- 8 Lechien JR, Fakhry N, Saussez S, Chiesa-Estomba CM, Chekkoury-Idrissi Y, Cammaroto G *et al.* Surgical, clinical and functional outcomes of transoral robotic surgery for supraglottic laryngeal cancers: a systematic review. *Oral Oncol* 2020;**109**:104848
- 9 Moola S, Munn Z, Sears K, Stetcu R, Currie M, Lisy K *et al.* Conducting systematic reviews of association (etiology): the Joanna Briggs Institute's approach. *Int J Evid Based Healthc* 2015;**13**:163–9
- 10 Murad MH, Sultan S, Haffar S, Bazerbachi F. Methodological quality and synthesis of case series and case reports. *BMJ Evid Based Med* 2018;**23**:60–3
- 11 Dowthwaite S, Nichols AC, Yoo J, Smith RV, Dhaliwal S, Basmaji J *et al.* Transoral robotic total laryngectomy: report of 3 cases. *Head Neck* 2013;**35**:E338–42
- 12 Smith RV, Schiff BA, Sarta C, Hans S, Brasnu D. Transoral robotic total laryngectomy. *Laryngoscope* 2013;**123**:678–82
- 13 Krishnan G, Krishnan S. Transoral robotic surgery total laryngectomy: evaluation of functional and survival outcomes in a retrospective case series at a single institution. *ORL J Otorhinolaryngol Relat Spec* 2017;**79**:191–201
- 14 Lawson G, Mendelsohn A, Fakhoury R, Van der Vorst S, Remacle M, Bachy V *et al.* Transoral robotic surgery total laryngectomy. *ORL J Otorhinolaryngol Relat Spec* 2018;**80**:171–7
- 15 Hans S, Chebib E, Chekkoury-Idrissi Y, Distinguin L, Circiu M, Vialatte de Pemille G *et al.* Surgical and oncological outcomes of transoral robotic total laryngectomy: a case series. *Oral Oncol* 2021;**121**:105511
- 16 Page MJ, McKenzie JE, Bossuyt PM, Boutron I, Hoffmann TC, Mulrow CD *et al.* The PRISMA 2020 statement: an updated guideline for reporting systematic reviews. *BMJ* 2021;**372**:n71.
- 17 Laccourreye O, Crevier-Buchman L, Hacquart N, Naudo P, Muscatello L, Brasnu D. Laryngectomies and pharyngo-laryngectomies with tracheo-laryngo-pharyngeal shunt of Pearson type. Technique, indications and preliminary results [in French]. *Ann Otolaryngol Chir Cervicofac* 1996;**113**:261–8
- 18 Guimarães AV, Aires FT, Dedivitis RA, Kulcsar MAV, Ramos DN, Cernea CR *et al.* Efficacy of pectoralis major muscle flap for pharyngocutaneous fistula prevention in salvage total laryngectomy: a systematic review. *Head Neck* 2016;**38**(suppl 1):E2317–21
- 19 Rao KN, Arora RD, Singh A, Nagarkar NM, Aggarwal A. Pharyngocutaneous fistula following primary total laryngectomy: a meta-analysis. *Indian J Surg Oncol* 2022;**13**:797–808
- 20 Süslü N, Senirli RT, Günaydın RÖ, Özer S, Karakaya J, Hoşal AŞ. Pharyngocutaneous fistula after salvage laryngectomy. *Acta Otolaryngol* 2015;**135**:615–21
- 21 Hasan Z, Dwivedi RC, Gunaratne DA, Virk SA, Palme CE, Riffat F. Systematic review and meta-analysis of the complications of salvage total laryngectomy. *Eur J Surg Oncol* 2017;**43**:42–51
- 22 Dombree M, Crott R, Lawson G, Janne P, Castiaux A, Krug B. Cost comparison of open approach, transoral laser microsurgery and transoral robotic surgery for partial and total laryngectomies. *Eur Arch Otorhinolaryngol* 2014;**271**:2825–34