



High-Resolution Electrocardiography in Twins Affected by Situs Viscerum Specularis: Short Case Report

S. Villatico Campbell¹, F. Di Maio¹, M.E. Silvotti¹, A. Sciacca¹, G. Brenchi², L. Gedda²

¹Fourth Medical Clinic, University of Rome "La Sapienza", and ²The Mendel Institute, Rome, Italy

We previously studied a pair of MZ twins with situs viscerum inversus of the heart, liver and stomach, concordant with regard to all other factors normally utilized to diagnose zygoty [3]. We have now reexamined them after three years to evaluate the development of their cardiovascular system.

Our male MZ twins, now 17 years old, have been examined with high-resolution electrocardiography (HRE), treadmill stress test with Bruce protocol, tests stressing the cardiovascular system (cold pressure test, handgrip test, arithmetic mental test), and single and two-dimensional dynamic echocardiography after holter monitoring.

Atriogram analysis is made possible by HRE, that shows individual morphological reproducibility. Such reproducibility is present in both twins. In the dextrocardiac twin it is also present with the electrode position inverted. The similarity of morphology in the cotwins is further confirmed, even if such similarity is only apparent, in view of the fact that the vectors are spatially of opposite orientation, thereby causing an inversion of the electrical field [1-4]. The H-V interval is normal, although in the dextrocardiac twin it is longer (30 ms) than in his cotwin (25 ms). As regards the echocardiographic and dynamic ECG examination, normal data were obtained for both twins which were practically superposable to those obtained three years before.

REFERENCES

1. Bharati S, Lev M (1978): The course of the conduction system in dextrocardia. *Circulation* 57:1.
2. Dickinson DF, et al (1979): The cardiac conduction system in situs ambiguus. *Circulation* 59:5.

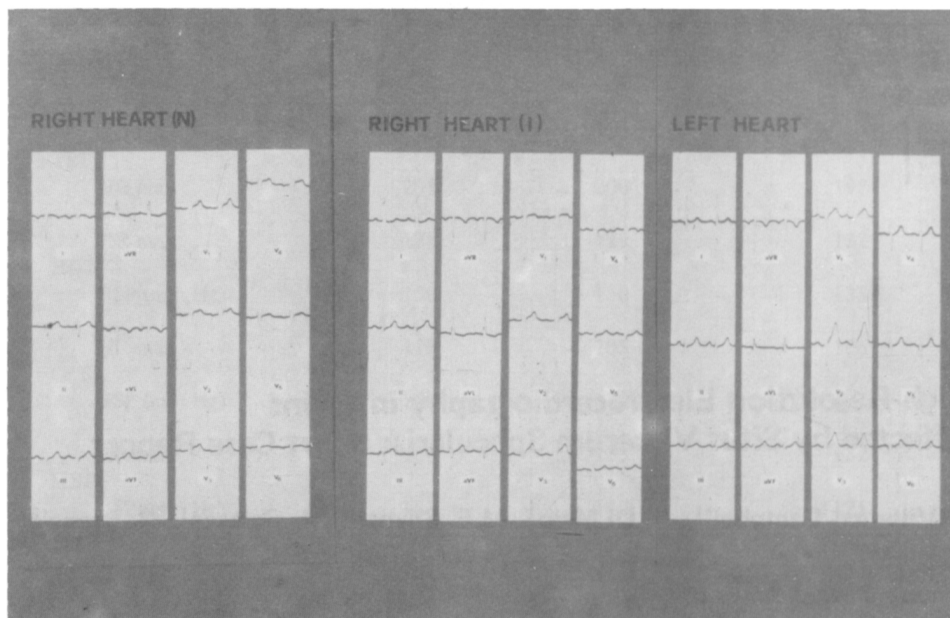


Fig. 1 - Twins standard ECG. Right heart with normal (N) and inverted (I) electrode position.

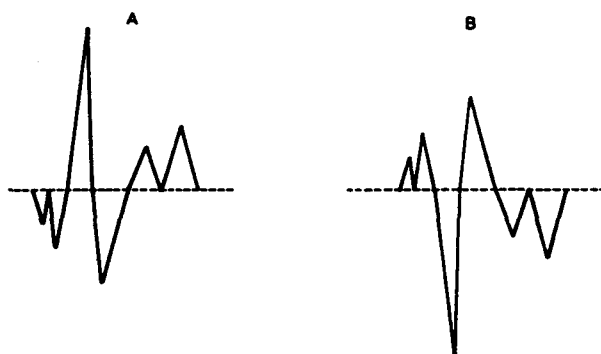


Fig. 2 - The opposite-down of the ECG vectors of the two twins (A, dextrocardiac; B, normal twin). The electrical fields are spatially opposite.

3. Gedda L, Sciacca A, Brenci G, Villatico Campbell S, Bonanni G, Gueli N, Talone C (1984): Situs viscerum specularis in monozygotic twins. *Acta Genet Med Gemello* 33:81-85.
4. Perez GL, Keith L (1978): Electrocardiograms of twins. In Nance WE (ed): *Twin Research. Part C: Clinical Studies*. New York: AR Liss, pp 33-47.

Correspondence: Dr. S. Villatico Campbell, Via Stefano Iacini 16, 00191 Roma, Italy.