

performed the wavelet analysis on EEG recorded during the face expectation period: 1000–2000 ms from the cue onset.

Results We found the emotional modulation (EM) in EEG rhythms during the expectation of angry vs. neutral faces in both groups. Statistical comparison of the spectral power using 2×2 factorial design showed that the EM differences ($P < 0.05$) between the groups were in the left parietal locations in 9 Hz and in 16–18 Hz, in the right parietal locations in 27–28 Hz, and in the right frontal area in 30–31 Hz.

Conclusions The unconscious expectation of angry vs. neutral faces resulted in EM differences between the MDD and healthy controls in the right frontal and bilateral parietal areas mostly in beta and gamma ranges.

Disclosure of interest The authors have not supplied their declaration of competing interest.

<http://dx.doi.org/10.1016/j.eurpsy.2017.02.321>

EW0708

Brain pathway differences between Parkinson's disease patients with and without depressive symptoms

S. Mohammadi Jooyandeh^{1,*}, T.C. Baghai¹, M.H. Aarabi², M. Dolatshahi³, B. Langguth¹

¹ University hospital Regensburg, psychiatry and psychotherapy, Regensburg, Germany

² Basir eye health research center, neuroscience, Tehran, Iran

³ Tehran university of medical sciences, student's scientific research center, Tehran, Iran

* Corresponding author.

Introduction Depression occurs frequently in patients suffering from Parkinson's disease (PD). However, the neural basis of depression in PD remains unclear. Diffusion magnetic resonance imaging (DMRI) connectometry is based on the spin distribution function (SDF), which quantifies the density of diffusing water.

Aim The aim of this study was to assess the microstructural changes in the brain connectivity of PD patients with and without depressive symptoms.

Methods DMRI was used to assess microstructural abnormalities in the brains of 16 PD patients with depressive symptoms compared to 11 PD patients without depressive symptoms. Data used in the preparation of this paper were obtained from the Parkinson's progression markers initiative (PPMI) database (<http://www.ppmi-info.org/data/>). This dataset was acquired on a 3-Tesla scanner (Siemens), producing 64 DWI at $b = 1000 \text{ s/mm}^2$ and one b_0 image. Diffusion MRI data were corrected for subject motion, eddy current distortions, and susceptibility artefacts due to magnetic field inhomogeneity. DMRI connectometry was conducted in a total of 27 patients using percentage measurement.

Results PD Patients with depressive symptoms showed decreased anisotropy ($FDR < 0.05$) in the fornix bilaterally, left inferior longitudinal fasciculus (ILF) and corticospinal tract bilaterally compared to PD patients without depressive symptoms.

Conclusions Lesser WM integrity of the left ILF fibers, which connect visual face recognition areas to the amygdala and hippocampus, seems to be associated with depressive symptoms in PD patients. Our study supports the hypothesis that neurodegenerative processes in projections from the somatosensory, cingulate, and insular cortices may be related to depression in PD.

Disclosure of interest The authors have not supplied their declaration of competing interest.

<http://dx.doi.org/10.1016/j.eurpsy.2017.02.322>

EW0709

Meta-analysis of aberrant brain activity in psychopathy

T. Poeppel^{1,*}, M. Donges¹, R. Rupprecht¹, P. Fox², A. Laird³, D. Bzdok⁴, B. Langguth¹, S. Eickhoff⁵

¹ University of Regensburg, department of psychiatry and psychotherapy, Regensburg, Germany

² University of Texas health science center, research imaging institute, San Antonio, USA

³ Florida international university, department of physics, Miami, USA

⁴ RWTH Aachen university, department of psychiatry and psychotherapy, Aachen, Germany

⁵ Heinrich Heine university, department of clinical neuroscience and medical psychology, Duesseldorf, Germany

* Corresponding author.

Introduction Psychopathy is characterized by superficial charm, untruthfulness, lack of remorse, antisocial behavior, egocentricity as well as poverty in major affective reactions. This clinical profile has been empirically conceptualized and validated. Recent brain imaging studies suggest abnormal brain activity underlying psychopathic behavior. However, no reliable pattern of altered neural activity has been disclosed so far.

Objective To identify consistent changes of brain activity in psychopaths and to investigate whether these could explain known psychopathology.

Methods First, we used activation likelihood estimation to meta-analyze brain activation changes in psychopaths across 28 functional magnetic resonance imaging studies reporting 753 foci from 155 analyses ($P < 0.05$, corrected). Second, we functionally characterized the ensuing regions employing meta-data of a large-scale neuroimaging database ($P < 0.05$, corrected).

Results Psychopathy was consistently associated with decreased brain activity in the right amygdala, the dorsomedial prefrontal cortex (DMPFC), and bilaterally in the lateral prefrontal cortex (LPFC). Consistently increased activity was observed bilaterally in the fronto-insular cortex (FIC) (Fig. 1). Moreover, we found that the physiological functional role of the candidate regions related to social cognition (DMFPC), cognitive speech and semantic processing (left FIC/LPFC), emotional and cognitive reward processing (right amygdala/FIC) as well as somesthesia and executive functions (RLPFC).

Conclusion Psychopathy is characterized by abnormal brain activity of bilateral prefrontal cortices and the right amygdala, which mediate psychological functions known to be impaired in psychopaths. Hence, aberrant neural activity can account for pertinent psychopathology in psychopathy.

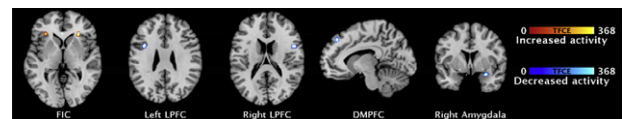


Fig. 1

Disclosure of interest The authors have not supplied their declaration of competing interest.

<http://dx.doi.org/10.1016/j.eurpsy.2017.02.323>

EW0710

Cannabis use decreases prefrontal glutamate levels in early psychosis

S. Rigucci^{1,2,*}, L. Xin³, P. Klauser¹, P.S. Baumann¹, L. Alameda¹, M. Cleusix⁴, J. Raoul⁴, C. Ferrari¹, M. Pompili², R. Gruetter⁵, K. Do Cuenod⁴, P. Conus¹

¹ Centre hospitalier universitaire vaudois, CHUV, department of general psychiatry, Lausanne, Switzerland