

## **Outcomes and Symptom-specific Quality of Life after Microscopic Parotidectomy: A Prospective Study**

**Authors:** Abhishek Bhardwaj<sup>a</sup>, Suji PS<sup>b</sup>, Rachit Sood<sup>c</sup>, Manu Malhotra<sup>d</sup>, Madhu Priya<sup>e</sup>, Saurabh Varshney<sup>f</sup>, Akash Varshney<sup>g</sup>, Subrat Nag<sup>h</sup>

### **Authors Affiliation:**

- a. M.S, DNB (ENT), Associate Professor, Department of Otorhinolaryngology & Head-Neck Surgery, All India Institute of Medical Sciences, Rishikesh, India. Pin 249203.  
Email id: [abhi04stanley@gmail.com](mailto:abhi04stanley@gmail.com)
- b. M.S, DNB (ENT), Assistant Professor, Department of Otorhinolaryngology, All India Institute of Medical Sciences, Deoghar, India. Pin 814152. Email id: [ps.sujips.suji@gmail.com](mailto:ps.sujips.suji@gmail.com)
- c. M.S, DNB (ENT), Academic Senior Resident, Department of Otorhinolaryngology & Head-Neck Surgery, All India Institute of Medical Sciences, Delhi, India. Pin 249203.  
Email id: [soodrachit@gmail.com](mailto:soodrachit@gmail.com)
- d. M.S. (ENT), Professor and Head, Department of Otorhinolaryngology & Head-Neck Surgery, All India Institute of Medical Sciences, Rishikesh, India. Pin 249203 Email: [manumalhotrallrm@gmail.com](mailto:manumalhotrallrm@gmail.com)
- e. M.S, DNB (ENT), Additional Professor, Department of Otorhinolaryngology & Head-Neck Surgery, All India Institute of Medical Sciences, Rishikesh, India. Pin 249203.  
Email id: [drpriyamadhu@gmail.com](mailto:drpriyamadhu@gmail.com)
- f. M.S, (ENT), Executive Director & CEO, All India Institute of Medical Sciences, Deoghar, Jharkhand, India, Pin 814142 Email ID: [drsaurabh68@gmail.com](mailto:drsaurabh68@gmail.com)
- g. MBBS, Junior Resident, Department of Otorhinolaryngology & Head Neck Surgery, All India Institute of Medical Sciences, Rishikesh, India. Pin 249203. Email id:

[akashvarshney321@gmail.com](mailto:akashvarshney321@gmail.com)

h. MBBS, Junior Resident, Department of Otorhinolaryngology & Head Neck Surgery,

All India Institute of Medical Sciences, Rishikesh, India. Pin 249203. Email id:

[subratanag25@gmail.com](mailto:subratanag25@gmail.com)

**Corresponding Author:**

**Dr. Suji P S**

Assistant Professor

Department of Otolaryngology & Head Neck Surgery

AIIMS, Deoghar, Jharkhand, India.

Pin code: 814152

Email: [ps.sujips.suji@gmail.com](mailto:ps.sujips.suji@gmail.com)

ORCID ID number: 0000-0003-4534-3691

Ph. No: +919495778899

**Objective:** Assess the postoperative complications of microscopic parotidectomy and its impact on quality of life (QoL).

**Methods:** Thirty patients were included in this prospective study. Three to six months post-surgery, patients underwent assessments for Frey's syndrome by minor test, aesthesiometer test, facial nerve function, and QoL questionnaire.

**Results:** FS symptom positive in none, Minor test positive in 50%. The preservation rate of the GAN posterior branch was 90%, but it had no significant impact on the aesthesiometer test. Transient and permanent facial paresis were observed in 13.3 % and 3.3%, and the salivary fistula in 3.3%. In QoL, the rating of general health as good/better was seen in 73.3%, nil/minimal pain in 93.3%, bothersome change of facial contour in none, and dry mouth in 23.3%.

**Conclusion:** Microscopic parotidectomy achieves good surgical outcomes regarding Frey's syndrome symptoms, GAN preservation, facial paresis, salivary fistula, and QoL.

**Keywords:** Parotid neoplasms, Facial nerve, Quality of life, Postoperative Complications

## Introduction

The Parotid gland tumours account for approximately 3% of all head and neck tumours, with the majority, approximately 80%, being benign<sup>1</sup>. These benign tumours include pleomorphic adenoma, cyst adenolymphoma, and basal cell adenoma. However, malignant tumours such as mucoepidermoid carcinoma, adenocystic carcinoma, and acinic cell carcinoma also occur, albeit less frequently. Whether the tumour is benign or malignant, parotid surgery is often necessary for the treatment. The primary objective of parotid surgery is the partial or complete removal of the gland while safeguarding facial nerve integrity and minimizing the risk of tumour recurrence. Surgical approaches for treating parotid tumours include extracapsular dissection, superficial parotidectomy, conservative parotidectomy, and total parotidectomy with facial nerve preservation. The literature reveals an overall complication rate of 8.5% to 21.6% associated with the types of parotidectomies; the complications include facial paresis, postoperative numbness, Frey's syndrome, pain, dryness, salivary fistula, and scar-related issues<sup>2,3</sup>.

In current clinical practice, measuring health-related quality of life (QoL) is increasingly recognised as decisive<sup>4</sup>. The subjective experience of postoperative symptoms and overall well-being is a significant aspect of patient care, influencing treatment decisions and patient satisfaction. The main objectives of this study are to assess the occurrence of postoperative complications after parotidectomy, focusing specifically on Frey's syndrome (FS), Facial nerve weakness or paralysis, First bite Syndrome, and deficit in the greater auricular nerve (GAN). Additionally, this study aims to investigate how these complications impact the QoL of patients undergoing parotidectomy.

By assessing various dimensions of QoL, including physical, emotional, and social well-being, this study seeks to elucidate the holistic impact of microscopic parotidectomy on

patients' lives. Furthermore, understanding the trajectory of symptom resolution and functional recovery post-surgery can inform healthcare providers in optimizing patient care pathways and postoperative management strategies.

## Materials and Methods

A prospective study was conducted between 2019 and 2023. Consenting patients who underwent microscopic parotidectomy were included in this study. The exclusion criteria were patients who underwent revision surgery, had prior head and neck radiation, or had debilitating systemic pathologies or peripheral neuropathy. The surgical steps followed in our study were similar to those described in the article by Bhardwaj A. et al.<sup>5</sup> (fig. 1).

Basic demographic information such as age, gender, details of the surgical procedure, type of parotid surgery, final histopathology report, and any postoperative complications were recorded and subjected to detailed analysis. The patients were subjected to a Minor test to assess for FS, an aesthesiometer test, a facial nerve examination, and a QoL questionnaire in the post-operative period between 3 to 6 months.

During the minor test, an iodine solution was applied to the operated area, followed by starch, after the iodine solution had dried. Afterward, salivary production was enhanced with the help of a lemon-flavoured candy. If a blue/purple colour change appeared in the area where the iodine solution and starch were applied, the test was considered positive for FS (fig. 2 A & B).

The aesthesiometer test was conducted in the eight cutaneous areas mentioned by Ryan et al.<sup>6</sup>, corresponding to the GAN distribution. For this test, a Semmes–Weinstein aesthesiometer was utilized. This device comprises a flexible plastic monofilament attached to a rigid plastic wand. Applying pressure to the skin with the monofilament until it begins to bend exerts a standardized, constant, and reproducible force onto the skin. The subjects were instructed to close their eyes, and the aesthesiometer test was initially conducted on the untreated side to familiarize them with the procedure. Subsequently, the eight areas on the operated side were tested randomly. If the subject perceived a normal tactile sensation, they

were instructed to say the word "touch." Conversely, if the subject experienced paraesthesia-like sensations or hypoesthesia, they were asked to say the word "up." For this study, "paraesthesia" was defined as a tingling, pinching, burning, or electric discharge sensation (fig. 2C).

Facial nerve functions were evaluated using the House-Brackmann classification<sup>7</sup>. The symptom-specific quality of life was assessed employing a modified questionnaire based on the University of Washington QoL instrument, following the framework established by Nitzan et al.<sup>8</sup> It consists of 12 Likert-type scaled questions. Two questions are general health-related with 1-5 scales; six are symptom-specific with a severity scale of 100/75/50/25/0; two are symptom-specific questions with a severity scale of 100/66/33/0, and two are binary. High scores on the QoL scales indicate elevated functionality and overall well-being. Statistical analysis was performed using Fisher's exact test, the Chi-squared test. The non-parametric tests (Wilcoxon-Mann-Whitney U Test, Kruskal Wallis Test) and parametric tests (t-test) were used for group comparisons. Statistical significance was determined at a p-value of <0.05.

## Results and analysis

Thirty patients were eligible per the study's defined inclusion and exclusion criteria. There were 16 (53.3%) males and 14 (46.7%) females, with a mean age of  $40.48 \pm 12.87$  years. Out of the thirty patients, twenty-four (80%) underwent superficial parotidectomy, four (13.3%) underwent total conservative parotidectomy, one (3.3%) patient underwent total parotidectomy, and one (3.3%) patient underwent only deep lobe resection.

The GAN was sacrificed in three (10%) patients, while in twenty-seven (90%) patients, only the anterior branch of the GAN was sacrificed during the resection. Postoperative facial nerve paresis was observed in 5 (16.3%) patients: transient in 4 patients and permanent in 1. Transient paresis resolved within two weeks for all four patients. In addition to the facial nerve palsy, other notable complications were observed. Specifically, one patient (3.3%) experienced tumour recurrence, diagnosed as adenoid cystic carcinoma. This individual developed lung metastasis within three months of surgery, prompting the initiation of chemoradiotherapy as part of the treatment regimen. Furthermore, one patient (3.3%) presented with a salivary fistula. The management of this complication involved conservative measures, including the application of pressure dressings and the administration of the anticholinergic drug Glycopyrrolate (Tablet Glycopyrrolate 2mg thrice daily for five days, followed by twice daily for five days). Remarkably, the salivary drainage drastically decreased from 50ml to 10ml within two days and resolved entirely within five days. These findings highlight the diverse spectrum of potential complications following microscopic parotidectomy and underscore the importance of vigilant postoperative monitoring and prompt intervention in managing adverse outcomes.

The preoperative cytology report identified three malignant lesions, including two cases of acinic cell carcinoma and one of adenocystic carcinoma, with an additional three cases classified as suspicious for malignancy. The remainder of the cases were diagnosed as benign.



However, the final histopathological examination (HPE) report revealed that out of the thirty subjects, 25 (83.3%) were diagnosed with benign conditions, including pleomorphic adenoma (18), myoepithelioma (2), warthin's tumor (3), chronic inflammation (1), and chronic sialadenitis with degenerated collapsed cyst (1). Interestingly, the remaining five subjects (16.7%) were diagnosed with malignant tumors, including adenocystic carcinoma (1), acinic cell carcinoma (2), adenocarcinoma (1), and mammary analogue of secretory carcinoma (1). Notably, one preoperative malignant lesion and two suspicious malignancies were benign upon histopathological examination, while two preoperatively benign cytology specimens were determined to be malignant postoperatively. The postoperative HPE impression of benign predominantly had a pre-operative cytology impression of benign. The HPE impression of malignant had significant higher proportions of suspicious for malignancy and malignant pre-operative cytology impressions. Our analysis revealed a statistically significant association between pre-operative cytology and postoperative HPE impression (Table I). This finding underscores the predictive value of pre-operative cytological assessments in determining the final histopathological outcomes in patients undergoing microscopic parotidectomy.

Our study highlights the utility and limitations of pre-operative cytology in diagnosing parotid gland tumors. While fine-needle aspiration cytology (FNAC) demonstrates high accuracy in identifying benign tumors, its predictive value for malignant tumors shows room for improvement. The moderate association between pre-operative cytology impressions and final histopathological outcomes underscores the need for a multi-faceted diagnostic approach.

Our analysis revealed a statistically significant association ( $p=0.048$ ) between postoperative complications and diagnosis of malignant lesions on histopathological examination (HPE). Specifically, a salivary fistula was observed in a patient diagnosed with acinic cell carcinoma, while tumour recurrence occurred in a patient with adenoid cystic

carcinoma. These findings suggest a potential correlation between the histopathological characteristics of the tumour and the likelihood of postoperative complications.

While none of the patients reported symptoms indicative of FS, an assessment conducted using the Minor Test revealed that 15 individuals (50%) tested positive. No statistically significant association was observed between FS and age, gender, sacrifice of the GAN, or other postoperative complications.

In this study, 10 (33.3%) patients reported symptoms consistent with anaesthesia over the operated site. Five (16.7%) experienced transient anaesthesia, which resolved spontaneously within three weeks, while the remaining five patients had persistent symptoms. However, upon conducting the esthesiometer test, only one patient with transient anaesthesia and one out of the five patients with persistent symptoms were found to have anaesthesia over the operated sites.

The aesthesiometer test results revealed that out of 30 patients, one reported anaesthesia over Zones 1, 2, and 4 regions, two reported anaesthesia over Zones 3, 5, 6, and 8 regions, and three reported anaesthesia over Zone 7. Notably, none of the patients experienced paraesthesia or hypoesthesia. The GAN was sacrificed in three patients. However, only one of these patients experienced anaesthesia over Zones 3, 5, and 7, while the other two did not report any paraesthesia or anaesthesia. There was no statistically significant association between the aesthesiometer test and GAN sacrifice (Table II).

All participants completed the QoL questionnaire. For the first two general health-related questions, the majority answered with a score of 3 (33.3% and 63.3%, respectively), indicating that most participants reported stable or improved health post-surgery, a small subset (4 participants) did experience a decline in their perceived health status. Out of the 4 participants with worsening health, one had post-operative permanent facial palsy, two

experienced postoperative pain at the operative sites, and one developed knee osteoarthritis two months after surgery. The osteoarthritis was managed conservatively by an orthopedician with medications and physical therapy over 6 months, which helped improve mobility but required ongoing management. The patient with permanent facial palsy denied facial reanimation surgery. For the two participants with operative site pain, analgesics, and anti-inflammatory medications were provided, and both reported gradual pain reduction within 3 to 4 weeks, with continued follow-up for 6 months to ensure complete recovery.

Regarding symptom-specific QoL-related questions (questions 3 to 10), the majority scored 75 and 100, suggesting a good quality of life with minimal postoperative complications and sequelae. Questions related to dryness of the mouth revealed that 7 (23.3%) patients reported complaints of dryness, with five individuals developing dryness after parotidectomy. There was a statistically significant association between the response score to questions 1 and 2, with a p-value of 0.04. A good score in response to question 3 was significantly associated with a good score in response to questions 4 and 5, with p-values of 0.013 and 0.004, respectively. Responses to question 6 showed a statistically significant association between the type of parotid surgery ( $p=0.049$ ) and postoperative facial palsy ( $p=0.019$ ) (Table III).

## Discussion

Parotidectomy may result in a range of complications, from minor complications such as an unhealthy scar to serious complications, including facial nerve palsy, FS, and salivary fistula. These complications may have a variable impact on the quality of life of patients undergoing parotidectomy.

The incidence of FS varies widely in the literature, ranging from 5% to 100%. This variation can be attributed to multiple factors, including differences in surgical techniques, study populations, and assessment techniques used to diagnose FS<sup>9</sup>. Tuncel et al. classified the severity of FS based on the following criteria: 1. Clinical Appearance of sweat in the parotid region (noticed/unnoticed), 2. Positivity on Minor test, 3. Excessive sweating needs medical or surgical intervention, and 4. Presence of foul smell of sweat. According to their classification, the syndrome was considered moderate if fewer than four criteria were met and severe if all four criteria were fulfilled. According to the study by Tuncel et al., the Minor test yielded positive results in 50% of the patients assessed. However, only 10% of the patients reported experiencing symptoms consistent with the findings of the Minor test<sup>10</sup>. In Neuman et al.'s study, out of the 82 Minor tests conducted, 62.2% yielded positive results. Interestingly, all patients who subjectively reported experiencing symptoms consistent with FS also tested positive on the Minor's test. Additionally, in 27% of cases, the Minor's test returned positive results despite patients not reporting subjective symptoms of facial sweating, indicating the presence of "subclinical FS"<sup>11</sup>. In our study, the incidence of FS was identified as 50% based on positivity on the Minor test; however, none of the cases were symptomatic. Compared with findings in the literature, our study yielded similar results, indicating a higher incidence of FS based on positivity on the Minor test than clinical symptomatology.

A Positive Minor test without symptoms highlights the importance of a better evaluation tool for FS. A significant difference in symptomatology and diagnostic positivity for FS mandates the requirement of diagnostic tools that are in coherence with symptoms. In the study by Lafont et al., infrared thermography has been shown to be an excellent diagnostic tool for FS<sup>12</sup>. Quantitative thermographic measurements offer valuable insights into the wide variation observed in the incidence of FS. Consequently, thermography holds promise as a diagnostic modality for evaluating and studying FS<sup>13</sup>.

As per the literature search, only a few studies have evaluated the preservation of GAN and deficits arising from GAN sacrifice during parotidectomy. In studies by Christensen et al., Hui et al., and Suen et al., GAN preservation rates were reported as 70.5%, 69%, and 50%, respectively<sup>14-16</sup>. These variations in preservation rates could be attributed to differences in the aggressiveness of surgeons regarding nerve preservation or the completeness of tumor extirpation. Surgeons' individual techniques, experience levels, and surgical philosophies may influence their decisions regarding GAN preservation during parotidectomy. Additionally, tumor characteristics and extent variations could contribute to differences in nerve preservation rates across studies.

In the study by Ryan et al.<sup>6</sup>, 22 patients underwent parotidectomy with GAN sacrifice, 11 (50%) patients exhibited at least one anaesthetic area, and 19 (86%) exhibited at least one hypo anaesthetic area at one-year post-surgery. In our study, with an anaesthesiometer test, we observed 6 (20%) patients who showed at least one anaesthetic area, and none reported paraesthesia or hypoanesthesia. Notably, the superhelix region (zone 7) was identified as the most affected area among these patients. This shows a significant difference arising from preserving the posterior branch of GAN. However, it's worth noting that five patients reported symptoms related to persistent anaesthesia, specifically over the operated site. Surprisingly, out of these five patients, only one revealed anaesthesia upon anesthesiometer testing. These

findings suggest a discrepancy between subjective patient-reported symptoms and objective clinical assessment using the anaesthesiometer test. While subjective symptoms may prompt patient concern and warrant clinical attention, objective assessment tools such as the esthesiometer test may provide insight into anaesthesia's true extent and severity following surgical intervention.

Patel et al.<sup>17</sup> previously concluded that GAN morbidity has a minimal impact on subjects' QoL, which is consistent with our findings and those of Ryan et al.<sup>6</sup> and Fiacchini et al.<sup>18</sup> In the study conducted by Bulut et al., GAN was preserved in 21% of cases (GAN group, n = 29). In comparison, it was sacrificed in 79% of cases (non-GAN group, n = 108) of parotidectomies. Interestingly, their findings revealed a negative result: GAN preservation did not significantly improve sensation in the long term, nor did it increase health-related QOL postoperatively<sup>19</sup>. This further supports the notion that deficits in the GAN may not significantly affect the overall QoL of patients undergoing parotidectomy. Preserving the posterior branch of the GAN can maintain sensations over the pinna and decrease the short-term disabilities like difficulty in shaving, and wearing earrings, associated with GAN sacrifice. Possibilities of self-inflicted injuries while shaving, though extremely rare can also be prevented. Literature suggests that this preservation may lead to a modest increase in surgical time, typically ranging from 5 to 25 minutes<sup>16</sup>. However, the potential benefits of improved sensory function and reduced risk of complications may outweigh this additional time in the operating room. This highlights the complexity of decision-making in parotid surgery and the need for a balanced approach considering anatomical preservation and functional outcomes.

The questionnaire regarding QoL following parotidectomy, developed by Nitzan et al. using the University of Washington QoL, is a simple and concise tool<sup>7</sup>. In our study, the general QoL showed no change; however, patients reported specific complaints pertaining to the surgery or parotid lesion. In the study by Ciuman et al., postoperative QoL was evaluated in

patients operated for benign parotid lesions using the Parotidectomy Outcome Inventory (POI-8). Their study revealed a minimal impact on the general QoL. However, they found that factors such as FS, operation site numbness, and cosmetic appearance could influence the symptom-specific QoL<sup>20</sup>.

The facial nerve plays a crucial role in the facial aesthetic and function, making it the most critical in parotid gland surgeries. Different studies have reported various frequencies of temporary and permanent dysfunctions of the facial nerve. Mehle et al., and Marshall et al., observed a higher incidence of transient facial palsy (46.1%, and 24.4%) compared to permanent dysfunction (3.9%, and 1.9%)<sup>21,22</sup>. In our study, the incidence (16.3%) of temporary facial dysfunction was lower than in other studies, which can be attributed to using a microscope for surgery. The permanent facial dysfunction occurred in 1 patient as the main trunk and branches of the facial nerve were sacrificed to achieve clearance of the tumour, which was infiltrating the nerve (3.3%). Our study had a significant association between postoperative facial palsy and aesthetic outcome ( $p=0.019$ ), underscoring the impact of facial nerve function on the perceived aesthetic results following parotid surgery. Patients experiencing facial palsy may encounter challenges related to facial symmetry, expression, and overall appearance, which can significantly affect their satisfaction with the surgical outcome. Therefore, addressing and minimizing the risk of postoperative facial palsy is crucial for optimizing aesthetic outcomes and enhancing patient satisfaction in parotid surgery. Also, all cases of temporary facial paresis resolved within two weeks of surgery, highlighting the advantage of the microscope in the anatomical preservation of all nerve branches.

One of the factors influencing postoperative symptom-specific QoL in parotidectomy is the aesthetics of the surgical site. In the study by Ciuman et al., which focused on patients who underwent surgery for benign tumours, aesthetic appearance was rated as "very good" or "good" in 87% of the cases<sup>20</sup>. In our study, 70% of the patients rated their postoperative facial

contour change using a score scale of "No change," with a score of 100, while 30% rated it as "slight change without bothersome" with a score of 75. In the study by Ciuman et al.<sup>20</sup>, the percentage of near-total and total parotidectomy was 5% (1 patient); it was 16.6% (5 patients) in our study, considering both conservative and total parotidectomy procedures.

The aesthetic scale analysis has revealed a statistically significant association with the type of parotid surgery ( $p=0.049$ ) in the study by Aydin et al<sup>23</sup>. They observed that as the extent of the surgery increased, the patients' residual parotid tissues were reduced, resulting in increased aesthetic discomfort. Additionally, incorporating the superficial musculoaponeurotic system flap for parotid reconstruction has shown efficacy in reducing cosmetic and functional complications post-parotidectomy<sup>24</sup>. Notably, in our study, the sternocleidomastoid flap was used to fill the hollow created out of the removal of the parotid gland to achieve a better aesthetic outcome in cases of total parotidectomy. Part of the sternocleidomastoid in its upper third portion was rotated and sutured to the masseter to fill the hollow. These approaches underscore the importance of a comprehensive approach to parotid surgery that considers both functional and aesthetic aspects to enhance patient satisfaction and overall outcomes.

Seven patients (23.3%) reported experiencing dry mouth, with five (71%) attributing it to the surgical procedure. While severe xerostomia can indeed impact QoL, it is worth noting that parotid surgery has not been demonstrated to reduce salivary flow significantly<sup>8</sup>. This study analyzes the challenges and opportunities for improvement in the immediate postoperative period through a comprehensive exploration of outcomes and symptom-specific QoL measures. Given the preliminary nature of our findings, we recommend further studies with larger sample sizes and control groups to more definitively assess the impact of magnification on outcomes such as quality of life and complications like FS. Ultimately, such insights can enhance patient-centered care delivery and contribute to better-informed clinical decision-making in managing parotid gland disorders.



## Summary

### What is already known on the subject

- Parotidectomy is associated with multiple possible complications, including facial nerve paresis, FS, salivary fistula, GAN injury, and alteration of facial aesthetics.
- The use of facial nerve monitors, surgical loupes, and microscopes has been documented to achieve better facial nerve preservation in parotidectomy.
- The role of the microscope in facial nerve preservation has been investigated in several studies so far. Still, the incidence of other complications and quality of life outcomes has not been studied in patients undergoing microscopic parotidectomy.

### What this paper adds to our understanding

- Shows favorable outcomes of microscopic parotidectomy on general and symptom-specific QoL, as well as on complications like Frey's Syndrome.
- Reaffirms the favorable outcomes of microscopic parotidectomy in facial nerve preservation.
- Symptomatic cases of FS can be made negligible using a microscope, but the positivity for the Minor test is as high as 50% in such cases.
- The posterior branch of GAN can be preserved in 90% of cases. However, its preservation does not significantly impact esthesiometer test results.
- Using a microscope in parotidectomy minimizes facial nerve paresis, thus enhancing patient satisfaction and aesthetic outcomes.

**Financial Support**

This research received no specific grant from any funding agency, commercial or not-for-profit sectors.

**Competing interests:** The authors declare none.

**Ethical Standards**

The authors assert that all procedures contributing to this work comply with the ethical standards of our national and institutional guidelines on human experimentation and with the Helsinki Declaration of 1975, as revised in 2008. The authors assert that all procedures contributing to this work comply with our institutional and national ethical standards. The Institutional Ethical Committee has approved the study.

## References

1. Smith SL, Komisar A. Limited parotidectomy: the role of extracapsular dissection in parotid gland neoplasms. *Laryngoscope* 2007 ;117:1163-7
2. Kilavuz AE, Songu M, Pinar E, Ozkul Y, Ozturkcan S, Aladag I. Superficial Parotidectomy Versus Partial Superficial Parotidectomy: A Comparison of Complication Rates, Operative Time, and Hospital Stay. *J Oral Maxillofac Surg* 2018 ;76:2027-32
3. Kim BD, Lim S, Wood J, Samant S, Ver Halen JP, Kim JY. Predictors of adverse events after parotidectomy: a review of 2919 cases. *Ann Otol Rhinol Laryngol* 2015 ;124:35-44
4. Stodulski D, Świątkowska-Stodulska R, Mikaszewski B, Kuczkowski J. Health-related quality of life of parotid carcinoma patients-a comparative study with parotid adenoma patients and assessment of the influence of demographic, treatment, and pathological factors. *Int J Oral Maxillofac Surg* 2019 ;48:163-72
5. Bhardwaj A, Sood R, Malhotra M, Priya M, Tyagi AK, Kumar A, et al. Microscopic Parotidectomy: A Prospective Study. *Indian J Otolaryngol Head Neck Surg* 2022 ;74:2273-80
6. Ryan WR, Fee WE. Long-term great auricular nerve morbidity after sacrifice during parotidectomy. *Laryngoscope* 2009 ;119:1140-6
7. House JW, Brackmann DE. Facial nerve grading system. *Otolaryngol Head Neck Surg* 1985 ;93:146-7
8. Nitzan D, Kronenberg J, Horowitz Z, Wolf M, Bedrin L, Chaushu G, et al. Quality of life following parotidectomy for malignant and benign disease. *Plast Reconstr Surg* 2004 ;114:1060-7
9. Luna-Ortiz K, Sansón-RíoFrío JA, Mosqueda-Taylor A. Frey syndrome. A proposal for evaluating severity. *Oral Oncol* 2004 ;40:501-5

10. Tuncel A, Karaman M, Sheidaei S, Tatlıpınar A, Esen E. A comparison of incidence of Frey's syndrome diagnosed based on clinical signs and Minor's test after parotid surgery. *Kulak Burun Bogaz İhtis Derg* 2012 ;22:200-6
11. Neumann A, Rosenberger D, Vorsprach O, Dazert S. Inzidenz des Frey-Syndroms nach Parotidektomie: Ergebnisse einer Befragung und Nachuntersuchung [The incidence of Frey syndrome following parotidectomy: results of a survey and follow-up]. *HNO* 2011 ;59:173-8
12. Lafont M, Whyte A, Whyte J, Saura E, Tejedor MT. Frey syndrome: factors influencing the time to event. *Int J Oral Maxillofac Surg* 2015 ;44:834-9
13. Choi HG, Kwon SY, Won JY, Yoo SW, Lee MG, Kim SW, et al. Comparisons of Three Indicators for Frey's Syndrome: Subjective Symptoms, Minor's Starch Iodine Test, and Infrared Thermography. *Clin Exp Otorhinolaryngol* 2013 ;6:249-53
14. Christensen NR, Jacobsen SD. Parotidectomy. Preserving the posterior branch of the great auricular nerve. *J Laryngol Otol* 1997 ;111:556-9
15. Hui Y, Wong DS, Wong LY, Ho WK, Wei WI. A prospective controlled double-blind trial of great auricular nerve preservation at parotidectomy. *Am J Surg* 2003 ;185:574-9
16. Suen DT, Chow TL, Lam CY, Wong ES, Lam SH. Sensation recovery improved by great auricular nerve preservation in parotidectomy: a prospective double-blind study. *ANZ J Surg* 2007 ;77:374-6
17. Patel N, Har-El G, Rosenfeld R. Quality of life after great auricular nerve sacrifice during parotidectomy. *Arch Otolaryngol Head Neck Surg* 2001 ;127:884-8
18. Fiacchini G, Cerchiai N, Tricò D, Sellari-Franceschini S, Casani AP, Dallan I, et al. Frey Syndrome, First Bite Syndrome, great auricular nerve morbidity, and quality of life following parotidectomy. *Eur Arch Otorhinolaryngol* 2018 ;275:1893-1902

19. Bulut OC, Hohenberger R, Oladokun D, Odenwald K, Plinkert PK, Federspil PA. Long-term quality of life and sensory impact of great auricular nerve preservation in parotid surgery as measured with the Parotidectomy Outcome Inventory-8. *Clin Otolaryngol* 2019 ;44:743-8
20. Ciuman RR, Oels W, Jaussi R, Dost P. Outcome, general, and symptom-specific quality of life after various types of parotid resection. *Laryngoscope* 2012 ;122:1254-61
21. Mehle ME, Kraus DH, Wood BG, Benninger MS, Eliachar I, Levine HL, et al. Facial nerve morbidity following parotid surgery for benign disease: the Cleveland Clinic Foundation experience. *Laryngoscope* 1993 ;103:386-8
22. Marshall AH, Quraishi SM, Bradley PJ. Patients' perspectives on the short- and long-term outcomes following surgery for benign parotid neoplasms. *J Laryngol Otol* 2003 ;117:624-9
23. Aydin S, Erbay MF, Kizilay A. The effects of residual parotid volume on symptom-specific quality of life and complications in patients undergoing parotid surgery. *Eur Arch Otorhinolaryngol* 2021 ;278:5003-11
24. Manola M, Moschillo L, Simeon V, De Luca E, Mastella A. The Effectiveness of Sternocleidomastoid Flap Versus Superficial Musculoaponeurotic System Flap for the Prevention of Frey Syndrome and Facial Depressed Deformity in Parotid Surgery for Pleomorphic Adenoma. *Ann Plast Surg* 2018 ;80:125-129

Table I. Comparison of preoperative cytology and postoperative HPE impression

Final HPE impression	Pre-operative cytology impression				Fisher's Exact test	
	Benign	Suspicious	Malignant	Total	$\chi^2$	p-value
Benign	22 (91.7%)	2 (66.7%)	1 (33.3%)	25 (83.3%)	7.200	0.041
Malignant	2 (8.3%)	1 (33.3%)	2 (66.7%)	5 (16.7%)		
Total	24 (100.0%)	3 (100.0%)	3 (100.0%)	30 (100.0%)		

Table II. Esthesiometer test result

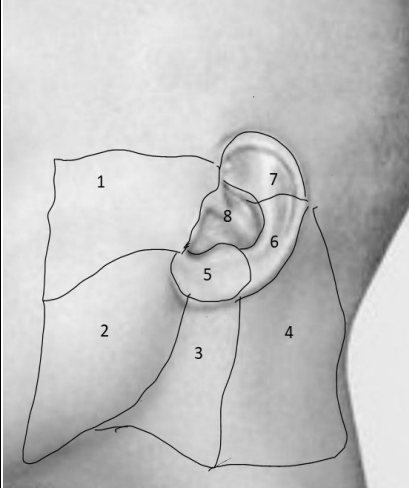
Pictorial representation of zones	Zone	Normal	Anaesthesia
	1. Preauricular	29 (96.7%)	1 (3.3%)
	2. Mandible body	29 (96.7%)	1 (3.3%)
	3. Infraauricular	28 (93.3%)	2 (6.7%)
	4. Postauricular	29 (96.7%)	1 (3.3%)
	5. Lobule	28 (93.3%)	2 (6.7%)
	6. Inferior helix	28 (93.3%)	2 (6.7%)
	7. Superior helix	27 (90.0%)	3 (10.0%)
	8. Concha	28 (93.3%)	2 (6.7%)
None of the patient reported hypoesthesia or paraesthesia			

Table III. Outcomes of patient response to QoL Questionnaire (Questionnaire by Nitzan et al<sup>8</sup>)

Sl.no.	Question	Score	Result	95% CI
1.	General health	1-Poor	1 (3.3%)	0.2% - 19.1%
		2-Not Bad	7 (23.3%)	10.6% - 42.7%
		3-Good	10 (33.3%)	17.9% - 52.9%
		4-Very Good	7 (23.3%)	10.6% - 42.7%
		5-Excellent	5 (16.7%)	6.3% - 35.5%
2	Compared to a year before diagnosis, your health is now	1-Much worse	0	
		2-Worse	4 (13.3%)	0.2% - 19.1%
		3-Same	19(63.3%)	10.6% - 42.7%
		4-Better	6 (20%)	17.9% - 52.9%
		5-Much Better	1 (3.3%)	10.6% - 42.7%
3	Pain	100: No Pain	18 (60%)	40.8% - 76.8%
		75: Some pain, no treatment	10 (33.3%)	17.9% - 52.9%
		50: Some pain treatment needed	2 (6.7%)	1.2% - 23.5%
		25: Much pain, treated with narcotics	0	-
		0: Severe, uncontrollable pain	0	-
4	Appearance	100- No Change	14 (46.7%)	28.8% - 65.4%
		75- Some change	14 (46.7%)	28.8% - 65.4%
		50- Bothering change	2 (6.7%)	1.2% - 23.5%
		25-Severe change	0	-
		0-cannot be with people	0	-
5	Scar	100- Not visible	10 (33.3%)	17.9% - 52.9%



		75- Visible, not bothersome	18 (60%)	40.8% - 76.8%
		50- visible and bothersome	2 (6.7%)	1.2% - 23.5%
		25- visible and very bothersome	0	-
		0-Intolerable	0	-
6	Facial contour change	100- not visible	21 (70%)	50.4% - 84.6%
		75- Visible, not bothersome	9 (30%)	15.4% - 49.6%
		50- visible and bothersome	0	-
		25- visible and very bothersome	0	-
		0-Intolerable	0	-
7	Sensation in the operated site	100- Not affected	20 (66.7%)	47.1% - 82.1%
		75- Affected but now normal	5 (16.7%)	6.3% - 35.5%
		50- Sensation deficit, not bothersome	5 (16.7%)	6.3% - 35.5%
		25- Sensation deficit and bothersome	0	-
		0-Intolerable	0	-
8	Local effects	100- None	30 (100%)	85.9% - 100.0%
		75- Erythema/sweating during eating	0	-
		50-Erythema and sweating but not bothersome	0	-
		25-Bothersome	0	-
		0-Intolerable	0	-
9	Salivary fistula	100- No	27 (90%)	72.3% - 97.4%

		66-notbothersome Resolved	2 (6.7%)	1.2% - 23.5%
		33- Bothersome secretion resolved	1 (3.3%)	0.2% - 19.1%
		0-Secretion persist	0	-
10	Facial Naerve	100- No damage to facial movement	22 (73.3%)	53.8% - 87.0%
		66- facial Movement impaired but resolved	5 (16.7 %)	6.3% - 35.5%
		33-Partial facial movements impaired	3 (10%)	2.6% - 27.7%
		0-complete facial movement impaired	0	-
11	Is Mouth Dry	Yes	7 (23.3 %)	10.6% - 42.7%
		No	23 (76.7%)	57.3% - 89.4%
12	Do you associate dry mouth with your surgery?	Yes	5 (22.7%)	8.7% - 45.8%
		No	17 (77.3%)	54.2% - 91.3%

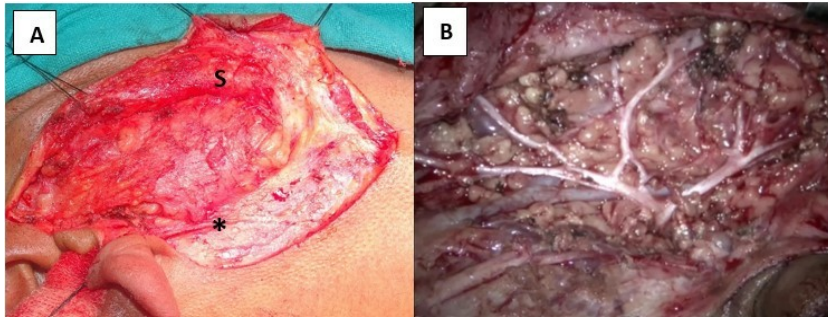


Figure 1

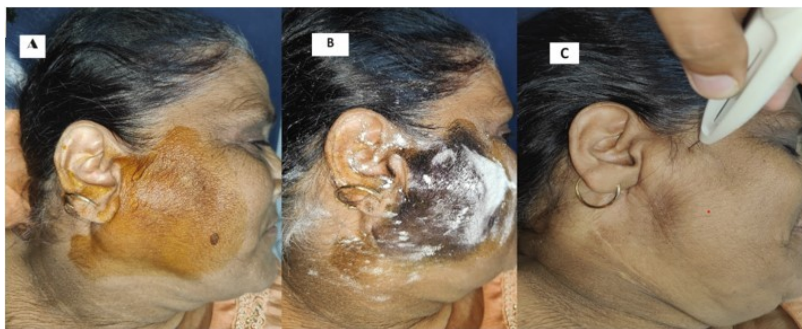

Figure 2