


Wide complex rhythm in a well neonate: Where are the P waves?

Gabrielle Jee¹ , Amos Wong¹, Victor Ofoe¹ and Orhan Uzun^{1,2}¹Department of Paediatric Cardiology, University Hospital of Wales, Cardiff, UK and ²Cardiff University School of Medicine, Cardiff, UK

Brief Report

Cite this article: Jee G, Wong A, Ofoe V, and Uzun O (2023) Wide complex rhythm in a well neonate: Where are the P waves? *Cardiology in the Young* **33**: 2124–2127. doi: [10.1017/S1047951123000963](https://doi.org/10.1017/S1047951123000963)

Received: 2 February 2022

Revised: 6 March 2023

Accepted: 6 April 2023

First published online: 4 May 2023

Keywords:

Neonate; arrhythmia; accelerated idioventricular rhythm

Corresponding author: Prof. O. Uzun, Department of Paediatric Cardiology, University Hospital of Wales, Cardiff, CF14 4XW, UK. Tel: +442920744749. E-mail: Uzun@cardiff.ac.uk

Abstract

A neonate was seen for an evolving broad QRS complex rhythm initially captured at birth as intermittent escape beats on electrocardiogram. Continuous monitoring recorded features mimicking pre-excitation, but closer analysis revealed a regular broad QRS complex rhythm with isorhythmic atrioventricular dissociation, favouring a ventricular source. Treatment with flecainide and propranolol achieved successful control of the incessant arrhythmia with improvement in cardiac function on echocardiogram.

In 1925, an intriguing electrocardiogram trace was published in a book by Welsh cardiologist Sir Thomas Lewis.¹ This rhythm was then known as accelerated idioventricular rhythm, a rare rhythm with much to learn about its epidemiology and progression.² This case illustrates the diagnostic and management challenges of accelerated idioventricular rhythm in a well neonate.

Case presentation

An 11-day-old female neonate was referred to the paediatric cardiology service for advice because of a regular broad (QRS) complex rhythm as shown in Figure 1a. This was captured on a 12-lead electrocardiogram during neonatal follow-up for an irregular heart rhythm at birth. Antenatal anomaly scan was normal with no mention of arrhythmia in the fetus, and the family history was negative for inherited arrhythmia syndromes and congenital cardiovascular abnormalities. She was delivered at 40⁺² weeks' gestation via an emergency caesarean section due to failure to progress of the labour, in the presence of a fetal tachycardia at a rate of 170 beats per minute. The heart rate at birth was 160 beats per minute. A 12-lead electrocardiogram showed intermittent broad QRS complexes with preceding sinus beats (Fig 1b). Apart from transiently elevated serum sodium of 147 mmol/L (which normalised later spontaneously), other biochemistry tests and clinical examination were all normal. These intermittent wide QRS complexes were initially interpreted as ventricular ectopic beats. She was discharged home with a follow-up planned in 1 week's time.

On a subsequent assessment by the cardiology team, she appeared slightly jaundiced but the serum bilirubin level was below phototherapy treatment. An isolated serum magnesium level of 0.71 mmol/L was noted. An echocardiogram showed normal heart structures and good myocardial function. A diagnosis of Wolff-Parkinson-White syndrome was suspected initially and owing to frequent and persistent arrhythmia, oral flecainide at 1 mg/kg/dose twice daily and magnesium supplements were commenced. This was in view of a regular broad QRS complex rhythm with possible slurred upstrokes suggestive of pre-excitation and Holter recordings of a 12-minute episode of tachycardia at a rate of 180 beats per minute (Fig 1c). Preceding P waves and short PR intervals were seen in parts of the Holter recording (Fig 1c and d). This broad QRS complex rhythm terminated suddenly as evidenced by changes in PR and QRS morphologies (Fig 1d). This led to the initial diagnosis of intermittent Wolff-Parkinson-White syndrome.

A review of the recordings by a paediatric electrophysiologist revealed the occasional absence of the P waves preceding the broad QRS complexes (Fig 1a) and as in Figure 1b, the baseline heart rate was noted to be in sinus rhythm at 125 beats per minute. This supported a rhythm that was not of the sinoatrial node origin. There was isorhythmic atrioventricular dissociation with a P wave occurring immediately after each QRS complex. The P waves occurring after the QRS complexes raised the suspicion of possible retrograde conduction. However, regular broad QRS complexes favoured a ventricular source and prompted the possibility of ventricular tachycardia. In this case, the ventricular rate of 150 beats per minute was within normal limits for a well neonate which rendered ventricular tachycardia less likely. A complete heart block could also be considered, but atrioventricular dissociation in a complete heart block is not isorhythmic with atrial rate being typically faster than the ventricular rate.

A short history of arrhythmia and inverted T waves across precordial leads (Fig 1a) in keeping with abnormal myocardial depolarisation and repolarisation also favoured a ventricular source. It became clearer that the presumed delta waves initially identified were a fusion of

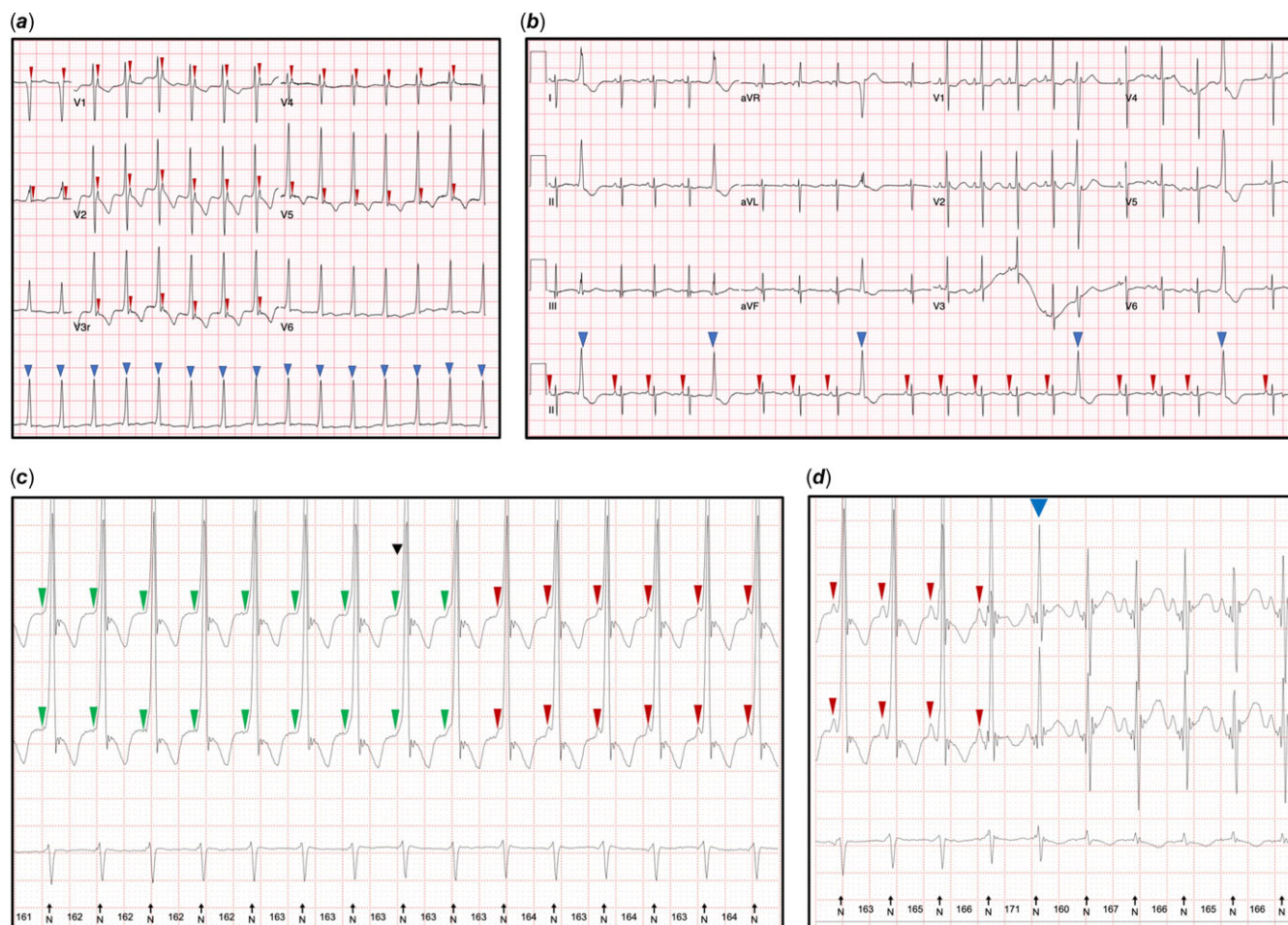

Figure 1. (a) Electrocardiogram on day 11 of life during initial neonatal outpatient showing a regular broad QRS complex rhythm with isorhythmic atrioventricular dissociation and T wave inversion across precordial leads. (b) Electrocardiogram at birth with baseline heart rate of 125 beats per minute and intermittent broad QRS complexes, absence of convincing preceding P waves and inverted T waves with a compensatory pause. (c and d) Holter monitoring on day 11 documenting a regular broad QRS complex rhythm with intermittently preceding P waves and short PR intervals with sudden resolution.

P waves and QRS complexes. These findings of a monomorphic broad QRS complex rhythm at 150 beats per minute (approximately 15% above preceding sinus rhythm) with isorhythmic dissociation in an asymptomatic neonate supported a diagnosis of an accelerated idioventricular rhythm.

Owing to persistent documentation of the accelerated idioventricular rhythm despite being on flecainide treatment for 24 hours (Fig 2a), propranolol 1 mg/kg/dose twice daily was added. This decision was taken due to the incessant arrhythmia and to achieve satisfactory rate control. A scheduled echocardiogram on day 18 of life demonstrated a new finding of mild mitral regurgitation. There was also ongoing intermittent broad QRS complex rhythm and isorhythmic dissociation captured on a Holter monitoring (Fig 2b). Therefore, the flecainide was increased to 2 mg/kg/dose twice daily. Magnesium supplements were stopped as the serum levels had normalised. She remained on propranolol 1 mg/kg/dose twice daily. She was asymptomatic throughout from birth and tolerated the antiarrhythmic treatment well. Successful rate and rhythm control were achieved as demonstrated by sinus rhythm on an electrocardiogram obtained on day 23 of life. An echocardiogram at 26 days of life showed improved myocardial function evidenced by resolving mitral regurgitation. Care of the neonate was

subsequently transferred to another unit following relocation from our institution.

Discussion

This case illustrates the importance of being vigilant in well neonates exhibiting slurred or wide QRS complexes on their electrocardiograms. The presence of broad QRS complexes should prompt urgent assessment and exclusion of not only sinister rhythms such as supraventricular tachycardia with aberrancy and ventricular tachycardia but also accelerated idioventricular rhythm.

Accelerated idioventricular rhythm is relatively rare with or without congenital cardiac disease.³ When encountered in the neonatal period as in this case, it often manifests shortly after birth.² Electrocardiogram findings include tachycardia at 10–15% of the normal sinus rate^{4–7} with a pattern of three or more consecutive monomorphic beats.¹ As the ectopic focus fires at a rate similar to the intrinsic sinoatrial rate, isorhythmic dissociation along with fusion and capture beats are seen.¹ Ventricular tachycardia where fusion and capture beats are also seen is an equally as important to alternative diagnosis exclude.^{8,9} Although typically presenting with

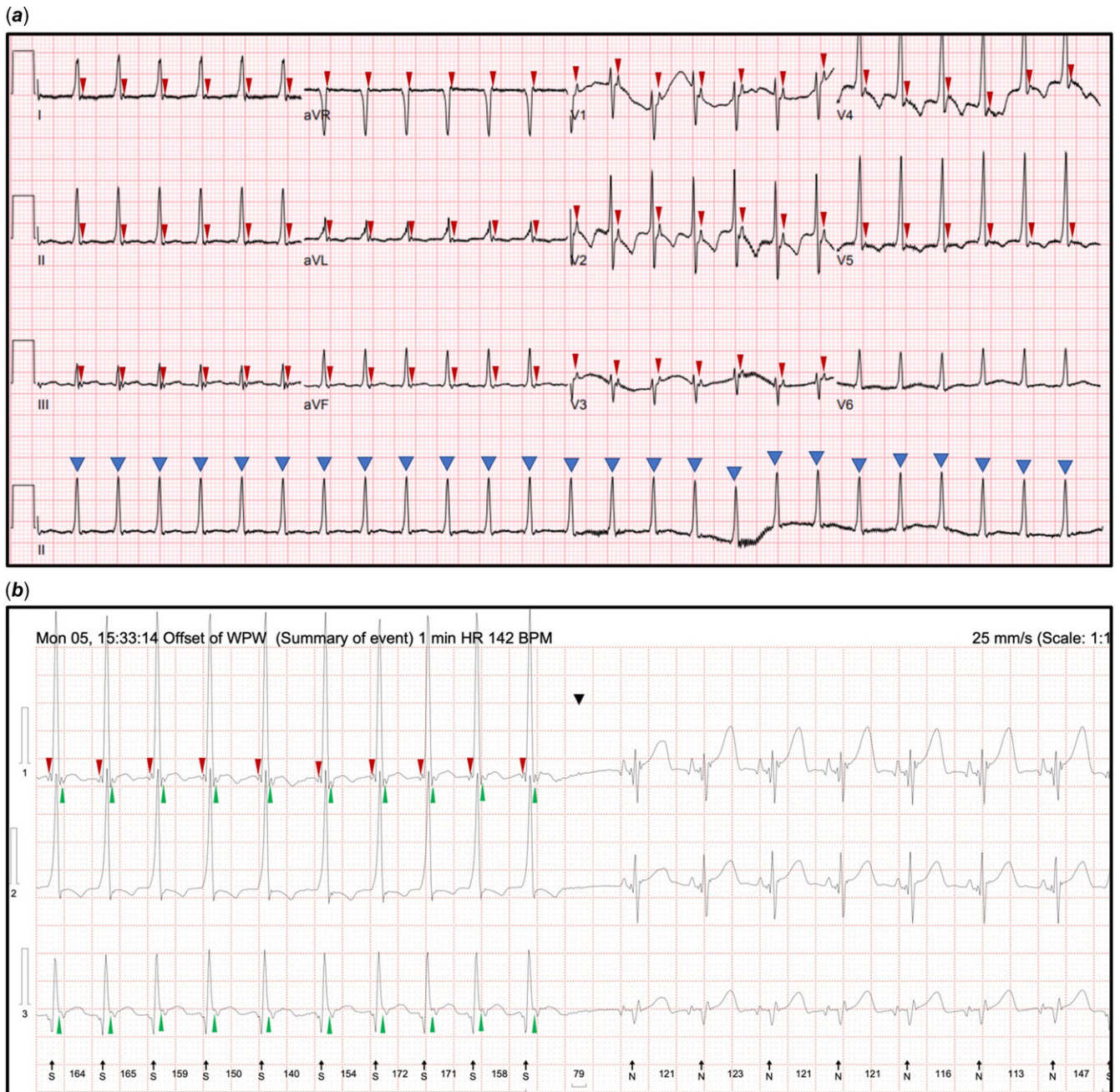


Figure 2. (a and b) Electrocardiogram and Holter monitoring repeated 24 hours after commencing oral flecainide showing a monomorphic broad QRS complex rhythm with P waves occurring after each QR complex and T wave inversion across precordial leads.

faster ventricular rates (age dependent in children),^{8,9} slow ventricular tachycardia should also be considered, and diagnosis should be made in context of the clinical picture. Adenosine test or transoesophageal diagnostic electrophysiology could be utilised in cases where pre-excitation cannot be confidently excluded.

Reynolds and Beach et al have reported the accelerated idioventricular rhythm to be relatively benign and the patients being typically asymptomatic, not requiring treatment but the risk of degenerating into sinister rhythms was unclear.^{3,10} A consensus statement in 2014 suggested that in the absence of symptoms, haemodynamic compromise, or underlying cardiac abnormalities, treatment is not indicated.¹² On the contrary, a

recent case report by Ergul et al described degeneration of accelerated idioventricular rhythm into torsades de pointes during sleep, requiring cardiac resuscitation in a previously asymptomatic 11-year-old boy.¹¹ Isolated case intervention may be warranted in the presence of syncope or sustained arrhythmia due to risk of sudden death, and emerging abnormal echocardiography findings like in our case.^{11,13} Notably, this rhythm may be resistant to pharmacological treatment.²

Freire and Dubrow described five neonatal cases of accelerated idioventricular rhythm, all being asymptomatic with varied presentations and eventual resolution of arrhythmia.² Spontaneous resolution was seen in two cases, and monotherapy with

propranolol or amiodarone was necessary in the other three cases due to frequent arrhythmia. Amiodarone was preferred in one case with a significant ventricular septal defect to avoid negative inotropy.² This previous report and our case both supported a good prognosis of accelerated idioventricular rhythm even though an unpredictable response to treatment can be rarely seen.²

Conclusion

Accelerated idioventricular rhythm in neonates is rare and typically encountered on the first few days of life. Albeit mostly benign and resolves spontaneously, it requires close monitoring and may necessitate even antiarrhythmic treatment based on individual risk assessment. It is pertinent to consider accelerated idioventricular rhythm in the differential diagnosis of broad complex rhythms as the clinical management may differ in other aetiologies.

Acknowledgements. We would like to thank the parents of this child for their enthusiasm and continuous support in sharing of this case to improve our knowledge in presentation and management of this arrhythmia. We also thank all healthcare team members involved in the management of this case for their hardwork and perseverance. Finally, we would like to extend our gratitude to the paediatric cardiology secretaries for consolidating all documentation required for preparation of this case report.

Financial support. This research received no specific grant from any funding agency, commercial, or not-for-profit sectors.

Conflicts of interest. None.

Ethical standards. The authors assert that all procedures contributing to this work comply with the ethical standards of the relevant national guidelines and Helsinki Declaration of 1975, as revised in 2008.

Patient consent. Obtained.

References

1. Riera A, Barros R, de Sousa F, Baranchuk A. Accelerated idioventricular rhythm: history and chronology of the main discoveries. *Indian Pacing Electrophysiol J* 2010; 10: 40–48. Retrieved January 14, 2022, from <https://www.ncbi.nlm.nih.gov/pmc/articles/PMC2803604/pdf/ipej100040-00.pdf>
2. Freire G, Dubrow I. Accelerated idioventricular rhythm in newborns: a worrisome but benign entity with or without congenital heart disease. *Pediatr Cardiol* 2008; 29: 457–462. Retrieved from <http://link.springer.com/10.1007/s00246-007-9024-z>
3. Reynolds JL, Pickoffrid AS. Accelerated ventricular rhythm in children: a review and report of a case with congenital heart disease. *Pediatr Cardiol* 2001; 22: 23–28.
4. Fouron JC. Fetal arrhythmias: the Saint-Justine hospital experience. *Prenat Diagn* 2004; 24: 1068–1080.
5. Martini B, Nava A, Thiene G, et al. Accelerated idioventricular rhythm of infundibular origin in patients with a concealed form of arrhythmogenic right ventricular dysplasia. *Heart* 1988; 59: 564–571.
6. Anatoliotaki M, Papagiannis J, Stefanaki S, Koropouli M, Tsilimigaki A. Accelerated ventricular rhythm in the neonatal period: a review and two new cases in asymptomatic infants with an apparently normal heart. *Acta Paediatr* 2007; 93: 1397–1400.
7. Bisset GS, Janos GG, Gaum WE. Accelerated ventricular rhythm in the newborn infant. *J Pediatr* 1984; 104: 247–249.
8. Kothari DS. Neonatal tachycardias: an update. *Arch Dis Child Fetal Neonatal Ed* 2006; 91: F136–F144.
9. Ban JE. Neonatal arrhythmias: diagnosis, treatment, and clinical outcome. *Korean J Pediatr* 2017; 60: 344.
10. Beach C, Marcuccio E, Beerman L, Arora G. Accelerated idioventricular rhythm in a child with status asthmaticus. *Pediatrics* 2015; 136: e527–e529.
11. Ergul Y, Kafali HC, Uysal F. Accelerated idioventricular rhythm resulting in torsades de pointes and cardiac arrest in a child: successfully cryoablated in left coronary cusp. *Cardiol Young* 2020; 30: 418–421.
12. Crosson JE, Callans DJ, Bradley DJ, et al. PACES/HRS expert consensus statement on the evaluation and management of ventricular arrhythmias in the child with a structurally normal heart. *Heart Rhythm* 2014; 11: e55–e78.
13. Hohnloser SH, Zabel M, Olschewski M, Kasper W, Just H. Arrhythmias during the acute phase of reperfusion therapy for acute myocardial infarction: effects of β -adrenergic blockade. *Am Heart J* 1992; 123: 1530–1535.