

Original Article

Cite this article: Baker DW, Uthayakumaran G, Polwart N, Lee MGY, Wilson W, Ayer J, Tanous D, D'Udekem Y, Celermajer DS, O'Donnell C, and Cordina R (2024). Transcatheter occlusion of venovenous collaterals in the total cavopulmonary Fontan circulation. *Cardiology in the Young*, page 1 of 6. doi: [10.1017/S1047951124025708](https://doi.org/10.1017/S1047951124025708)

Received: 11 March 2024

Revised: 16 June 2024

Accepted: 3 August 2024

Keywords:



Venovenous collateral; Fontan circulation; adult CHD; transcatheter occlusion

Corresponding author:

Rachael Cordina;

Email: rachael.cordina@sydney.edu.au

Transcatheter occlusion of venovenous collaterals in the total cavopulmonary Fontan circulation

David W. Baker^{1,2} , Gajon Uthayakumaran³, Ngaire Polwart⁴, Melissa G.Y. Lee⁵, Will Wilson⁵, Julian Ayer³, David Tanous⁶, Yves D'Udekem⁷ , David S. Celermajer^{1,2}, Clare O'Donnell⁴ and Rachael Cordina^{2,1}

¹Department of Cardiology, Royal Prince Alfred Hospital, Sydney, NSW, Australia; ²Sydney Medical School, University of Sydney, Sydney, NSW, Australia; ³The Heart Centre for Children, The Children's Hospital at Westmead, Westmead, NSW, Australia; ⁴Green Lane Paediatric and Congenital Cardiac Service, Starship Children's Hospital, Auckland, New Zealand; ⁵Department of Cardiology, The Royal Melbourne Hospital, Melbourne, Victoria, Australia; ⁶Department of Cardiology, Westmead Hospital, Sydney, NSW, Australia and ⁷Division of Cardiac Surgery, Children's National Hospital, Washington, DC, USA

Abstract

Background: Venovenous collaterals are abnormal connections between the systemic and pulmonary venous systems. They are commonly seen in the Fontan circulation and may lead to significant hypoxaemia. Transcatheter closure of venovenous collaterals is a potential but controversial treatment as the long-term benefits and outcomes are not well understood. **Methods:** This retrospective cohort study utilised data from the Australian and New Zealand Fontan Registry. Patients who underwent transcatheter venovenous collateral occlusion for hypoxemia from the year 2000 onwards were included. Atriopulmonary and Kawashima-type Fontan circulations were excluded to reflect a more contemporary Fontan cohort. **Results:** Nineteen patients (age 19.3 ± 7.8 years, 53% female) underwent transcatheter venovenous collateral occlusion. Compared to baseline, mean oxygen saturation was improved at latest follow-up (90.5% vs 87.0%; $p = 0.003$). Nine patients achieved a clinically significant response (defined as an increase of at least 5% to 90% or greater), and this was associated with lower baseline Fontan pressures (12.9 v 15.6 mmHg; $p = 0.02$). No heart failure hospitalisations, arrhythmia, transplant referrals, or mortality were observed during the median follow-up period of 4 years. Two patients experienced thromboembolic events and five patients underwent re-intervention. **Conclusion:** Transcatheter occlusion of venovenous collaterals in Fontan patients with chronic hypoxaemia resulted in a modest increase in oxygenation over a median follow-up of 4 years and longer-term prognosis did not appear to be adversely affected. Lower Fontan pressures at baseline were associated with a greater improvement in oxygenation.

Highlights

- Venovenous collaterals are a common cause of hypoxaemia in Fontan patients, associated with morbidity and mortality. Limited data suggest transcatheter venovenous collateral occlusion improves oxygenation but is associated with reduced survival in a higher-risk Fontan population, particularly with elevated Fontan pressures.
- In this study of a more contemporary Fontan cohort, transcatheter venovenous collateral occlusion appeared safe and effective, without evidence of significant harm over a median follow-up period of 4 years. The largest benefit was observed in the setting of lower baseline Fontan pressures.
- Transcatheter venovenous collateral occlusion may be beneficial in the management of chronic hypoxaemia, without adversely effecting longer-term outcomes, in carefully selected Fontan patients.

Introduction

Venovenous collaterals are a common complication of the Fontan circulation, reported in up to 62% of patients.¹ These abnormal connections between the systemic and pulmonary venous systems are thought to act as decompressing vessels in the situation where the systemic venous pressure must always exceed the pulmonary venous pressure for the Fontan circulation to “work”.² Right-to-left shunting via these collaterals may assist in sustaining cardiac output via the provision of ventricular preload but results in reduced oxygen saturations and an increased risk of paradoxical embolism. As chronic hypoxaemia is associated with increased mortality and morbidity in the Fontan population,^{3–7} patients may

© The Author(s), 2024. Published by Cambridge University Press. This is an Open Access article, distributed under the terms of the Creative Commons Attribution licence (<http://creativecommons.org/licenses/by/4.0/>), which permits unrestricted re-use, distribution and reproduction, provided the original article is properly cited.

be considered for closure of their venovenous collaterals, typically by transcatheter occlusion. Short-term improvements in oxygenation have been demonstrated; however, concern exists whether these improvements are sustained, and whether any clinical benefits are derived.⁸⁻ Indeed, a single retrospective cohort study suggested occlusion was associated with increased mortality without any long-term improvement in oxygen saturations, though this was in a relatively high-risk Fontan cohort.¹² We aimed to explore clinical outcomes following venovenous collateral closure in a modern population of total cavopulmonary Fontan patients followed by the Australian and New Zealand Fontan Registry.

Materials and methods

This is a retrospective cohort study of data collected from the Australian and New Zealand Fontan Registry. This includes all patients from both countries with a Fontan circulation, updated annually with correspondence from treating cardiologists and linkage with the National Death Index. The registry protocols and ethics approvals have been previously described.¹³

Patients who had undergone transcatheter venovenous collateral occlusion within the registry were identified by direct correspondence with the major interventional centres across Australia and New Zealand. Patients were excluded if they had an atriopulmonary or Kawashima-type Fontan circulation, had undergone surgical venovenous collateral closure, had closure performed for an indication other than cyanosis, or had undergone concurrent Fontan fenestration closure.

Data were extracted from the registry between years 2000 and 2022 inclusive. Oxygen saturations were determined from ambulatory clinic visits. Baseline oxygenation was the most recent saturation prior to initial venovenous collateral occlusion procedure. Subsequent oxygen saturations were included until latest follow-up or until re-intervention (defined as additional venovenous collateral closure or Fontan fenestration closure) occurred. Clinical outcomes were assessed until latest follow-up, including beyond any potential re-intervention. Venovenous collateral size were categorised into large or small based on proceduralist description, and not objectively measured routinely.

All statistical analyses were performed using R Studio (version 4.3.2). Continuous variables are summarised as mean (standard deviation [SD]) or median (interquartile range [IQR]) where appropriate, following normality assessment by Shapiro-Wilk's method. Categorical variables are summarised with counts and percentages. The number and percentage of missing data for each variable are reported. The pre-specified criteria of achieving a clinically important response ("a responder") were defined as having an increase in oxygen saturations following initial venovenous collateral occlusion of greater than or equal to 5% to a resting saturation greater than or equal to 90% at latest follow-up. Difference in oxygen saturation before and after venovenous collateral closure was assessed using paired-sample student's *t*-test. To compare differences between responders and non-responders, an independent student's *t*-test or Wilcoxon rank sum test for continuous variables, and a Fisher's exact test for categorical variables were performed. Two-tailed *P*-values less than 0.05 were considered statistically significant, and where possible, estimates were provided with the corresponding 95% confidence interval.

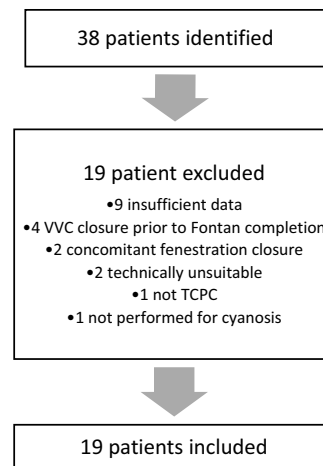


Figure 1. Flow diagram: VVC, venovenous collateral; TCPC, total cavopulmonary connection.

Results

There were 38 patients identified from the registry ($n = 1,787$), of which 19 were excluded (Figure 1). The remaining 19 patients comprised the cohort, where 53% were female, and the mean age was 19.3 ± 7.8 years (range 6–32). There were no previous instances of heart failure admission, transplant referral, or Fontan failure. Baseline characteristics are presented in Table 1. At the time of Fontan surgery, six patients (32%) had a fenestration created. Prior to VVC occlusion, three had undergone percutaneous closure, and two had spontaneously closed, therefore one patent Fontan fenestration remained.

At the time of transcatheter venovenous collateral occlusion, the mean oxygen saturation was 87% (4.3). A total of 26 collaterals were identified, averaging 1.4 per patient. Successful closure of at least one collateral was achieved in all patients. There were two unsuccessful attempts involving additional collaterals that were both described as small by the proceduralist and unable to be engaged. Complications were reported in two patients without significant long-term sequelae. One complication involved coil embolisation, successfully snared without issue. The second complication was an intimal disruption that caused local thrombus formation following device deployment and retrieval.

The median duration of follow-up after transcatheter occlusion was 4.0 years (IQR 2.9–6.6). At latest follow-up assessment, prior to any re-intervention, mean oxygen saturations had increased to 90.5% (4.4), a mean difference of 3.5% (95%CI 1.3–5.6; $p = 0.003$) from baseline. Oxygen saturations over time are plotted in supplementary Figure 1.

Functional status across the whole cohort, as measured by patient-reported NYHA classification remained unchanged compared to baseline. There were no instances of heart failure hospitalisation, arrhythmia, heart transplant referral, or death observed throughout the follow-up period. One patient, with complex comorbidities including combined variable immune deficiency and chronic granulomatous bronchiectasis, experienced progressive ankle oedema at 6-month follow-up. This condition later progressed to protein-losing enteropathy and Fontan failure at 12 months.

Thromboembolic complications were observed in two patients. One experienced a stroke 22 months after venovenous collateral

Table 1. Total cohort baseline, procedural, and outcome characteristics

<i>Baseline Characteristics</i>		
Age (years), mean (SD)		
At VVC procedure	19.3	(7.8)
At Fontan completion	3.7	(1.2)
Female, n (%)	10	(53)
Oxygen saturation (%), mean (SD)		
	87	(4.3)
Dominant ventricle, n (%)		
Left	12	(63)
Right	5	(26)
Biventricular	2	(11)
Fontan type, n (%)		
Lateral tunnel	7	(37)
Extracardiac conduit	12	(63)
NYHA*, n (%)		
I/II	17	(100)
Comorbidity, n (%)		
Heart failure admission	0	(0)
Atrial arrhythmia	5	(26)
Thromboembolism	1	(5)
Pacemaker	1	(5)
Ventricular arrhythmia/AICD	0	(0)
PLE or Fontan failure	0	(0)
Ventricular systolic impairment*, n (%)		
None/mild	15	(88)
Moderate/severe	2	(12)
AVVR*, n (%)		
None/mild	15	(88)
Moderate/severe	2	(12)
<i>Procedural Characteristics</i>		
Number of VVC per patient, n (%)		
1	13	(68)
2	5	(26)
3	1	(5)
Successful closure, n (%)		
Large VVC (n = 21)	21	(100)
Small VVC (n = 5)	3	(60)
Complication, n (%)		
	2	(8)
Transcatheter closure method, n (%)		
Device only	15	(63)
Coil only	6	(25)
Device and coil	1	(4)
Device and liquid embolic agent	2	(8)
<i>Outcome data</i>		
Follow-up (years), median (IQR)		
	4.0	(2.9, 6.6)

(Continued)

Table 1. (Continued)

Oxygenation Δ (%), mean (SD)	3.5	(4.4)	P = 0.003
Outcomes, n (%)			
Death	0	(0)	
Heart failure admissions	0	(0)	
New heart failure findings on exam	1	(5)	
Arrhythmia	0	(0)	
Thromboembolism	2	(11)	
PLE or Fontan failure	1	(5)	
Heart transplantation or referral	0	(0)	
NYHA Δ^\ddagger , mean (SD)	0	(-0.5, 0.5)	P = 1.0
Ventricular systolic impairment Δ^\ddagger , n (%)			P = 0.3
None/Mild	16	(94)	
AVVR Δ^\ddagger , n (%)			P = 0.6
None/Mild	17	(100)	

AICD= automatic implantable cardioverter-defibrillator; AVVR= atrioventricular valve regurgitation; PLE= protein-losing enteropathy; WVC= venovenous collateral. There were 2*, 3[‡] and 4[‡] missing observations, respectively.

Table 2. Comparison between responders and non-responders

	Responders n = 9	Non-Responders n = 10	P-value
Age (years), mean (SD)			
At WVC procedure	18.3 (7.4)	20.2 (8.4)	0.7
At Fontan	3.7 (0.7)	3.8 (1.5)	0.7
Female, n (%)	5 (56)	5 (50)	1.0
Oxygen saturation (%), mean (SD)	87 (4.6)	87 (4.2)	0.7
Delta oxygen saturation (%), mean (SD)	6.8 (2.5)	0.5 (3.5)	<0.001
Follow-up (years), median (IQR)	4.0 (3.3-6.9)	4.0 (2.0-5.4)	0.7
Haemodynamics			
Fontan pressure (mmHg)†, mean (SD)	12.9 (1.7)	15.6 (2.2)	0.02
Superior vena cava pressure (mmHg)*, mean (SD)	12.7 (1.1)	15.2 (1.9)	0.007
PCWP/VEDP (mmHg)‡, mean (SD)	8.3 (1.5)	10.6 (2.7)	0.1
Transpulmonary gradient (mmHg)†, mean (SD)	4.8 (1.7)	5.0 (1.0)	0.6
PVR (Wood units)‡, mean (SD)	1.0 (0.3)	1.4 (0.5)	0.4
Number of WVC, median (IQR)	1.0 (1.0-1.0)	1.5 (1.0-2.0)	0.2
Number of occlusion devices used, median (IQR)	1.0 (1.0-3.0)	1.5 (1.0-2.0)	0.1
NYHA delta	-0.7 (0.5)	0.4 (0.8)	0.02

PCWP= pulmonary capillary wedge pressure; PVR= pulmonary vascular resistance; VEDP= ventricular end-diastolic pressure; WVC= venovenous collateral. There were 3*, 6[‡], and 7[‡] missing observations, respectively.

closure while receiving aspirin therapy, with the aetiology suspected to be embolic. Despite a clinically significant improvement in oxygen saturations (from 77% to 90%), residual flow was identified during a repeat catheterisation, and further occlusion of the same collateral vessel was performed. For the second case, stroke occurred 16 months following venovenous collateral occlusion, but was determined to be unrelated as thrombus was identified within the pulmonary artery stump. Of note however, the patient had been transitioned from warfarin to aspirin following venovenous collateral occlusion.

Among the cohort of 19 patients, 9 (47%) met the pre-specified criteria for achieving a clinically important response (Table 2). Only one patient achieved increased oxygen saturations by 5% to greater than 90%, but did not sustain this, falling below 90% oxygen at latest follow-up. This patient had elevated Fontan pressures (18 mmHg). A comparison between responders and non-responders revealed significant differences in Fontan pressures at baseline. Responders had lower central venous pressure (12.9 mmHg v 15.6 mmHg; $p = 0.02$) and lower superior vena caval pressure (12.7 mmHg v 15.2 mmHg; $p = 0.007$) compared to

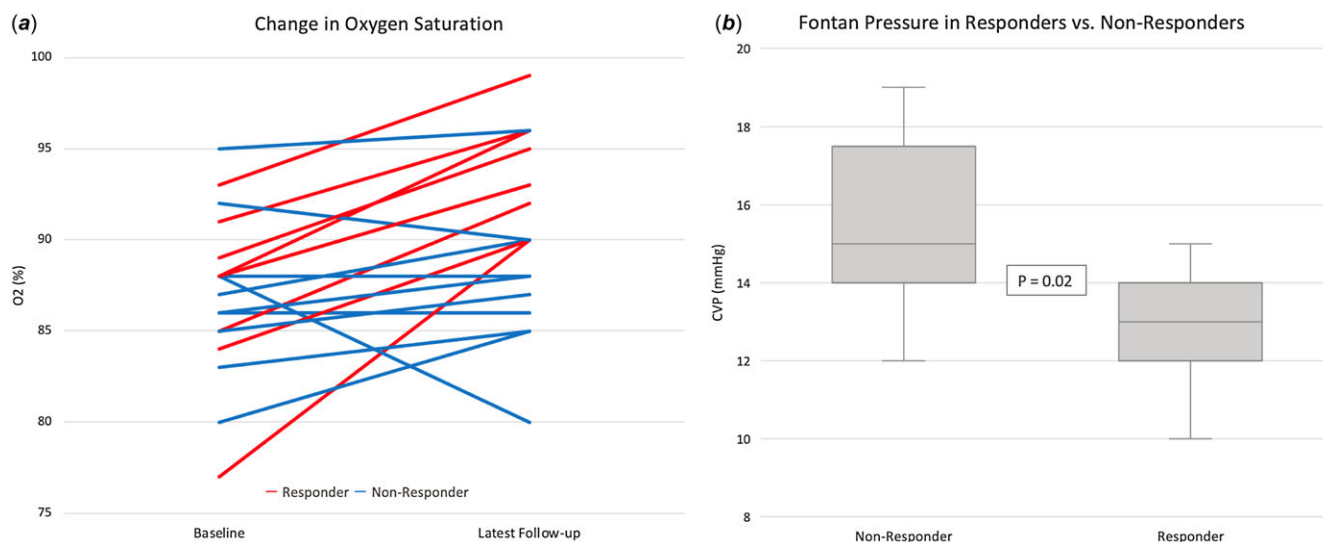


Figure 2. Oxygen saturation at baseline and latest follow-up (A) and the fontan pressure at baseline between responders and non-responders (B).

non-responders (Figure 2). Responders also reported improvements in functional status (NYHA classification) compared to non-responders (-0.7 vs. 0.4, $p = 0.02$). Sensitivity analysis excluding the patient with a patent Fontan fenestration revealed similar results (see supplementary Table 1).

Out of the initial cohort of 19 patients, 5 (26%) underwent re-intervention following initial venovenous collateral closure, with a mean time of 2.3 (1.3) years between procedures. The most common indication for re-intervention was hypoxaemia, in four out of the five cases. The remaining patient underwent re-intervention following a stroke, as described previously. Among the four patients who required re-intervention for cyanosis, one experienced a clinically important improvement in oxygenation but continued to report exertional symptoms and demonstrated desaturation upon exercise. Consequently, this patient underwent additional transcatheter occlusion procedure 2 years after the initial procedure with symptomatic improvement, yet to undergo further exercise testing. The three remaining patients did not experience clinically important improvements following initial closure. One had a patent Fontan fenestration, subsequently closed 6 months later, resulting in a clinically important improvement in oxygenation. The other two patients underwent further transcatheter venovenous collateral occlusion procedures, performed at 3 and 4 years after the initial intervention, respectively, resulting in modest improvements in oxygenation.

Discussion

We observed a modest increase in oxygenation post-transcatheter venovenous collateral occlusion in a small contemporary Fontan cohort. Importantly, this effect was sustained over a median follow-up duration of 4 years, the longest such reported in the literature. These results are consistent with pre-existing data reporting similar improvements in systemic oxygenation but over a shorter 2-year follow-up period.^{8,10}

Although the effect on oxygen saturations was modest, chronic hypoxaemia is an important predictor of mortality amongst those living with a Fontan circulation³, as well as impaired fertility and pregnancy loss, renal dysfunction, impaired neurocognitive

development, and perioperative morbidity.⁴⁻⁷ The development of hypoxaemia should prompt clinicians to investigate potentially treatable causes, of which venovenous collaterals are amongst the most common.¹⁴

Despite the aetiology of venovenous collaterals not being completely understood, the predominating theory is they develop due to the recanalisation of embryological venous connections in response to the elevated systemic venous pressure inherent to Fontan physiology.² This is supported by multiple case reports and small cohort data suggesting a relationship between their presence and higher Fontan pressures.¹⁰ Conflicting data from larger series have found no difference in Fontan pressures in those with and without venovenous collaterals, though this may be due to the decompressive nature of the collaterals themselves.^{1,8}

Controversy regarding the safety and long-term effectiveness of this procedure exist. In the setting of elevated Fontan pressures, venovenous collateral occlusion may be harmful and has been associated with increased mortality, especially when Fontan pressures exceeded 18 mmHg.¹² Importantly, this cohort included relatively high-risk Fontan patients including those with isomerism and atriopulmonary connections, as well as performing venovenous collateral closure in preparation for heart transplant referral or Fontan conversion, and not solely for the indication of cyanosis. In our cohort, we observed few adverse outcomes associated with the intervention. Importantly, no instances of heart failure hospitalisations, transplant referrals, or mortality were reported during the median follow-up period of 4 years, among the longest durations reported in the literature. Although two thromboembolic events were observed, this is a known complication of the Fontan circulation even in the absence of venovenous collateral occlusion, reported in up to 25% of adults.¹⁵

The other prevailing argument against venovenous collateral closure is that it may be a futile undertaking. Following occlusion of a decompressing collateral, a subsequent increase in central venous pressure may lead to the recanalisation of “new” collateral networks and the return of progressive hypoxaemia. This has been observed anecdotally, and in the setting of elevated Fontan pressures, the formation of new collateral networks appears more likely¹⁶, though in a minority of patients (6%).¹² The sustained

improvement in oxygenation and the low rate of re-intervention for new venovenous collaterals may suggest futility is less of a concern in this relatively low-risk, contemporary Fontan cohort.

Although only 47% of patients achieved the pre-specified clinically important response, this was associated with lower Fontan pressures at baseline, as well as modest improvement in functional capacity. These findings offer hope that following careful patient selection, a potentially favourable outcome may be associated with venovenous collateral closure in patients experiencing symptomatic cyanosis in the absence of elevated Fontan pressures.

Limitations of this study include the small sample size and the presence of missing and non-standardised variables inherent to registry-based data reliant upon treating specialists submitting correspondence. The study would have been enhanced with the inclusion of formal exercise data and objective quantification of collateral size and flow. Advances such as 4D flow at cardiac MRI may improve our ability to explore associations between collateral size, Fontan pressures, and the development of new collaterals post-closure.¹⁷ Future prospective studies may consider incorporating longitudinal assessment of Fontan pressures, venovenous collateral flow, and cardiopulmonary exercise testing.

Conclusion

In a contemporary group of Fontan patients with chronic hypoxaemia, transcatheter occlusion of venovenous collaterals proved to be a safe procedure and yielded a modest increase in oxygenation over a median follow-up of 4 years. A clinically important improvement in oxygenation was more likely to be observed when Fontan pressures were lower. Importantly, longer-term prognosis did not appear to be adversely affected.

Supplementary material. The supplementary material for this article can be found at <https://doi.org/10.1017/S1047951124025708>.

Acknowledgements. None.

Financial support. This research received no specific grant funding from any funding agency, commercial, or not-for-profit sectors.

Competing interests. None.

References

- Evans WN, Acherman RJ, Mayman GA, et al. Fontan venovenous collaterals and hepatic fibrosis. *J Card Surg* 2020; 35: 2974–2978.
- Magee AG, McCrindle BW, Mawson J, Benson LN, Williams WG, Freedom RM. Systemic venous collateral development after the bidirectional cavopulmonary anastomosis: prevalence and predictors. *J Am Coll Cardiol* 1998; 32: 502–508.
- Schafstedde M, Nordmeyer S, Schleiger A et al. Persisting and reoccurring cyanosis after Fontan operation is associated with increased late mortality. *Eur J Cardiothorac Surg* 2021; 61: 54–61. DOI: [10.1093/ejcts/ezab298](https://doi.org/10.1093/ejcts/ezab298).
- Zentner D, Celermajer DS, Gentles T et al. Management of people With a Fontan circulation: a Cardiac Society of Australia and New Zealand Position statement. *Heart Lung Circ* 2020; 29: 5–39. DOI: [10.1016/j.hlc.2019.09.010](https://doi.org/10.1016/j.hlc.2019.09.010)
- Byrne RD, Weingarten AJ, Clark DE et al. More than the heart: hepatic, renal, and cardiac dysfunction in adult Fontan patients. *Congenit Heart Dis* 2019; 14: 765–771.
- Verrall CE, Yang JYM, Chen J et al. Neurocognitive dysfunction and smaller brain volumes in adolescents and adults with a Fontan circulation. *Circulation* 2021; 143: 878–891.
- Egbe AC, Khan AR, Ammash NM et al. Predictors of procedural complications in adult Fontan patients undergoing non-cardiac procedures. *Heart* 2017; 103: 1813–1820. DOI: [10.1136/heartjnl-2016-311039](https://doi.org/10.1136/heartjnl-2016-311039)
- Lluri G, Levi DS, Aboulhosn J. Systemic to pulmonary venous collaterals in adults with single ventricle physiology after cavopulmonary palliation. *Int J Cardiol* 2015; 189: 159–163.
- Heinemann M, Breuer J, Steger V, Steil E, Sieverding L, Ziemer G. Incidence and impact of systemic venous collateral development after Glenn and Fontan procedures. *Thorac Cardiovasc Surg* 2001; 49: 172–178.
- Sugiyama H, Yoo SJ, Williams W, et al. Characterization and treatment of systemic venous to pulmonary venous collaterals seen after the Fontan operation. *Cardiol Young* 2003; 13: 424–430.
- McElhinney DB, Mohan Reddy V, Hanley FL, Moore P. Systemic venous collateral channels causing desaturation after bidirectional cavopulmonary anastomosis: evaluation and management. *J Am Coll Cardiol* 1997; 30: 817–824.
- Poterucha JT, Johnson JN, Taggart NW, et al. Embolization of venovenous collaterals after the Fontan operation is associated with decreased survival. *Congenit Heart Dis* 2015; 10: E230–E236.
- Iyengar AJ, Winlaw DS, Galati JC, et al. The Australia and New Zealand Fontan Registry: description and initial results from the first population-based Fontan Registry. *Intern Med J* 2014; 44: 148–155.
- Masura J, Bordacova L, Tittel P, Berden P, Podnar T. Percutaneous management of cyanosis in Fontan patients using Amplatzer occluders. *Catheter Cardiovasc Interv* 2008; 71: 843–849.
- Egbe AC, Connolly HM, Niaz T, et al. Prevalence and outcome of thrombotic and embolic complications in adults after Fontan operation. *Am Heart J* 2017; 183: 10–17. DOI: [10.1016/j.ahj.2016.09.014](https://doi.org/10.1016/j.ahj.2016.09.014)
- Ozawa H, Hoashi T, Ohuchi H, Kurosaki K, Ichikawa H. Long-term outcomes after fenestration closure in high-risk Fontan candidates. *Pediatr Cardiol* 2021; 42: 1356–1364. DOI: [10.1007/s00246-021-02619-9](https://doi.org/10.1007/s00246-021-02619-9)
- Raimondi F, Martins D, Coenen R et al. Prevalence of venovenous shunting and high-output state quantified with 4D flow MRI in patients with fontan circulation. *Radiol Cardiothorac Imaging* 2021; 3: e210161. doi: [10.1148/rct2.10161](https://doi.org/10.1148/rct2.10161).