

# Siamese Twins With Craniofacial Duplication and Bilateral Cleft Lip/Palate in a Ceramic Representation of the Chimú Culture (Peru): A Comparative Analysis With a Current Case

Harry Pachajoa,<sup>1,2</sup> Maria F. Hernandez-Amaris,<sup>1</sup> Gloria Liliana Porras-Hurtado,<sup>3,4</sup> and Carlos A. Rodriguez<sup>5</sup>

<sup>1</sup>Centro de Investigaciones en Anomalías Congénitas y Enfermedades Raras, Universidad Icesi, Cali, Colombia

<sup>2</sup>Fundación Clínica Valle del Lili, Cali, Colombia

<sup>3</sup>Comfamiliar Risaralda, Pereira, Colombia

<sup>4</sup>Investigador asociado a Colciencias, Colombia

<sup>5</sup>Museo Arqueológico Julio Cesar Cubillos, Universidad del Valle, Cali, Colombia

Craniofacial duplication or diprosopus is a very rare malformation that is present in approximately 0.4% of conjoined twins. Here is presented a case of craniofacial duplication in association with bilateral cleft lip/palate in both heads found in a ceramic representation from the early Chimú culture from Peru. A comparative analysis is made with a current case of a 28-week-old fetus with similar characteristics. After reviewing the medical literature on conjoined twins, very few reports of facial cleft in both twins were found, with no reports at all of bilateral cleft lip/palate. This ceramic crock is considered one of the first representations suggestive of craniofacial duplication, and probably the first reporting it in association with facial cleft.

■ **Keywords:** conjoined twins, congenital abnormalities, prenatal diagnosis

The prevalence of conjoined twins is reported in 1 of every 75,000 live births (Castilla et al., 1988); these events are classified in terms of symmetry, place of fusion, and grade of duplication (Potter & Craig, 1975). The most frequent type is thoracopagus (32.7%), and the least frequent is diprosopus (0.4%). The latter are Siamese twins characterized by having two faces and one single body (Machin, 1993). This craniofacial duplication is an extremely rare event, with very few reports in the medical literature (Molina et al., 2008; Okazaki et al., 1987); its estimated prevalence is 1 of every 180,000 to 15 million live births (Al Muti Zaitoun et al., 1999). Here is presented a case of craniofacial duplication with bilateral cleft palate in a pre-Hispanic ceramic representation of the Chimú culture from Peru, and a comparative analysis of this case with a current one.

## Materials and Methods

From 2011 to 2013, a multidisciplinary research project on health and diseases in prehispanic art from the Pacific coast of South America was conducted by the Universidad Icesi and Universidad del Valle in Cali, Colombia. A hallmark

of this project was a rare anthropomorphic ceramic crock identified by the Brünin National Archeological Museum (Lambayeque, Peru). This crock, of exceptional iconography, belonged to the Chimú culture (Peru, 900–1470 A.D.) and appears to be the representation of Siamese twins with craniofacial duplication plus bilateral cleft lip and palate. A review of the literature was made from searches in Pubmed, Scopus, Embase and DOAJ databases using as keywords the terms ‘diprosopus’, ‘conjoined twins’ and ‘Siamese’; however, there was no evidence of a similar case reported in the medical literature.

Shortly after, a similar case of a 28 week-old fetus was presented during a meeting from the Latin-American Collaborative Study of Congenital Malformations (ECLAMC),

RECEIVED 13 February 2014; ACCEPTED 11 March 2014. First published online 28 April 2014.

ADDRESS FOR CORRESPONDENCE: Harry Pachajoa, Centro de Investigaciones en Anomalías Congénitas y Enfermedades Raras, Universidad Icesi, Cali, Colombia. E-mail: [hmpachajoa@icesi.edu.co](mailto:hmpachajoa@icesi.edu.co), [mfernandez@icesi.edu.co](mailto:mfernandez@icesi.edu.co)



**FIGURE 1**  
(Colour online) Effigy crock from the Chimú culture. Possibly representing conjoined twins with craniofacial duplication and cleft lip/palate.

which was held in Caxias do Sul, Brazil, in November 2013. The report and presentation of this case led us to review and write about this subject from a multidisciplinary point of view, taking into account iconographic, archeological, medical and genetic data.

## Results

### Anthropological Analysis

The anthropological analysis suggests an anthropomorphic representation made in the top of an effigy jar or crock, where a pair of conjoined twins with bilateral cleft palate can be distinguished (see [Figures 1](#) and [2](#)).

The ceramic piece is representative of the early Chimú culture, which existed from 900 to 1470 A.D. in the north coast of Peru. This culture was the continuation of a previous civilization, the Moche. The capital, or political-administrative centre, of this civilization, the city of Chan-Chan, was the largest city in the world at that time; it was remarkable for being built entirely from adobe, and until



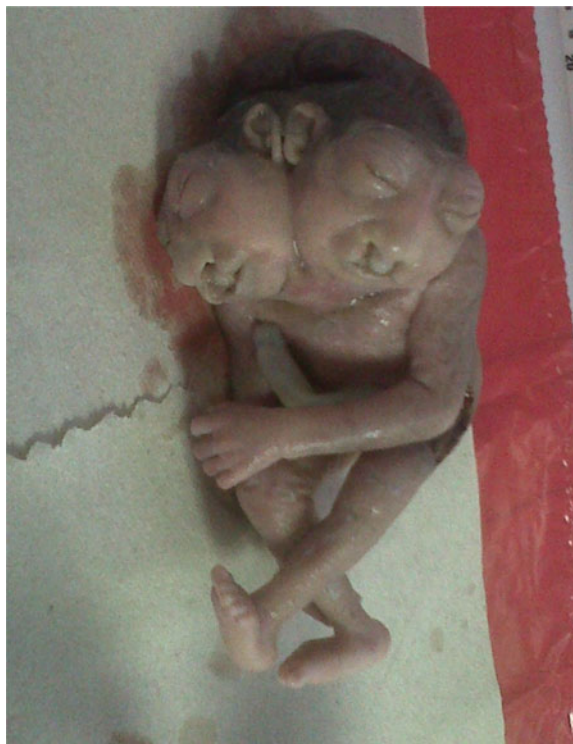**FIGURE 2**  
(Colour online) Detail of bilateral cleft lip/palate on the possible diprosopus twins represented on the Chimú crock.

today it is still recognized as one of the most splendid cities from the pre-Hispanic culture.

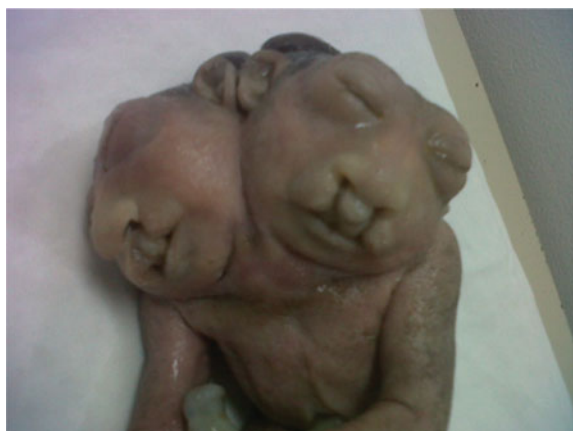
### Case Report Analysis

This analysis reports on the case of a fetus from the third pregnancy of a 37-year-old woman with a 55-year-old man. She was admitted from perinatology at the 28th week of pregnancy after detailed ultrasound findings revealed a fetus with two heads conjoined by the neck, sharing a single trunk and extremities (two arms and two legs). Each head had developed an individual spine in the most cephalic portion, which fused with each other at the thoracolumbar level where a defect of the normal curvature was evident. Both heads presented an acrania/anencephaly sequence, with the encephalic mass exposed to the amniotic cavity, and bilateral cleft lip/palate. The fetus was identified as female by the characteristics of the external genitals. The placenta was a grade 1, located in anterior position, and augmented amniotic fluid (over 8 cm) was noticed. There was no evidence of a gastric chamber and an analysis of the cardiac structure was not possible because of the fetal position. The ultrasound conclusion was '25-week-old monochorionic, monoamniotic conjoined-twins, with dicephaly and multiple structural defects not compatible with life', suggesting the indication of pregnancy termination. Following counseling, the mother agreed to schedule a C-section, which was done without any complications.

The fetus presented the characteristics previously described by the perinatologist; a muscle biopsy was taken to determine the karyotype, giving a normal result, 46,XX. The fetus was sent to anatomical pathology for postmortem examination. The subsequent report stated it was a body corresponding to female conjoined twins with two heads and a single body; both heads with anencephaly, encephalocele and bilateral cleft lip/palate (see [Figures 3](#) and [4](#)). A bilateral cranial rachischisis down to the mid thoracic spine was also evident; and after dissection, a defect in cardiac structure with a big interatrial communication was documented.

**FIGURE 3**

(Colour online) 28 week-old fetus with craniofacial duplication and bilateral cleft lip/palate.

**FIGURE 4**

(Colour online) Detail of midline defect: bilateral cleft lip/palate in both heads.

## Discussion

Many anthropomorphic malformations can be seen in artistic representations of different Peruvian cultures; most of these belong to the Moche civilization, which later gave rise to the Chimú culture. Some of these malformations include dwarfism, achondroplasia, flat feet and facial cleft (Guerra & Sanchez, 1990). Conjoined twins of the diprosopus type have been represented in various sculptures from different

cultures, such as the Tlatilco (Bendersky, 2000), and have been described in European literature from the 16th century (Bates, 2002). The crock presented in this article is probably one of the first representations of this type of Siamese twins, and likely to be the only one to document the presence of bilateral cleft palate in addition to the abnormal fusion. Nevertheless, it is also possible that this representation may be the one of classical, non-conjoined twins with bilateral lip/palate defects.

Diprosopus malformation is an entity with a variable spectrum in terms of clinical presentation, being possible to find rather partial or complete duplication of the different facial structures (Brodsky, 1939; Castilla et al., 1988; Machin, 1993; Okazaki et al., 1987; Pachajoa & Rodriguez, 2013). Although craniofacial duplication has been historically considered as a type of conjoined twins (Al Muti Zaitoun et al., 1999; Bates, 2002; Bendersky, 2000; Hahnel et al., 2003; Okazaki et al., 1987), it has also been suggested that it could be due to a duplication of the rostral aspect of the notochord (Hahnel et al., 2003). This defect could lead to the formation of two spinal axis and two neural plates, which finally turns into the duplication of the different derivatives from the neural crest (Kotrikova et al., 2007; Maruotti et al., 2009).

The congenital defects associated to diprosopus malformations include other different systems, such as the cardiovascular, gastrointestinal, respiratory, central nervous system; and also neural tube defects, the most frequent being the presentation of anencephaly, cranial rachischisis, spina bifida, duplication of the brain hemispheres and fusion of the structures in the posterior fossa (Chen, 2008; Kotrikova et al., 2007; Molina et al., 2008; Wu et al., 2002). In the reviewed literature there were very few reports of cleft lip/palate in both twins (Potter & Craig, 1975). Gorlin (1988) and Bulbul (2004) reported unilateral cleft lip/palate in both heads, but no reports of bilateral cleft lip/palate were found, leaving only with the two cases reported here. Although we recognize it is possible that this old artistic crock could be the representation of a mid-line defect in otherwise normal twins, we would still like to think it is actual evidence of a much rarer event.

## Acknowledgments

The authors are very grateful to Dr Carlos Wester La Torre, director of the Brunning National Archeological Museum, in Lambayeque, Peru, for his collaboration and for allowing us to work with the ceramic collection of the museum.

## References

- Al Muti Zaitoun, A., Chang, J., & Booker, M. (1999). Diprosopus (partially duplicated head) associated with anencephaly: A case report. *Pathology Research and Practice*, 195, 45–50.

- Bates, A. (2002). Conjoined twins in the 16th century. *Twin Research*, 5, 521–528.
- Bendersky, G. (2000). Tlatilco sculptures, diprosopus and the emergence of medical illustrations. *Perspectives in Biology and Medicine*, 43, 477–503.
- Brodsky, I. (1939). A description of a monster, diprosopus tetrophtalmus. *British Journal of Ophthalmology*, 23, 250–256.
- Bulbul, Y., Drummond, C. L., Hillion, Y., Bidat, L., & Vile, Y. (2004). Diprosopus associated with neural tube defect and facial cleft in the third trimester. *Fetal Diagnosis and Therapy*, 19, 246–250.
- Castilla, E. E., Lopez-Camelo, J. S., Orioli, I. M., Sanchez, O., & Paz, J. E. (1988). The epidemiology of conjoined twins in Latin America. *Acta Geneticae Medicae et Gemellologiae*, 37, 111–118.
- Chen, C. (2008). Syndromes, disorders and maternal risk factors associated with neural tube defects. *Taiwan Journal Of Obstetrics and Gynecology*, 47, 1–9.
- Gorlin, R. J. (1988). Diprosopus, anencephaly and facial clefting. *American Journal of Medical Genetics*, 30, 845.
- Guerra, F., & Sanchez, M. C. (1990). Las enfermedades del hombre americano. *Quinto Centenario*, 16, 19–52.
- Hahnel, S., Shramm, P., Hassfeld, S., Steiner, H. H., & Seitz, A. (2003). Craniofacial duplication (Diprosopus): CT, MR, angiography findings — case report. *Radiology*, 226, 210–213.
- Kotrikova, B., Hassfeld, S., Steiner, H. H., Hahnel, S., Krempien, R., & Muhling, J. (2007). Operative correction and follow-up of craniofacial duplication. *Plastic and Reconstructive Surgery*, 199, 985–991.
- Machin, G. A. (1993). Conjoined twins: Implications for blastogenesis. *Birth Defects Original Article Series*, 29, 141–179.
- Maruotti, G. M., Paladini, D., Napolitano, R., Mazzarelli, L. L., Russo, T., Quarantelli, M., . . . Martinelli, P. (2009). Prenatal 2D and 3D ultrasound diagnosis of diprosopus: case report with post-mortem magnetic resonance images (MRI) and review of the literature. *Prenatal Diagnosis*, 29, 992–994.
- Molina, S., Duque, J., Motta, A., Alvarado, C., & Torres, C. (2008). Duplicación facial diprosopus: Reporte de un caso y revisión de la literatura. *Latin American Journal of Dismorphology*, 1, 9–13.
- Okazaki, J., Wilson, J. L., Holmes, S. M., & Vandermark, L. L. (1987). Diprosopus: Diagnosis in utero. *American Journal of Roentgenology*, 149, 147–148.
- Pachajoa, H., & Rodriguez, C. A. (2013). Holoprosencephaly with premaxillary agenesis in a prehistoric skull. *Archives of Disease in Childhood: Fetal and Neonatal Edition*, 98, 264.
- Potter, E. L., & Craig, J. M. (1975). Multiple pregnancies and conjoined twins. *Pathology of the Fetus and Infant*, 3, 220–237.
- Wu, J., Staffenberg, D. A., Mulliken, J. B., & Shanske, A. L. (2002). Diprosopus: A unique case and review of the literature. *Teratology*, 66, 282–287.
-