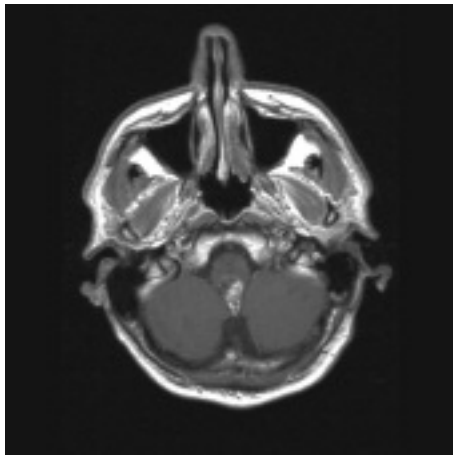


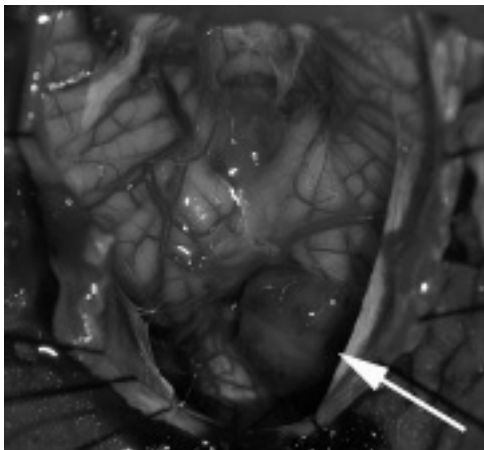
TO THE EDITOR

**Re: Fourth ventricular neurocytoma: case report and review of the literature. Cook DJ, Christie SD, Macaulay RJB, Rheume DE, Holness RO. Can J Neurol Sci 2004;31:558-564.**

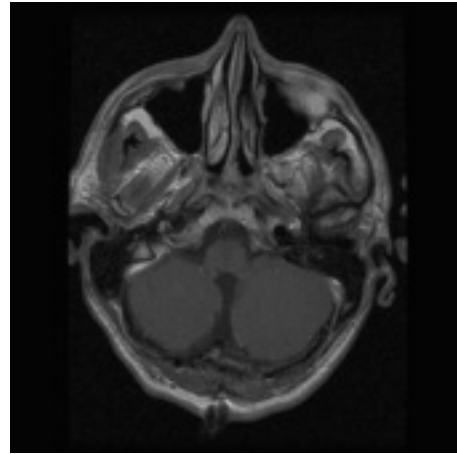
I have recently encountered an additional case of this entity. This 40-year-old, otherwise healthy man experienced a spontaneous fourth ventricle hemorrhage in September 2004. He recovered uneventfully and did not require any acute surgical intervention. Initial imaging with computed tomography (CT) and magnetic resonance imaging (MRI) showed the clot but no other lesion. Catheter angiography was also unremarkable. Serial follow-up imaging demonstrated the presence of an underlying mass lesion that became evident when the hematoma resolved (Figure 1).



**Figure 1:** Axial T1-weighted, gadolinium-enhanced MRI demonstrating a circumscribed, enhancing lesion dorsal to the medulla.



**Figure 2:** Intra-operative appearance of the central neurocytoma. The tumour can be seen protruding caudal to the right cerebellar tonsil. It extended rostrally between the cerebellar tonsils to the level of the vermis (not seen on this picture).



**Figure 3:** Axial T1-weighted gadolinium-enhanced MRI obtained following resection of the tumour showing no evidence of residual tumour.

The lesion was surgically resected in December 2004 (Figure 2).

The lesion was quite vascular and seemed to arise from the dorsal medulla. A gross total resection was achieved, and post-operative imaging did not show any residual tumour (Figure 3).

He remained neurologically intact post operatively. Pathology consisted of a fourth ventricle neurocytoma. Upon discussion at our Neuro-Oncology tumour board, we have decided not to prescribe any adjunctive therapy at present, and will follow him with serial clinical and imaging follow-up. I hope this information is useful to others who may encounter these rare tumours.

*P. Daniel McNeely  
Halifax, Nova Scotia*

TO THE EDITOR

**Irving Heller - A Tribute**

Each time someone we know dies, it diminishes us. It leaves less of the world that we knew.

Although I saw him in action only briefly, he left a life long impression. I was a junior resident in internal medicine rotating through the Montreal Neurological Institute. He already was a legend among residents for his sharp wit, keen mind and high clinical standards. I saw him a few times thereafter, exchanged patient referrals and traded greetings through a mutual acquaintance.

I came to appreciate him as someone big enough to harbor contradictions: a man of withering wit and deep compassion, a public agnostic and a private Old Testament scholar, an Olympian rationalist who thrived on the emotionalism of human relations.

Irving, may you have found the truth and the peace that you sought through your philosophical and theological researches.

*Vladimir Hachinski  
London, Ontario*