



Outbreak of *Mycoplasma pneumoniae* pneumonia in hospitalized patients: Who is concerned? Nord Franche-Comté Hospital, France, 2023–2024

From the Field

Cite this article: Zayet S, Poloni S, Plantin J, Hamani A, Meckert Y, Lavoignet C-E, Gendrin V and Klopfenstein T (2024). Outbreak of *Mycoplasma pneumoniae* pneumonia in hospitalized patients: Who is concerned? Nord Franche-Comté Hospital, France, 2023–2024. *Epidemiology and Infection*, **152**, e46, 1–5 <https://doi.org/10.1017/S0950268824000281>


Received: 22 January 2024
Accepted: 05 February 2024

Keywords:

France; Franche-Comté; é; *Mycoplasma pneumoniae* outbreak; pneumonia

Corresponding author:

Souheil Zayet;
Email: souhail.zayet@gmail.com

Souheil Zayet¹ , Samantha Poloni¹, Julie Plantin², Abdoulaye Hamani¹, Yann Meckert³, Charles-Eric Lavoignet⁴, Vincent Gendrin¹ and Timothée Klopfenstein¹

¹Infectious Diseases Department, Nord Franche-Comté Hospital, Trévenans, France; ²Microbiology Department, Nord Franche-Comté Hospital, Trévenans, France; ³Post-emergency Department, Nord Franche-Comté Hospital, Trévenans, France and ⁴Emergency Department, Nord Franche-Comté Hospital, Trévenans, France

Abstract

We report an outbreak of confirmed *Mycoplasma pneumoniae* community-acquired pneumonia (CAP) in Nord Franche-Comté Hospital, France, from 14 November 2023 to 31 January 2024. All 13 inpatients (11 adults with a mean age of 45.5 years and 2 children) were diagnosed with positive serology and/or positive reverse transcription polymerase chain reaction (RT-PCR) on respiratory specimens. All patients were immunocompetent and required oxygen support with a mean duration of oxygen support of 6.2 days. Two patients were transferred to the intensive care unit (ICU) but were not mechanically ventilated. Patients were treated with macrolides (n = 12, 92.3%) with recovery in all cases. No significant epidemiological link was reported in these patients.

Global prospective surveillance data suggest a recent re-emergence of *Mycoplasma pneumoniae* (*M. pneumoniae*) infection in Europe and Asia. This delayed re-emergence is striking because it occurred sometime after non-pharmaceutical interventions against COVID-19 were discontinued, and a possible circulation of *M. pneumoniae* is usually described as endemic, punctuated with cyclic epidemics every 3 to 5 years [1]. *M. pneumoniae* beyond the COVID-19 pandemic surveillance is needed [2, 3].

In our paper, we have highlighted an outbreak of *M. pneumoniae* infection in Nord Franche-Comté Hospital, a French district general hospital with a capacity of 1,216 beds and about 100,000 visits to its emergency rooms per year [4], so as to alert the medical community about a possible emergence of this pathogen and what appears to be its changing attributes. Our patients reside in Franche-Comté (Belfort-Montbeliard), a region of about 300,000 habitants in the East of France, close to the Swiss and German borders. In the period from 14 November 2022 to 31 January 2023 (the same period in the previous year), only one patient (a 15-year-old man) was diagnosed in our hospital for *M. pneumoniae*-associated community-acquired pneumonia (CAP) (Figure 1). Our series consisted of 13 confirmed cases of *M. pneumoniae* CAP (11 adults and 2 older children) in hospitalized patients in Nord Franche-Comté Hospital between 14 November 2023 and 31 January 2024. In adult inpatients, the mean age was 45.5 years (range: 19–70) with a male predominance (72.7%). All patients were considered as immunocompetent mostly without comorbidities (Charlson comorbidity index mean at 0.5 (range: 0–2)). Tobacco consumption was noted in 45.5% of adult patients (n = 5). The 13 patients had no direct contact with each other, and no significant epidemiological links were discovered. Two adult patients reported similar respiratory presentations in their children. *M. pneumoniae* was a part of a polymicrobial infection in only one patient, and a second one had co-infection with confirmed severe acute respiratory syndrome coronavirus 2 (SARS-CoV-2) (paucisymptomatic form with no respiratory symptoms initially). Diagnosis in all patients was based on positive serology (IgM and IgG) and/or positive specific or multiplex reverse transcription polymerase chain reaction (RT-PCR) on respiratory specimens (nasopharyngeal swab or bronchoalveolar lavage). Pulmonary consolidation or diffuse infiltrates were described in our patients with bilateral patterns in 72.7% of cases (n = 8/11). All adult patients were treated with antimicrobial drugs (spiramycin (n = 9), azithromycin (n = 1), and levofloxacin (n = 1)) with a favourable outcome. Two patients were transferred to the intensive care unit (ICU) but were not mechanically ventilated. All patients required oxygen supplementation with a mean duration of oxygen support of 6.2 days (range: 1–13) (Table 1).

© The Author(s), 2024. Published by Cambridge University Press. This is an Open Access article, distributed under the terms of the Creative Commons Attribution-NonCommercial-NoDerivatives licence (<http://creativecommons.org/licenses/by-nc-nd/4.0>), which permits non-commercial re-use, distribution, and reproduction in any medium, provided that no alterations are made and the original article is properly cited. The written permission of Cambridge University Press must be obtained prior to any commercial use and/or adaptation of the article.

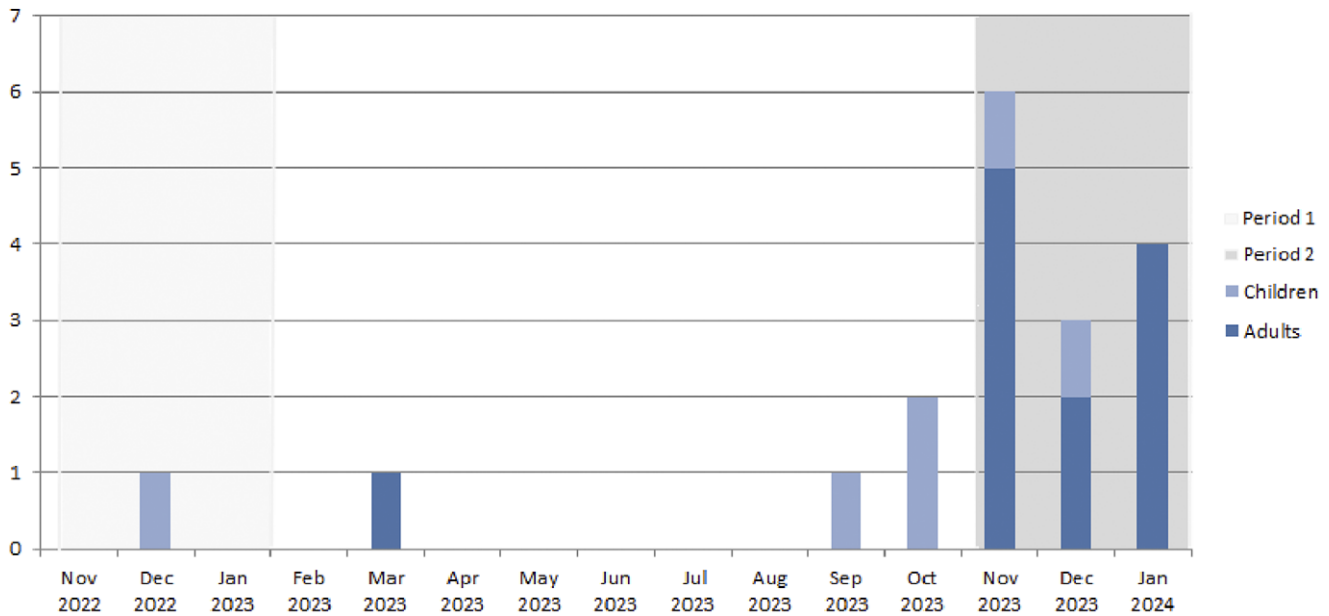


Figure 1. Monthly distribution of *Mycoplasma pneumoniae* infections (confirmed on positive IgM or positive RT-PCR on respiratory specimen) in children and adults in Nord Franche-Comté Hospital, 14 November 2023–31 January 2024 (Period 1: 14 November 2022 to 31 January 2023, Period 2: 14 November 2023 to 31 January 2024).

Over a two-and-a-half-month period from mid-November 2023 to end-January 2024 onwards, we observed an increased number of hospitalized patients diagnosed with pneumonia caused by *M. pneumoniae*, in Nord Franche-Comté Hospital, in the East of France. In our analysis, we preferred to exclude the two children because it is not unusual for children to be hospitalized for *M. pneumoniae* infection during the cold period. Larcher *et al.* have also reported an increased incidence of *M. pneumoniae* CAP in young adults hospitalized in a French university hospital ($n = 6$) during the first three weeks of November, with similar findings in patients' characteristics [5]. This case series suggests that the pathogenicity of *M. pneumoniae*, even in adult immunocompetent patients without comorbidities, has changed. All patients presented mild-to-severe pneumonia requiring supplemental oxygen support, with a high-flow nasal cannula in the oldest patient. National data from epidemiologic surveillance and the renal network of hospital laboratories showed that the number of PCR detections of *M. pneumoniae* increased significantly from October 2023 onwards; this number tripled between weeks 40 and 46 in 2023, with a further increase in week 47, especially in the under-15 and 15–44 age groups [6]. *M. pneumoniae* presented as a co-infection associated with a second pathogen (*Mycobacterium tuberculosis* and SARS-CoV-2) in two patients, suggesting that it may preferentially concern patients with pre-existing lung parenchymal involvement/disease. The highest macrolide resistance *M. pneumoniae* (MRMp) rate was detected in Taiwan from April 2018 to March 2019 with 42 of 53 isolates (79%) [7], with a high prevalence also in Japan [7, 8]. In France, the MRMp detection rate was 13% ($n = 3$) and 12% ($n = 2$) in 2018 and 2019, respectively; however, no resistant strains were found in 2017 and 2020 [7]. In our series, only one patient did not respond to macrolides after 5 days of treatment with ICU admission, raising the issue of a possible MRMp (no antimicrobial susceptibility testing was performed for this

patient, which limits this hypothesis). One final point to emphasize is the discordance between serology and PCR results (which were negative in three patients and low positive in two patients). This can be explained by the fact that the respiratory sample was performed 1–3 days after the introduction of antibiotics in these patients.

One of the limitations of our paper was the absence of baseline number of cases in our region pre-COVID-19. This does not lead us to conclude for certain if these cases represent a truly unusual increase or simply a re-emergence of *M. pneumoniae* following the COVID-19 pandemic. Nevertheless, providers should more seriously consider *M. pneumoniae* in their differential diagnosis and testing choices; *M. pneumoniae* serology still has a place in molecular biology and should be performed only in patients with negative PCR and compatible symptoms without other diagnoses. Rapid PCR negativity seems to be good evidence that patients are non-contagious shortly after the start of antimicrobial drugs.

We recommend that worldwide surveillance of *M. pneumoniae* is needed [2, 3] at the present time.

Data availability statement. Data are available on request due to privacy restrictions. The data presented in this case study are available on request from the corresponding author.

Author contribution. Conceptualization: C-E.L., J.P., T.K., V.G., S.Z.; Data curation: C-E.L., S.P., S.Z.; Funding acquisition: C-E.L., J.P.; Investigation: A.H., S.P., T.K., Y.M., S.Z.; Resources: A.H., S.P., Y.M., S.Z.; Software: A.H., S.P., Y.M.; Methodology: J.P., T.K., S.Z.; Formal analysis: S.P., S.Z.; Supervision: T.K.; Validation: T.K., V.G.; Writing – review & editing: T.K., V.G.; Visualization: V.G.; Writing – original draft: S.Z.

Funding statement. This research received no external funding.

Informed consent statement. We made sure to keep participant data confidential and in compliance with the Declaration of Helsinki.

Competing interest. The authors declare no conflicts of interest.

Table 1. Characteristics of patients hospitalized for *Mycoplasma pneumoniae* infections in Nord Franche-Comté Hospital, 14 November 2023–14 January 2024

Case	Sex	Age	Tobacco consumption/CCI/ immunosuppression	Clinical features	Serology (date)	RT-PCR/ specimen*/Ct (date)	CRP (mg/L)// acute kidney failure/ hepatitis**	Imaging findings (chest X-ray, echography or CT)	Oxygen support/days	Antimicrobial drugs/ (1st day)	Hospitalization/ICU admission/MV	Hospital length stay/ outcome
1	F	67	No/2**/no	Fever, sweating, weight loss, dyspnoea	ND	Positive multiplex RT-PCR/BAL / ND (16/11/23)	120/no/yes	Bilateral GGO (CT)	Yes (9 L/min)/13	3GC–spiramycin/ piperacillin–tazobactam (14/11/23)–levofloxacin (20/11/23)	Yes/yes/no	33/recovery (discharged)
2	M	39	Yes/0/no	Fever with ILI, cough*****	IgM >27UA/mL/IgG > 200UA/ mL (21/11/23)	Positive specific RT-PCR/NP/40 (21/1/23)	110/no/no	Bilateral consolidation with a basal distribution (CT)	Yes (4 L/min)/6	3GC–spiramycin (18/11/23)	Yes/no/no	6/recovery (discharged)
3	M	43	No/0/no	Fever with ILI, cough, macular rash*****	IgM >27UA/mL/IgG > 200UA/ mL (28/11/23)	Positive-specific RT-PCR/NP/ high (28/11/23)	232/no/yes	Unilateral lower lobar pneumonia (CT)	Yes (2 L/min)/3	Spiramycin (27/11/23)	Yes/no/no	4/recovery (discharged)
4	F	35	Yes/0/no	Fever, dysphagia, dyspnoea	IgM >27UA/mL/IgG > 200UA/ mL (27/11/23)	Negative-specific RT-PCR/NP (27/11/23)	91/no/ND	Unilateral lower lobar pneumonia (CT)	Yes (2 L/min)/4	Spiramycin (26/11/23)	Yes/no/no	4/recovery (discharged)
5	M	11	No/0/no	Fever, cough, dyspnoea	IgM >27UA/mL/IgG > 200UA/ mL (23/11/23)	ND	29/no/no	Bilateral alveolar-interstitial syndrome (echography)	Yes (1 L/min)/ ND	Azithromycin (23/11/23)	Yes/no/no	6/recovery (discharged)
6	M	59	Yes/2**/no	Cough, dyspnoea*****	IgM =17UA/mL/IgG > 200UA/ mL (28/11/23)	Positive-specific RT-PCR/NP/ND (28/11/23)	120/no/yes	Bilateral micro-nodular consolidation (CT)	Yes (3 L/min)/10	Spiramycin (27/11/23)	Yes/no/no	10/recovery (discharged)
7	M	39	No/0/no	Fever, cough, dyspnoea	IgM >27UA/mL/IgG = 72UA/ mL (14/12/23)	Positive-specific RT-PCR/NP/ND (13/12/23)	83/no/yes	Bilateral micro-nodular with unilateral basal consolidation (CT)	Yes (1 L/min)/3	Amoxicillin–clavulanate–spiramycin (13/12/23)	Yes/no/no	5/recovery (discharged)
8	M	39	Yes/0/no	Fever, cough	ND	Positive-specific RT-PCR/NP/ND (11/12/23)	130/no/no	Bilateral interstitial pneumonia (X-ray)	Yes (1 L/min)/1	3GC–azithromycin (11/12/23)	Yes/no/no	1/recovery (discharged)
9	M	12	No/ 0/no	Cough, dyspnoea, macular rash	IgM >27UA/mL/IgG = 13UA/ mL (30/12/23)	ND	25/no/no	Bilateral interstitial pneumonia (X-ray)	Yes (1 L/min)/1	Azithromycin (30/12/23)	Yes/no/no	1/recovery (discharged)
10	F	46	No/0/no	Fever with ILI, cough, dyspnoea	IgM >27UA/mL/IgG = 147UA/ mL (08/01/24)	Negative-specific RT-PCR/NP (08/01/24)	25/no/yes	Bilateral consolidation with a basal	Yes (2 L/min)/5	Amoxicillin–clavulanate–	Yes/no/no	6/recovery (discharged)

(Continued)

Table 1. (Continued)

Case	Sex	Age	Tobacco consumption/CCI/ immunosuppression	Clinical features	Serology (date)	RT-PCR/ specimen*/Ct (date)	CRP (mg/L)// acute kidney failure/ hepatitis**	Imaging findings (chest X-ray, echography or CT)	Oxygen support/days	Antimicrobial drugs/ (1st day)	Hospitalization/ICU admission/MV	Hospital length stay/ outcome
11	F	70	No/2/no	Fever, dyspnoea, vomiting	ND	Positive-specific RT-PCR/NP/ND (24/01/24)	165/yes/no	Unilateral consolidation with a basal distribution (CT)	Yes(2 L/min)/10	Amoxicillin–clavulanate–spiramycin (16/01/24)	Yes/no/no	11/recovery (discharged)
12	M	42	Yes/0/no	Fever, cough, dyspnoea	IgM =18UA/mL/IgG = 150UA/ mL (26/01/24)	Negative-specific RT-PCR/NP (29/01/24)	120/no/no	Bilateral micro-nodular with unilateral basal consolidation (CT)	Yes (2 L/min)/7	Amoxicillin–spiramycin (26/01/24)	Yes/no/no	8/recovery (discharged)
13	M	19	No/0/no	Fever, dyspnoea, abdominal pain, vomiting	IgM >27UA/mL/IgG = 165UA/ mL (30/01/24)	ND	120/yes/no	Bilateral consolidation with a basal distribution (CT)	Yes (15 L/min)/7	3GC–spiramycin (26/01/24)	Yes/yes/no	10/recovery (discharged)

Abbreviations: 3GC: third-generation cephalosporin; BAL: bronchoalveolar lavage; CCI: Charlson Comorbidity Index; CT: computed tomography; F: female; ILI: influenza-like illness; GGO: ground-glass opacities; M: male; ND: not determined/done; NP: nasopharyngeal swab; MV: mechanic ventilation; RT-PCR: reverse transcription polymerase chain reaction; ICU: intensive care unit.

*We identified a polymicrobial infection in patient 1 with associated other bacterial species (*Serratia marcescens* and *Mycobacterium tuberculosis*). Patient 7 was initially hospitalized for confirmed SARS-CoV-2 infection with concomitant *Mycoplasma pneumoniae* community-acquired pneumonia.**Five patients (1, 6, 7, 10, 11, and 13) presented hepatitis with cholestasis. ***Three patients (1, 6, and 11) with Chalson Comorbidity Index at 2 had underlying cardiovascular diseases. ****Patients 2 and 3 reported similar respiratory presentations in their children; *****Patient 6 reported a recent travel in Guyana since 2 weeks.

We performed an NP swab for specific RT-PCR QIAstat* for *M. pneumoniae* by sequence analysis of the p1 adhesin gene. We also performed LBA specimens for DiagCORE*, Multiplex Respiratory Panel 2 – SAT Dx., which detects viral and bacterial pathogens including human mastadenovirus A–G (formerly adenovirus), primate bocaparvovirus 1 + 2 (formerly bocavirus), human (hMPV), rhinovirus/enterovirus, influenza A virus (as no subtype, subtype H1, H1N1/2009, or H3), influenza B virus, human respirovirus 1 or 3, human orthorubulavirus 2 or 4 (formerly human parainfluenza virus types 1–4), human orthopneumovirus, *M. pneumoniae*, *Legionella pneumophila*, *Bordetella pertussis*, and *Chlamydia pneumoniae*, coronavirus (differentiating HKU1, NL63, OC43, or 229E), human metapneumovirus A/B, and SARS-CoV-2.

References

- [1] **Beeton ML**, et al. (2020) *Mycoplasma pneumoniae* infections, 11 countries in Europe and Israel, 2011 to 2016. *Euro Surveill* **25**(2), 1900112.
- [2] **Meyer Sauteur PM**, et al. (2022) *Mycoplasma pneumoniae* beyond the COVID-19 pandemic: Where is it? *Lancet Microbe* **3**(12), e897.
- [3] **Meyer Sauteur PM**, et al. (2023) *Mycoplasma pneumoniae*: Delayed re-emergence after COVID-19 pandemic restrictions. *Lancet Microbe* **5**, e100–e101.
- [4] **Zayet S**, et al. (2023) *Campylobacter fetus* invasive infections and risks for death, France, 2000–2021. *Emerging Infectious Diseases* **29**(11), 2189–2197.
- [5] **Larcher R**, et al. (2023) *Mycoplasma pneumoniae* is back! Is it the next pandemic? *Anaesthesia, Critical Care and Pain Medicine* **43**, 101338.
- [6] Augmentation des infections à *Mycoplasma pneumoniae* en France | Santé publique France (Internet). (cité 12 déc 2023). Disponible sur: <https://www.santepubliquefrance.fr/les-actualites/2023/augmentation-des-infections-a-mycoplasma-pneumoniae-en-france>.
- [7] **Meyer Sauteur PM**, et al. (2022) *Mycoplasma pneumoniae* detections before and during the COVID-19 pandemic: Results of a global survey, 2017 to 2021. *Euro Surveill* **27**(19), 2100746.
- [8] **Tashiro M**, et al. (2017) Comparison of efficacy of antimicrobial agents among hospitalized patients with *mycoplasma pneumoniae* pneumonia in Japan during large epidemics of macrolide-Resistant *M. Pneumoniae* infections: A Nationwide observational study. *Clinical Infectious Diseases* **65**(11), 1837–1842.