

Anterior cingulate grey-matter deficits and cannabis use in first-episode schizophrenia

PHILIP R. SZESZKO, DELBERT G. ROBINSON, SERGE SEVY, SANJIV KUMRA, CLAUDIA I. RUPP, JULIA D. BETENSKY, TODD LENCZ, MANZAR ASHTARI, JOHN M. KANE, ANIL K. MALHOTRA, HANDAN GUNDUZ-BRUCÉ, BARBARA NAPOLITANO and ROBERT M. BILDER

Background Despite the high prevalence of cannabis use in schizophrenia, few studies have examined the potential relationship between cannabis exposure and brain structural abnormalities in schizophrenia.

Aims To investigate prefrontal grey and white matter regions in patients experiencing a first episode of schizophrenia with an additional diagnosis of cannabis use or dependence ($n=20$) compared with similar patients with no cannabis use ($n=31$) and healthy volunteers ($n=56$).

Method Volumes of the superior frontal gyrus, anterior cingulate gyrus and orbital frontal lobe were outlined manually from contiguous magnetic resonance images and automatically segmented into grey and white matter.

Results Patients who used cannabis had less anterior cingulate grey matter compared with both patients who did not use cannabis and healthy volunteers.

Conclusions A defect in the anterior cingulate is associated with a history of cannabis use among patients experiencing a first episode of schizophrenia and could have a role in poor decision-making and in choosing more risky outcomes.

Declaration of interest None. Funding detailed in Acknowledgements.

The prevalence of cannabis use in schizophrenia can range up to 43% (Bersani *et al*, 2002) and poses unique treatment challenges (Green *et al*, 2004). The use of cannabis in schizophrenia tends to be associated with earlier age at first psychotic episode, especially among male patients (Van Mastrigt *et al*, 2004), and is associated with an unfavourable outcome (Henquet *et al*, 2005). Although numerous studies have identified frontal brain structural abnormalities in schizophrenia (Goldstein *et al*, 1999; Gur *et al*, 2000), little research has been directed at understanding the potential association between these abnormalities and cannabis use. Animal studies suggest that using Δ^9 -tetrahydrocannabinol, the main psychoactive component of cannabis, may be neurotoxic to the frontal lobes (Verrico *et al*, 2003), which are believed to have a key role in the neurobiology of schizophrenia (Goldman-Rakic & Selemon, 1997). In this study we investigated three prefrontal cortical regions (the superior frontal gyrus, anterior cingulate gyrus and orbital frontal lobe) implicated in drug addiction (Goldstein & Volkow, 2002; Tucker *et al*, 2004), in a sample of patients with a first episode of schizophrenia with or without a history of cannabis use compared with healthy volunteers. We tested the hypothesis that patients with the dual diagnosis would have greater prefrontal structural abnormalities compared with patients who did not use cannabis and with healthy volunteers.

METHOD

The 51 patients included in this study were recruited from admissions to the in-patient service at the Zucker Hillside Hospital in Glen Oaks, New York, and were participating in clinical trials comparing the efficacy of atypical antipsychotic drugs. All patients were interviewed using the Structured Clinical Interview for Axis I DSM-IV Disorders

(SCID; First *et al*, 1994) and met DSM-IV criteria (American Psychiatric Association, 1994) for schizophrenia ($n=36$), schizoaffective disorder ($n=8$) or schizophreniform disorder ($n=7$). Of the 51 patients with schizophrenia included in this study, 8 had a diagnosis of cannabis abuse and 12 had a diagnosis of cannabis dependence. Of the 20 patients with a diagnosis of either cannabis abuse or dependence, 6 had a diagnosis of alcohol abuse ($n=5$) or dependence ($n=1$). Among the 6 patients who had a diagnosis of alcohol abuse or dependence, other substance use diagnoses included cocaine abuse ($n=1$), hallucinogen abuse ($n=1$) and opioid dependence ($n=1$). None of the 14 patients with a diagnosis of cannabis abuse or dependence had any other substance use diagnosis. Only 2 of the 31 patients without a diagnosis of cannabis abuse or dependence had any other substance use diagnosis (1 with alcohol abuse and 1 with alcohol dependence). Twenty-five patients were antipsychotic drug-naïve at the time of the scan, including 6 patients from the group with cannabis use and 19 patients from the group without cannabis use. The median duration of antipsychotic drug exposure from entry into the clinical trial and the magnetic resonance imaging examination was 0 weeks (range 0–34 weeks).

Fifty-six healthy volunteers were recruited from local newspaper advertisements and through word of mouth in the community and denied any history of psychiatric or medical illness as determined by clinical interview and the non-patient version of the SCID (SCID-NP; Spitzer & Williams, 1988). Thus, no one in the healthy comparison group had a substance use diagnosis. Exclusion criteria for all study participants included serious neurological or endocrine disorder, any medical condition or treatment known to affect the brain, and meeting DSM-IV criteria for mental retardation. All procedures were approved by the local institutional review board and written informed consent was obtained from all participants.

Classification of handedness was based on a modified version of the Edinburgh Inventory consisting of 20 items (Oldfield, 1971). Participants with a laterality quotient greater than 0.70 were classified as dextral and the rest as non-dextral (Schachter *et al*, 1987). Handedness for 3 patients without cannabis use and 9 healthy volunteers was assessed solely on the basis of handwriting preference.

Imaging procedures

Magnetic resonance imaging (MRI) scans were conducted at Long Island Jewish Medical Center and were acquired in the coronal plane using three-dimensional fast spoiled gradient recalled acquisition with inversion recovery (time to repetition) 12.7 ms or 14.7 ms, echotime 4.5 ms or 5.5 ms, field of view 22 cm) on a 1.5 T whole-body superconducting imaging system (General Electric, Milwaukee, Wisconsin, USA). This sequence produced 124 contiguous images (slice thickness 1.5 mm) through the whole head with in-plane resolution of 0.86 mm × 0.86 mm in a 256 × 256 matrix.

Measurement procedures

All measurements were completed in MEDx (Sensor Systems, Sterling, Virginia, USA). The images were aligned along the anterior and posterior commissures for standardisation across individuals and flipped randomly in the right-left axis. Scans were mixed together randomly and no identifying information was available to the operator from the scan. All measurements were thus completed by an operator who was masked to group membership and hemisphere.

Total intracranial contents

Measurement of total intracranial contents was completed in MEDx by computing the volume of the total cerebrum, cerebrospinal fluid, cerebellum and brainstem. Interrater reliability between two raters as assessed by intraclass correlations in nine cases was 0.99.

Frontal lobe subregions

Measurement of the frontal lobe subregions was completed using methods described previously (Szeszko *et al*, 1999), which were adapted from Rademacher *et al* (1992) for use in our magnetic resonance images. This method has been used in our previous work (Szeszko *et al*, 2000, 2004) and utilises the cerebral sulci in combination with a set of coronal planes that close the selected regions of interest. The boundaries of the superior frontal gyrus were the tip of the cingulate sulcus (anterior), the connection of the superior and precentral sulci (posterior), the superior frontal sulcus (lateral) and the cingulate sulcus (medial). The boundaries of the anterior cingulate

gyrus were the tip of the cingulate sulcus (anterior), the connection of the superior and precentral sulci (posterior), the callosal sulcus (ventral) and the cingulate sulcus (dorsal). The boundaries of the orbital frontal region were the last appearance of the anterior horizontal ramus (anterior), the last appearance of the olfactory sulcus (posterior), the anterior horizontal ramus/circular sulcus of insula (lateral) and the olfactory sulcus (medial) (Fig. 1). Because one of the limiting sulci required for measurement of the orbital frontal region (the anterior horizontal ramus) was not present in every hemisphere (Ono *et al*, 1990; Szeszko *et al*, 1999), orbital frontal volumes could not be computed for some individuals (see Table 2).

All regions were outlined manually in the coronal plane on a slice-by-slice basis and included both grey and white matter (Fig. 2). After outlining the frontal region of interest, the operator automatically segmented it into grey and white matter using a thresholding method generated from histograms (Otsu, 1979), as described previously (Lim *et al*, 1992; Szeszko *et al*, 2004). Intraclass correlations between two or three operators for these brain structures

(number of cases 8–10) were as follows: anterior cingulate gyrus grey matter, right hemisphere, ICC=0.90, left hemisphere, ICC=0.94; anterior cingulate gyrus white matter, right, ICC=0.94, left, ICC=0.94; superior frontal gyrus grey matter, right, ICC=0.92, left, ICC=0.97; superior frontal gyrus white matter, right, ICC=0.95, left, ICC=0.95; orbital frontal lobe grey matter, right, ICC=0.92, left, ICC=0.99; orbital frontal lobe white matter, right, ICC=0.94, 0.94, left, ICC=0.90.

Statistical procedures

The mixed-models approach (SAS version 8.2 for Windows) for repeated-measures analysis of variance was used to compare brain structure volumes between patients and healthy volunteers. Analyses were conducted separately for the anterior cingulate, superior frontal gyrus and orbital frontal lobe because of their neuroanatomical heterogeneity. For each of the three frontal regions the statistical model included group (healthy volunteers *v.* patients with cannabis use *v.* patients without cannabis use) and gender as between-subject factors. Tissue type (grey *v.* white) and hemisphere

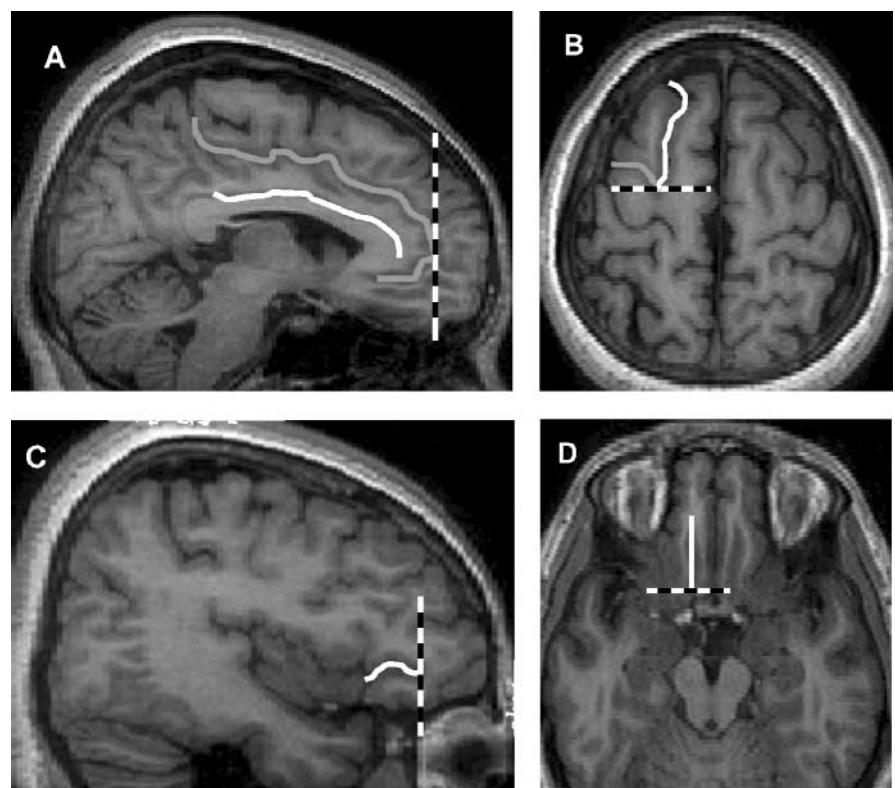


Fig. 1 Sulcal anatomy and coronal planes used for measurement of the frontal subregions. A, cingulate sulcus (grey), callosal sulcus (white) and tip of the cingulate sulcus (black, dashed); B, superior frontal sulcus (white), precentral sulcus (grey) and the connection between the two (black, dashed); C, anterior horizontal ramus (white) and its anterior tip (black, dashed); D, olfactory sulcus (white) and its posterior tip (black, dashed).

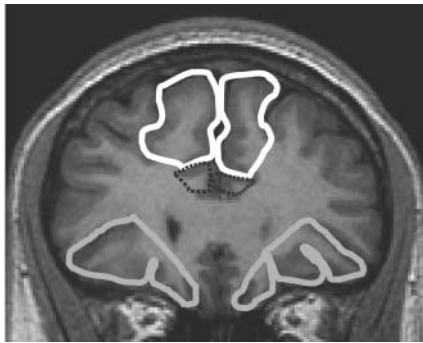


Fig. 2 Frontal lobe subregions (superior frontal gyrus, white; anterior cingulate gyrus, black, dashed; orbital frontal lobe, grey). Outlined regions were automatically segmented into grey and white matter using a thresholding method generated from grey-level histograms (see text and Otsu, 1979 for details).

were repeated measures. Age was included as a covariate because the groups differed in age and because age correlated with the brain structure volumes. Intracranial volume was included as a covariate to control for non-specific differences in brain size among individuals. Subsequent analyses excluded any patient with a substance use diagnosis other than cannabis abuse or dependence. Group differences in demographic variables were examined using independent group *t*-tests. Chi-square tests were used to examine differences in categorical variables. Analyses of frontal brain structure volumes were conducted using two-tailed tests with $\alpha=0.017$ (0.05 divided by number of brain regions). Results of analyses for individual brain structure volumes are presented for descriptive purposes only (see Table 2).

RESULTS

Sample characteristics for the two patient groups and the healthy comparison group are given in Table 1. The three groups did not differ significantly from each other in distributions of age, gender, handedness or the absence of the right or left anterior horizontal ramus ($P>0.05$). Also, as expected, the groups differed in education ($F=6.64$, $d.f.=2,97$, $P=0.002$), with healthy volunteers having more education than either patient group. Patients with cannabis use did not differ significantly from patients without cannabis use in distributions of age at first psychotic symptoms, years of education, duration of antipsychotic treatment, duration of untreated psychosis or global

Table 1 Sample characteristics

	Healthy comparison group ($n=56$)	Schizophrenia group	
		No cannabis use ($n=31$)	Cannabis use ($n=20$)
Gender, n			
Male	36	25	17
Female	20	6	3
Age, years: mean (s.d.)	25.7 (6.7)	24.8 (4.9)	22.4 (3.6)
Handedness, n^1			
Dextral	42	23	15
Non-dextral	12	8	5
Education, years: mean (s.d.) ²	14.6 (2.6)	13.2 (1.8)	12.6 (1.9)
Age at first psychotic symptoms, years: mean (s.d.)	–	21.4 (4.6)	20.3 (4.2)
Antipsychotic treatment, weeks: mean (range)	–	3.1 (0–26.7)	5.2 (0–34.4)
Antipsychotic drug-naïve, n	–	19	6
Duration of untreated psychosis, weeks: mean (range)	–	169 (1–828)	87 (4–380)
Global Assessment of Functioning score: mean (s.d.)	–	33.1 (13.4)	31.0 (16.6)

1. Missing data from healthy group ($n=2$).
2. Missing data from healthy group ($n=7$).

assessment of functioning (all $P>0.05$; Table 1). There were, however, significantly more patients who were antipsychotic drug-naïve among the cannabis user group compared with the non-cannabis user group ($\chi^2=4.76$, $d.f.=1$, $P=0.029$).

Mean brain structure volumes for the three study groups are given in Table 2, along with the adjusted 95% confidence intervals for the difference between group means. The main finding that distinguished the groups was a significant group-by-tissue type interaction for the anterior cingulate ($F_{2,108}=6.39$, $P=0.002$). Follow-up tests revealed that patients who used cannabis had significantly less anterior cingulate grey matter compared with patients who did not ($t_{1,108}=-2.41$, $P=0.018$) and with healthy volunteers ($t_{1,108}=-2.19$, $P=0.031$). Repeating the analysis with antipsychotic drug-naïve status as a covariate revealed that patients who used cannabis had significantly less anterior cingulate grey matter compared with patients who did not ($t_{1,48}=-2.40$, $P=0.020$). Individual data points illustrating total anterior cingulate grey-matter volumes for the three groups are provided in Fig. 3. None of the interactions involving gender was statistically significant for the anterior cingulate. Neither the main effect of group nor group-by-tissue type interaction was statistically significant for the orbital frontal lobe (all $P>0.05$). In addition, the main

effect of group was not statistically significant for the superior frontal gyrus.

There also was a significant main effect of hemisphere for the anterior cingulate ($F_{1,110}=19.3$, $P<0.001$) and orbital frontal lobe ($F_{1,94}=16.1$, $P<0.001$). Overall, participants had more grey matter ($t_{1,110}=-4.78$, $P<0.001$) and white matter ($t_{1,110}=-3.33$, $P=0.001$) in the right anterior cingulate compared with the left anterior cingulate. In addition, participants had more grey matter ($t_{1,94}=3.80$, $P<0.001$) and white matter ($t_{1,94}=4.07$, $P<0.001$) in the left compared with the right orbital frontal lobe. No significant hemispheric asymmetry was evident in the sample for either superior frontal gyrus grey-matter or white-matter volumes ($P>0.05$).

Subsequent analyses investigated whether having other substance use diagnoses influenced the observed findings. The group-by-tissue type interaction remained statistically significant ($F_{2,100}=6.07$, $P=0.003$) for the anterior cingulate when we excluded patients from analysis who had any substance use diagnosis other than cannabis abuse or dependence. Specifically, patients with either cannabis abuse or dependence as their sole substance use diagnosis had significantly less anterior cingulate grey matter than patients without any substance use diagnosis ($t_{1,100}=-2.45$, $P<0.016$) and healthy volunteers ($t_{1,100}=-2.34$, $P=0.021$).

Table 2 Unadjusted frontal lobe volumes and adjusted confidence intervals for group differences

	Healthy control group (n=56)		Schizophrenia group		Adjusted confidence intervals of difference between groups ¹				
	Mean (s.d.)	No cannabis use (n=31) Mean (s.d.)	Cannabis use (n=20) Mean (s.d.)	Control – FESZ without cannabis use	Control – FESZ with cannabis use	FESZ without cannabis use – FESZ with cannabis use	ES	95% CI	
		95% CI	ES	95% CI	ES	95% CI			
Superior frontal gyrus									
Grey matter total	33.3 (5.51)	32.9 (6.26)	32.7 (5.10)	-1.35 to 3.06	0.007	-0.25 to 4.35	0.042	-2.19 to 3.41	0.004
White matter total	25.4 (4.81)	25.4 (5.52)	25.7 (3.90)	-1.65 to 1.96	0.000	-2.66 to 1.49	0.004	-3.10 to 1.27	0.015
Right hemisphere									
Grey matter	16.8 (2.89)	16.0 (3.22)	16.5 (2.95)	-0.18 to 2.21	0.033	-0.39 to 2.21	0.027	-1.98 to 1.23	0.005
White matter	12.8 (2.42)	12.4 (2.81)	13.0 (2.34)	-0.46 to 1.39	0.012	-1.50 to 0.73	0.007	-2.16 to 0.31	0.046
Left Hemisphere									
Grey matter	16.7 (2.61)	17.0 (3.51)	16.2 (2.82)	-1.16 to 1.10	0.000	0.03 to 2.36	0.055*	-0.62 to 2.59	0.031
White matter	12.7 (2.36)	12.9 (3.01)	12.7 (2.13)	-1.07 to 0.77	0.001	-1.13 to 0.87	0.001	-1.25 to 1.28	0.000
Anterior cingulate gyrus									
Grey matter total	8.28 (1.55)	8.46 (1.54)	7.35 (1.46)	-0.75 to 0.53	0.001	0.31 to 1.80	0.100**	0.26 to 1.91	0.130*
White matter total	4.38 (0.94)	4.34 (0.88)	4.05 (0.96)	-0.29 to 0.38	0.001	-0.20 to 0.64	0.015	-0.26 to 0.69	0.018
Right hemisphere									
Grey matter	4.39 (1.01)	4.50 (1.09)	4.11 (1.19)	-0.50 to 0.36	0.001	-0.17 to 0.89	0.025	-0.22 to 0.98	0.034
White matter	2.28 (0.58)	2.28 (0.63)	2.24 (0.76)	-0.23 to 0.24	0.000	-0.32 to 0.28	0.000	-0.37 to 0.35	0.000
Left hemisphere									
Grey matter	3.89 (1.00)	3.96 (1.02)	3.24 (0.89)	-0.49 to 0.40	0.000	0.19 to 1.20	0.093**	0.11 to 1.30	0.109*
White matter	2.10 (0.60)	2.06 (0.55)	1.81 (0.42)	-0.20 to 0.29	0.002	-0.04 to 0.51	0.039	-0.07 to 0.52	0.048
Orbital frontal									
Grey matter total	10.1 (2.22)	10.8 (2.35)	10.5 (2.64)	-1.56 to 0.35	0.022	-1.02 to 1.23	0.001	-0.65 to 2.15	0.029
White matter total	6.37 (1.53)	6.87 (1.57)	6.79 (2.00)	-0.96 to 0.20	0.023	-1.08 to 0.46	0.011	-0.77 to 1.11	0.004
Right hemisphere²									
Grey matter	4.84 (1.19)	5.11 (1.39)	5.03 (1.52)	-0.75 to 0.34	0.007	-0.44 to 0.79	0.005	-0.34 to 1.33	0.034
White matter	3.03 (0.84)	3.24 (0.90)	3.17 (1.11)	-0.50 to 0.21	0.009	-0.45 to 0.43	0.000	-0.29 to 0.80	0.021
Left hemisphere³									
Grey matter	5.28 (1.41)	5.70 (1.25)	5.36 (1.48)	-0.88 to 0.29	0.014	-0.60 to 0.80	0.001	-0.34 to 1.05	0.024
White matter	3.36 (0.99)	3.60 (0.87)	3.51 (1.08)	-0.56 to 0.18	0.013	-0.67 to 0.28	0.010	-0.49 to 0.47	0.000

ES, effect size; FESZ, first-episode schizophrenia.

1. Volumes adjusted for age and total intracranial contents.

2. Owing to the absence of the anterior horizontal ramus volumes could not be computed for 5 healthy volunteers, 4 patients without cannabis use and 2 patients with cannabis use.

3. Owing to the absence of the anterior horizontal ramus volumes could not be computed for 6 healthy volunteers, 2 patients with schizophrenia without cannabis use and 1 patient with schizophrenia with cannabis use. *p < 0.05; **p < 0.01.

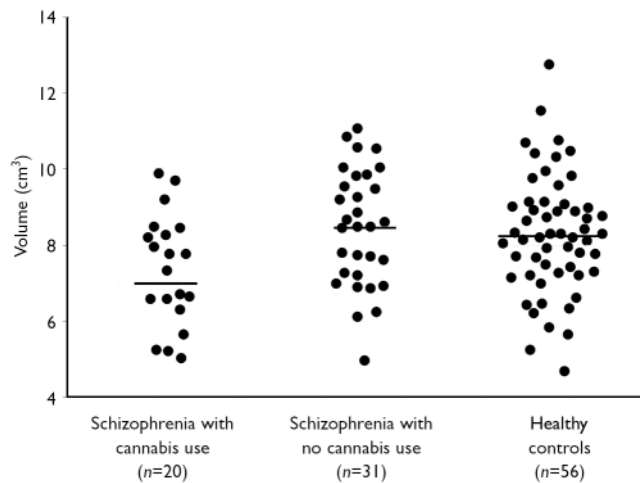


Fig. 3 Scatterplot of total anterior cingulate gyrus grey-matter volumes (horizontal lines represent mean values).

DISCUSSION

Understanding the relationship between prefrontal grey matter and cannabis use in schizophrenia may have important implications for improving our understanding of the potentially deleterious effects of these substances on brain structure in this disorder. Using methods for cortical parcellation of the prefrontal cortex based on the sulcal anatomy, we report that patients experiencing a first episode of schizophrenia who have a history of cannabis use have less anterior cingulate grey matter compared with similar patients who do not use cannabis and with healthy volunteers. We obtained similar findings when we excluded patients with substance use diagnoses other than cannabis abuse or dependence from analysis.

Other studies

Little research has been directed at understanding the relationship between cannabis use and brain structure, especially in schizophrenia, and thus it is difficult to compare our findings with prior work. In a structural neuroimaging study Cahn *et al* (2004) did not identify differences in total grey- and white-matter volumes between patients with recent-onset schizophrenia comorbid with cannabis abuse or dependence and patients with no cannabis use, but did not examine discrete frontal cortical regions. Several studies reported grey-matter structural alterations in cannabis users, however, and this may have relevance for the findings reported here. For example, Matochik *et al* (2005) reported

that individuals who used cannabis had lower grey-matter density in the right parahippocampal gyrus and greater density bilaterally near the precentral gyrus and right thalamus compared with those who did not. In addition, Wilson *et al* (2000) reported lower whole-brain grey-matter volume among individuals who started using cannabis before age 17 years compared with individuals who started using cannabis later. Moreover, the use of other illicit substances such as cocaine has been linked to anterior cingulate grey-matter structural alterations (Franklin *et al*, 2002; Matochik *et al*, 2003).

The anterior cingulate is believed to play an important part in mediating executive functions, including set-shifting and response inhibition, which have been reported to be abnormal among individuals who use cannabis (Gruber & Yurgelun-Todd, 2005). Several studies reported aberrant anterior cingulate activity among cannabis users while performing the Stroop task, which requires the ability to inhibit prepotent tendencies to respond (Eldreth *et al*, 2004; Gruber & Yurgelun-Todd, 2005). It is also noteworthy that abnormal anterior cingulate activity was also reported in cannabis users while performing a motor sequencing task (Pillay *et al*, 2004) and in individuals exposed to marijuana prenatally (Smith *et al*, 2004). People who are substance users also find it difficult to inhibit their own actions as working memory demands increase (Hester & Garavan, 2004), and individuals who use cannabis may need the anterior cingulate to 'work harder' to complete task demands (Kanayama *et al*, 2004). Drug

craving has also been linked with anterior cingulate activity (Kilts *et al*, 2001) and more specifically with attentional biases for cannabis-related stimuli (Field *et al*, 2004).

Implications

Risky decision-making is considered integral to the phenomenology of drug use (Fishbein *et al*, 2005) and such decisions are intimately linked with reward and punishment, which is mediated by neural systems involving the anterior cingulate (Shidara & Richmond, 2002). Patients with schizophrenia who use cannabis may have deficits in the ability to balance rewards and punishments, which could contribute to drug-taking behaviour. Specifically, people who use cannabis tend to make decisions based on large immediate gains in spite of more costly losses (Whitlow *et al*, 2004). Among drug users, risky choices during a decision-making test were associated with abnormal metabolic activity in the anterior cingulate (Tucker *et al*, 2004), which may partly form the neuroanatomical substrate of choosing risky outcomes. Our results are compatible with the hypothesis that grey-matter structural alterations involving the anterior cingulate in patients with schizophrenia using cannabis could be associated with poor decision-making and partly mediate the compulsive drive towards drug use (Adinoff, 2004).

We did not observe significant differences between the group with first-episode schizophrenia with no history of cannabis use and the healthy volunteer group in any of the prefrontal grey-matter or white-matter volumes. One potentially important consideration in the assessment of brain structure in schizophrenia, however, is illness duration, especially given some evidence that grey-matter deficits in schizophrenia are progressive (Mathalon *et al*, 2001; Cahn *et al*, 2002; Pantelis *et al*, 2003) and that such deficits occur only after the first few years following illness onset (Molina *et al*, 2004). It is therefore conceivable that prefrontal grey-matter structural alterations might become apparent later in the course of schizophrenia, at least in our cohort of patients without cannabis use. In addition, it would be helpful to elucidate the potential effects of cannabis on the anterior cingulate in longitudinal studies, especially given that this region has been implicated in the transition to psychosis (Pantelis *et al*, 2003).

Limitations

There were several limitations to our study that should be acknowledged. One potential limitation is the extensive amount of time required to outline the frontal lobe regions of interest. An alternative approach might be the use of voxel-based morphometry, although this method requires brain normalisation and smoothing, which could result in the loss of information if abnormalities are subtle and localised to small regions. Also, there are inherent challenges in using sulcal anatomical features as the boundaries of regions of interest, given their heterogeneous presentation; however, we believe that this approach provides greater cytoarchitectonic validity compared with methods based on invariant landmarks not appearing on the cortical surface. In addition, qualitative methods for mapping cingulate and paracingulate morphology (Yucel *et al*, 2002) may be useful in complementing the volumetric approach described here. Another potential limitation is the lack of a study group who used cannabis but did not have schizophrenia, to test whether our findings were more generally associated with cannabis use. Moreover, given the cross-sectional nature of this study, we could not determine whether anterior cingulate grey-matter volume deficits predispose patients to use cannabis or whether these deficits are a consequence of cannabis use.

ACKNOWLEDGEMENTS

This work was supported in part by grants from NARSAD (P.R.S.) and the National Institute of Mental Health to P.R.S. (MH01990), R.M.B. (MH60374), S.S. (DA015541), J.M.K. (MH60575), D.G.R. (MH60004) and the North Shore–Long Island Jewish Research Institute General Clinical Research Center (MO1 RR018535).

REFERENCES

- American Psychiatric Association (1994)** *Diagnostic and Statistical Manual of Mental Disorders* (4th edn) (DSM–IV). APA.
- Adinoff, B. (2004)** Neurobiologic processes in drug reward and addiction. *Harvard Review of Psychiatry*, **12**, 305–320.
- Bersani, G., Orlandi, V., Kotzalidis, G. D., et al (2002)** Cannabis and schizophrenia: impact on onset, course, psychopathology and outcomes. *European Archives of Psychiatry and Clinical Neurosciences*, **252**, 86–92.
- Cahn, W., Hulshoff Pol, H. E., Bongers, M., et al (2002)** Brain morphology in antipsychotic-naïve schizophrenia: a study of multiple brain structures. *British Journal of Psychiatry*, **181** (suppl. 43), s66–s72.
- Cahn, W., Hulshoff Pol, H. E., Caspers, E., et al (2004)** Cannabis and brain morphology in recent-onset schizophrenia. *Schizophrenia Research*, **67**, 305–307.
- Eldreth, D. A., Matochik, J. A., Cadet, J. L., et al (2004)** Abnormal brain activity in prefrontal brain regions in abstinent marijuana users. *NeuroImage*, **23**, 914–920.
- Field, M., Mogg, K. & Bradley, B. P. (2004)** Cognitive bias and drug craving in recreational cannabis users. *Drug and Alcohol Dependence*, **74**, 105–111.
- First, M. B., Spitzer, R. L., Gibbon, M., et al (1994)** *Structured Clinical Interview for Axis I DSM–IV Disorders–Patient Edition (SCID–I/P)*, Biometrics Research Department, New York State Psychiatric Institute.
- Fishbein, D. H., Eldreth, D. L., Hyde, C., et al (2005)** Risky decision making and the anterior cingulate cortex in abstinent drug abusers and nonusers. *Brain Research. Cognitive Brain Research*, **23**, 119–136.
- Franklin, T. R., Acton, P. D., Maldjian, J. A., et al (2002)** Decreased gray matter concentration in the insular, orbitofrontal, cingulate, and temporal cortices of cocaine patients. *Biological Psychiatry*, **51**, 134–142.
- Goldman-Rakic, P. S. & Selemon, L. D. (1997)** Functional and anatomical aspects of prefrontal pathology in schizophrenia. *Schizophrenia Bulletin*, **23**, 437–458.
- Goldstein, J. M., Goodman, J. M., Seidman, L. J., et al (1999)** Cortical abnormalities in schizophrenia identified by structural magnetic resonance imaging. *Archives of General Psychiatry*, **56**, 537–547.
- Goldstein, R. Z. & Volkow, N. D. (2002)** Drug addiction and its underlying neurobiological basis: neuroimaging evidence for the involvement of the frontal cortex. *American Journal of Psychiatry*, **159**, 1642–1652.
- Green, B., Kavanagh, D. J. & Young, R. M. (2004)** Reasons for cannabis use in men with and without psychosis. *Drug and Alcohol Review*, **23**, 445–453.
- Gruber, S. A. & Yurgelun-Todd, D. A. (2005)** Neuroimaging of marijuana smokers during inhibitory processing: a pilot investigation. *Brain Research. Cognitive Brain Research*, **23**, 107–118.
- Gur, R. E., Cowell, P. E., Latshaw, A., et al (2000)** Reduced dorsal and orbital prefrontal gray matter volumes in schizophrenia. *Archives of General Psychiatry*, **57**, 761–768.
- Henquet, C., Murray, R., Linszen, D., et al (2005)** The environment and schizophrenia: the role of cannabis use. *Schizophrenia Bulletin*, **31**, 608–612.
- Hester, R. & Garavan, H. (2004)** Executive dysfunction in cocaine addiction: evidence for discordant frontal, cingulate, and cerebellar activity. *Journal of Neuroscience*, **24**, 11017–11022.
- Kanayama, G., Rogowska, J., Pope, H. G., et al (2004)** Spatial working memory in heavy cannabis users: a functional magnetic resonance imaging study. *Psychopharmacology (Berlin)*, **176**, 239–247.
- Kilts, C. D., Schweitzer, J. B., Quinn, C. K., et al (2001)** Neural activity related to drug craving in cocaine addiction. *Archives of General Psychiatry*, **58**, 334–341.
- Lim, K. O., Zipursky, R. B., Watts, M. C., et al (1992)** Decreased gray matter in normal aging: an in vivo magnetic resonance study. *Journal of Gerontology*, **47**, B26–30.
- Mathalon, D. H., Sullivan, E. V., Lim, K. O., et al (2001)** Progressive brain volume changes and the clinical course of schizophrenia in men: a longitudinal magnetic resonance imaging study. *Archives of General Psychiatry*, **58**, 148–157.
- Matochik, J. A., London, E. D., Eldreth, D. A., et al (2003)** Frontal cortical tissue composition in abstinent cocaine abusers: a magnetic resonance imaging study. *NeuroImage*, **19**, 1095–1102.
- Matochik, J. A., Eldreth, D. A., Cadet, J. L., et al (2005)** Altered brain tissue composition in heavy marijuana users. *Drug and Alcohol Dependence*, **77**, 23–30.
- Molina, V., Sanz, J., Sarramea, F., et al (2004)** Lower prefrontal gray matter volume in schizophrenia in chronic but not in first episode schizophrenia patients. *Psychiatry Research*, **131**, 45–56.
- Oldfield, R. C. (1971)** The assessment and analysis of handedness: the Edinburgh Inventory. *Neuropsychologia*, **9**, 97–114.
- Ono, M., Kubik, S. & Abernathy, C. D. (1990)** *Atlas of the Cerebral Sulci*. Thieme.
- Otsu, N. A. (1979)** Thresholding selection method from gray-level histogram. *IEEE Transactions on Systems, Man, and Cybernetics*, **9**, 62–66.
- Pantelis, C., Velakoulis, D., McGorry, P. D., et al (2003)** Neuroanatomical abnormalities before and after

Correspondence: Dr Philip R. Szeszko, Zucker Hillside Hospital, Psychiatry Research, 75–59 263rd Street, Glen Oaks, NY 11004, USA. Tel: +1 718 470 8489; fax: +1 718 343 1659; email: szeszko@lij.edu

(First received 27 March 2006, final revision 17 July 2006, accepted 27 October 2006)

onset of psychosis: a cross-sectional and longitudinal MRI comparison. *Lancet*, **361**, 281–288.

Pillay, S. S., Rogowska, J., Kanayama, G., et al (2004) Neurophysiology of motor function following cannabis discontinuation in chronic cannabis smokers: an fMRI study. *Drug and Alcohol Dependence*, **76**, 261–271.

Rademacher, J., Galaburda, A. M., Kennedy, D. N., et al (1992) Human cerebral cortex: localization, parcellation, and morphometry with magnetic resonance imaging. *Journal of Cognitive Neuroscience*, **4**, 352–374.

Schachter, S. C., Ransil, B. J. & Geschwind, N. (1987) Associations of handedness with hair color and learning disabilities. *Neuropsychologia*, **25**, 269–276.

Shidara, M. & Richmond, B. J. (2002) Anterior cingulate: single neuronal signals related to degree of reward expectancy. *Science*, **296**, 1709–1711.

Smith, A. M., Fried, P. A. & Hogan, M. J., et al (2004) Effects of prenatal marijuana on response inhibition: an fMRI study of young adults. *Neurotoxicology and Teratology*, **26**, 533–542.

Spitzer, R. L. & Williams, D. (1988) *Structured Clinical Interview for Diagnoses—Nonpatient Version*. New York: State Psychiatric Institute.

Szeszko, P. R., Bilder, R. M., Lencz, T., et al (1999) Investigation of frontal lobe subregions in first-episode schizophrenia. *Psychiatry Research: Neuroimaging*, **90**, 1–15.

Szeszko, P. R., Bilder, R. M., Lencz, T., et al (2000) Reduced anterior cingulate gyrus volume correlates with executive dysfunction in men with first-episode schizophrenia. *Schizophrenia Research*, **43**, 97–108.

Szeszko, P. R., MacMillan, S., McMeniman, M., et al (2004) Brain structural abnormalities in psychotropic drug-naïve pediatric patients with obsessive-compulsive disorder. *American Journal of Psychiatry*, **161**, 1049–1056.

Tucker, K. A., Potenza, M. N., Beauvais, J. E., et al (2004) Perfusion abnormalities and decision making in cocaine dependence. *Biological Psychiatry*, **56**, 527–530.

Van Mastrigt, S., Addington, J. & Addington, D. (2004) Substance misuse at presentation to an early

psychosis program. *Social Psychiatry and Psychiatric Epidemiology*, **39**, 69–72.

Verrico, C. D., Jentsch, J. D., Roth, R. H. (2003) Persistent and anatomically selective reduction in prefrontal cortical dopamine metabolism after repeated, intermittent cannabinoid administration to rats. *Synapse*, **49**, 61–66.

Whitlow, C. T., Liguori, A., Livengood, L. B., et al (2004) Long-term heavy marijuana users make costly decisions on a gambling task. *Drug and Alcohol Dependence*, **76**, 107–111.

Wilson, W., Mathew, R., Turkington, T., et al (2000) Brain morphological changes and early marijuana use: a magnetic resonance and positron emission tomography study. *Journal of Addictive Disorders*, **19**, 1–22.

Yucel, M., Pantelis, C., Stuart, G. W., et al (2002) Anterior cingulate activation during Stroop task performance: a PET to MRI coregistration study of individual patients with schizophrenia. *American Journal of Psychiatry*, **159**, 251–254.