

through the compressed or narrowed portion of the trachea [2]. For this reason, fiberoptic endotracheal intubation is advisable.

Ljunghall and colleagues showed that patients with HPT who were apparently asymptomatic preoperatively did not have defects of their neuromuscular transmission that were of clinical significance [5]. In asymptomatic pHPT neither consistent abnormality of neuromuscular transmission nor abnormal muscle structure was found [6]. On the contrary, Al Mohaya and colleagues reported a decreased response to both succinylcholine and atracurium in a patient with parathyroid adenoma [3].

In patients there was a decreased duration of action of *cis*-atracurium. There was recovery of T1 to 25% of control at 26.9 min and repeated doses of *cis*-atracurium (0.03 mg kg<sup>-1</sup>) administered to maintain relaxation during surgery provided a clinical duration 10.2 ± 0.8 min. Wuffel and colleagues reported that recovery index 25–75% and time to a TOF ratio of 0.70 of *cis*-atracurium were prolonged significantly by sevoflurane compared with total intravenous anaesthesia [7]. However, in our patient, increased minimum alveolar concentration (MAC) of sevoflurane did not result in significant effects on duration of or recovery from the block. On the contrary, recovery was considerably shorter in our patient. Intraoperative electrolytes and acid–base balance status were normal and normothermia was maintained.

In conclusion, special attention should be paid to neuromuscular function monitoring in patients with pHPT.

A. Papadima, E. E. Lagoudianakis,  
H. Markogiannakis, A. Pappas, A. Manouras  
First Department of Propaedeutic Surgery  
Hippocrateion Hospital  
Athens Medical School  
Athens, Greece

L. Georgiou  
Department of Anaesthesiology  
Hippocrateion Hospital  
Athens, Greece

## References

1. Aguilera IM, Vaughan RS. Calcium and the anaesthetist. *Anaesthesia* 2000; 55: 779–790.
2. Voyagis GS, Kyriakos KP. The effect of goiter on endotracheal intubation. *Anesth Analg* 1997; 84: 611–612.
3. Al-Mohaya S, Naguib M, Abdelatif M, Farag H. Abnormal responses to muscle relaxants in a patient with primary hyperparathyroidism. *Anesthesiology* 1986; 65: 554–556.
4. Bentrem DJ, Angelos P, Talamonti MS, Nayar R. Is preoperative investigation of the thyroid justified in patients undergoing parathyroidectomy for hyperparathyroidism? *Thyroid* 2002; 12: 1109–1112.
5. Ljunghall S, Akerstrom G, Johansson G, Olsson Y, Stalberg E. Neuromuscular involvement in primary hyperparathyroidism. *J Neurol* 1984; 231: 263–265.
6. Jansson S, Grimby G, Hagne I, Hedman I, Tisell LE. Muscle structure and function before and after surgery for primary hyperparathyroidism. *Eur J Surg* 1991; 157: 13–16.
7. Wuffel H, Kahl M, Ledowski T. Augmentation of the neuromuscular blocking effects of cisatracurium during desflurane, sevoflurane, isoflurane or total i.v. anaesthesia. *Br J Anaesth* 1998; 80: 308–312.

## Changes in the cerebral state index (CSI) during intraoperative cardiac arrest

doi:10.1017/S0265021508004341

### EDITOR:

The Cerebral State Monitor (CSM, Danmeter A/S, Odense, Denmark) is a portable electroencephalogram (EEG)-based device used to evaluate anaesthetic depth. It shows a non-dimensional scale between 0 and 100 that corresponds to the cerebral state index (CSI).

Correspondence to: Enrique Cárdenas, Servicio de Anestesiología y Clínica del Dolor, USP Hospital San Jaime, Partida de la Loma s/n, 03180 Torrevieja (Alicante), Spain. E-mail: alenma17@yahoo.es; Tel: +34 680 82 0723; Fax: +34 966 92 2706

Accepted for publication 14 March 2008 EJA 4942  
First published online 9 May 2008

A CSI value between 40 and 60 is considered to be optimal for surgical anaesthesia. As the CSI value approaches zero, the burst suppression ratio (BS%), which indicates the amount of isoelectric EEG, increases, suggesting cerebral hypoperfusion [1]. There are references in the literature suggesting the usefulness of similar systems, particularly the bispectral index (BIS) and patient state index (PSI), in states of intraoperative cerebral hypoperfusion [2,3]. In this report we describe the use of CSM to assess the effectiveness of cardiopulmonary resuscitation (CPR) during a complex oncological procedure.

## Case report

A 62-yr-old male patient with a history of professional exposure to asbestos and a diagnosis of right pleural mesothelioma was scheduled for pleurectomy, decortication and intrathoracic hyperthermic chemotherapy. The patient had also a previous talc pleurodesis because of recurrent pleural effusions. The performance status was 1 (WHO scale), although preoperative spirometry showed a moderate to severe restrictive pattern. The electrocardiogram and cardiac ultrasonography were normal.

The patient was premedicated with midazolam and an epidural thoracic catheter was placed (T8-T9) with no incidences. Anaesthesia was induced with propofol, fentanyl and *cis*-atracurium, and intubation was completed with a left 37F Bronco-Cath<sup>®</sup> double-lumen tube (Mallinckrodt Medical, St Louis, MO, USA). The sevoflurane dose used for anaesthetic maintenance was titrated using the CSI, expired fraction and haemodynamic parameters. Intraoperative analgesia was maintained with ropivacaine administered both in fractionated bolus doses and through continuous infusion through the epidural catheter. Right lung collapse was uneventful and the patient maintained an adequate oxygenation during the operation.

The surgical procedure was lengthy and difficult and a complete pleurectomy and partial pericardiectomy were performed. During the mediastinal manipulations the patient needed increasing doses of dopamine in order to maintain a mean blood pressure value of 50–60 mmHg. While a pericardial repair with Gore-Tex<sup>®</sup> patch (W. L. Gore & Associates, Inc., Flagstaff, AZ, USA) was performed, a sudden episode of ventricular tachycardia ensued. It was accompanied by severe haemodynamic breakdown and abrupt decrease of end tidal CO<sub>2</sub>. Direct cardiac defibrillation at low energy levels proved ineffective and the surgeon decided to apply a cardiac massage *in situ*. The pulseless ventricular tachyarrhythmia

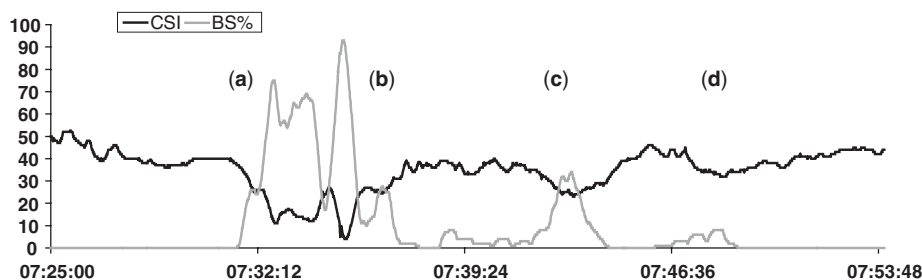
developed into an asystole and cardiac massage had to be maintained while atropine and inotropic drugs were simultaneously administered.

After approximately 20 min of advanced cardiac life support, the patient recovered normal sinus rhythm, allowing the completion of surgery. A total dose of 4 mg epinephrine and 3 mg atropine was given during resuscitation. The medical team decided to avoid intrathoracic hyperthermic chemotherapy since this procedure may have worsened the haemodynamic status.

The CSM was used during surgery in order to measure the depth of anaesthesia. Before induction, three sensors were placed according to the manufacturer's indications in mid-forehead (+), left forehead (reference) and left mastoid (-). After confirming that a good electrode impedance value was achieved, monitoring started and the CSI level decreased through loss of consciousness. The CSI remained between 40 and 50 during most of the surgical procedure until cardiac arrest.

Figure 1 shows a decrease in the CSI and a simultaneous increase in the burst suppression ratio (BS%), coinciding with the occurrence of ventricular tachyarrhythmia and the associated haemodynamic deterioration. When the surgeon initiated direct cardiac compression, an increase in the CSI was observed, achieving similar values to those observed before cardio-circulatory collapse. In a second phase, the surgeon suspended the massage in order to check the effectiveness of pharmacologic measures, and a new decrease of the CSI and an increase in the BS ratio are observed. The heart recovered an effective cardiac rate and the CSI again returned to pre-cardiac arrest values.

All electroencephalographic data were recorded using the CSM capture software provided by the manufacturer. Unfortunately, the haemodynamic monitor did not allow data recording and blood pressure values corresponding to CSI variations could not be recorded.



**Figure 1.**

Cerebral state index (CSI) during cardiac arrest. Note the parallel increase in burst suppression (BS) ratio (grey line) along with decreasing CSI values (black line) due to cerebral hypoperfusion. (a) Cardiac arrest. (b) The surgeon starts direct cardiac compressions and CSI reaches maintenance values. (c) Surgeon stops the compressions but still asystolia. (d) The patient recovers an effective cardiac rhythm and CSI shows again maintenance values. The signal quality index (SQI) was above 90% during the whole period of time and it is not shown in the figure.

After surgery was completed, the patient was transferred under sedation, analgesia and controlled mechanical ventilation to the intensive care unit. He subsequently died 7 h after admission due to a second cardiac arrest, so it was impossible to evaluate possible neurological sequelae.

## Discussion

The monitoring of anaesthetic depth is potentially useful in order to optimize the administration of hypnotic drugs during anaesthesia and to prevent possible episodes of awareness, especially in some high-risk situations. The CSM allows the monitoring of anaesthetic depth through the CSI. This index is reported to be the result of the combination of four parameters calculated from the EEG. The first three parameters result from the spectral analysis of the electroencephalographic signal and the fourth is the burst suppression rate calculated by the monitor. A novel feature of the CSM is a fuzzy logic inference system used for calculating the CSI [1].

This case showed that cortical electrical activity was clearly affected during cardiac arrest due to cerebral hypoperfusion, producing a decrease in the CSI and a simultaneous electroencephalographic 'silence' reflected in the increasing burst suppression ratio.

It is of special interest that the CSI increased during direct cardiac massage and the CSI decreased, and the BS ratio increased again, when the surgeon momentarily suspended massage manoeuvres. CSI and BSR values were not associated with EMG activity and the signal quality index was higher than 90%.

Although there have been no other reports of similar clinical situations described with the CSM, Azim and Wang [2] describes a similar case using a BIS monitor (Aspect Medical Systems, Natick, MA, USA). Azim and Wang suggested that the increase in BIS during CPR indicated an acceptable cerebral perfusion, although no signs of peripheral perfusion were present. In that case, adequate neurological recovery was achieved; however, it was impossible for us to verify the neurological state after the cardiac arrest and this is probably the main drawback of our current report. Nevertheless, we consider that the findings are relevant, as once the patient recovers normal heart rate after intraoperative CPR manoeuvres, the CSI returned to the range of values observed before the critical episode.

Another disadvantage of the current report could be the unavailability to record haemodynamic parameters; due to the characteristics of the circulatory collapse and in the absence of intraoperative haemorrhage, we consider that those values were not relevant.

Other authors have described a similar case using the PSI (PSA 4000; Physiometrix Inc., North Billerica, MA, USA) during intraoperative cardiac arrest [3]. They described that PSI values were in single digits during the collapse; however, those values were not specifically analysed during CPR.

It has recently been suggested that BIS monitoring could have a prognostic implication after out-of-hospital cardiac arrest, Shibata and colleagues [4] concluded, in a small study, that the BIS values were significantly lower in the non-surviving group than in the surviving group. However, a practice parameter about prediction of outcome in post-CPR comatose survivors, published by the American Academy of Neurology, assigned a higher prognostic value to somatosensory evoked potentials than to EEG measurements [5].

In conclusion, the CSI could be useful in situations of cerebral hypoperfusion such as those derived from CPR in order to optimize recovery manoeuvres. The availability of this type of monitoring in high-risk surgeries could be of use, not only as an aid to adequate drug titration but also as an indirect means of assessing brain perfusion in critical situations.

E. Cárdenas, J. Cano, O. Tovar  
Servicio de Anestesiología y Clínica del Dolor  
USP Hospital San Jaime  
Torrevieja, Spain

J. Belda, R. Rami  
Servicio de Cirugía Torácica  
Hospital Mutua de Terrassa  
Barcelona, Spain

## References

1. Jensen EW, Litvan H, Revuelta M *et al.* Cerebral State Index during propofol anaesthesia. A comparison with bispectral index and the A-line ARX index. *Anesthesiology* 2006; 105: 28–36.
2. Azim N, Wang CY. The use of bispectral index during a cardiopulmonary arrest: a potential predictor of cerebral perfusion. *Anaesthesia* 2004; 59: 610–612.
3. Nguyen NK, Lenkovsky F, Joshi GP. Patient state index during cardiac arrest in the operating room. *Anesth Analg* 2005; 100: 155–157.
4. Shibata S, Imota T, Shigeomi S, Sato W, Enzan K. Use of bispectral index during early postresuscitative phase after out-of-hospital cardiac arrest. *J Anesth* 2005; 19: 243–246.
5. Wijdicks EFM, Hijdra A, Young GB, Bassetti CL, Wiebe S. Practice parameter: prediction of outcome in comatose survivors after cardiopulmonary resuscitation (an evidence based review). *Neurology* 2006; 67: 203–210.