

Neuroimaging Highlight

Idiopathic Extracranial Internal Carotid Artery Vasospasm

Aaron de Souza^{1,2}  and Stuart Walker³

¹Department of Neurology, Launceston General Hospital, Launceston, TAS, Australia, ²University of Tasmania Launceston Clinical School, Launceston, TAS, Australia and ³Department of Vascular Surgery, Royal Hobart Hospital, Hobart, TAS, Australia

Keywords: Internal carotid; stenosis; stroke; vasospasm

(Received 21 January 2024; date of acceptance 26 January 2024)

A 25-year-old male with no history of trauma or use of vasoactive substances presented with recurrent migrainous headaches associated with alternating right or left hemiparesis or hemianaesthesia. An MRI scan showed a chronic right cerebral watershed infarct with loss of the normal bright vascular signal in the distal extracranial and intracranial portions of the right internal carotid artery (ICA) on T1-weighted Magnetized Prepared Rapid Gradient Echo images interpreted as chronic ICA occlusion

(Fig. 1a). Duplex carotid ultrasound scan four weeks later reported patent ICAs bilaterally, with elevated peak systolic velocities and broadening of the spectral waveform with a “beaded” appearance to the distal right ICA, consistent with bilateral stenoses, right 50%–69%, left 70%–79% (Fig. 1b). Computed tomography angiography (CTA) a week later demonstrated a focal critical stenosis in the mid-cervical left ICA (Fig. 1c), with no contralateral abnormality. To investigate other potential sites of arterial

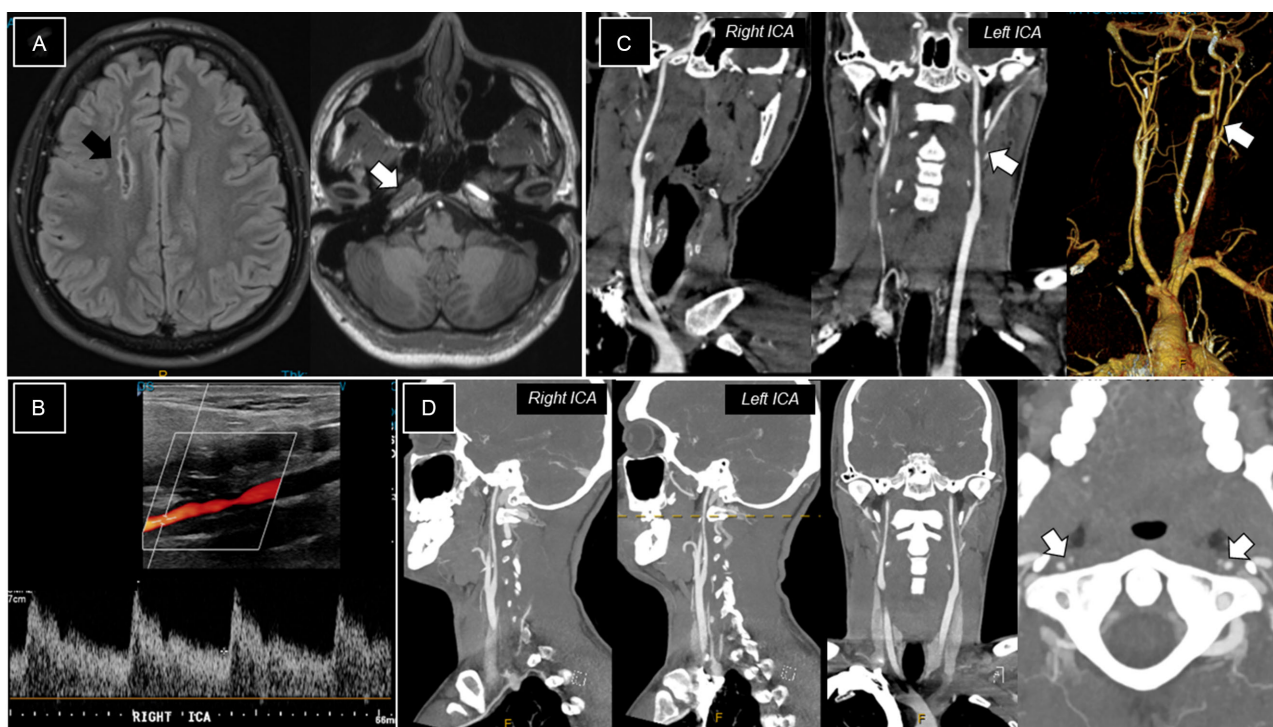


Figure 1: (a) MRI of the brain demonstrating a chronic right cerebral watershed infarct on fluid-attenuated inversion recovery images [black arrow] and loss of the normal bright vascular signal in the right ICA on T1-MPRAGE images [white arrow]. (b) Right carotid ultrasound four weeks later showed broadening of the spectral waveform and “beading” of the distal right ICA. (c) CTA after another week revealed a focal critical stenosis of the left ICA with a normal-appearing ICA on the right. (d) Resolution of left ICA stenosis on repeat CTA after six weeks, with diffuse narrowing of both ICAs.

Corresponding author: A. de Souza; Email: aaron.de.souza@ths.tas.gov.au

Cite this article: de Souza A and Walker S. Idiopathic Extracranial Internal Carotid Artery Vasospasm. *The Canadian Journal of Neurological Sciences*, <https://doi.org/10.1017/cjn.2024.20>

© The Author(s), 2024. Published by Cambridge University Press on behalf of Canadian Neurological Sciences Federation. This is an Open Access article, distributed under the terms of the Creative Commons Attribution licence (<http://creativecommons.org/licenses/by/4.0/>), which permits unrestricted re-use, distribution and reproduction, provided the original article is properly cited.

pathology, we performed CTA with aortography six weeks later. There was no evidence of fibromuscular dysplasia or other vasculitis. The stenosis of the left ICA had completely resolved with diffuse narrowing of both ICAs in their intracranial course (Fig. 1d).

Reversible idiopathic extracranial internal carotid vasospasm (IEICAV) is a rare cause of stroke in adolescents and young adults.^{1–6} Segmental filiform narrowing of one or the other cervical ICA spontaneously resolves in 24–72 hours.⁷ Due to the dynamic nature of the process, diagnosis often depends on serendipitously-timed imaging studies,^{1,6,7} and the demonstration of alternating and spontaneously-resolving ICA stenosis differentiates IEICAV from fibromuscular dysplasia, ICA dissection and atheromatous disease.⁴ Unlike reversible cerebral vasoconstriction syndrome which affects the intracranial ICA and its branches, patients with IEICAV have recurrent episodes of vasospasm over years and do not experience thunderclap headaches.^{1,3,6} Yokoyama *et al* reported worsening of focal neurological symptoms when standing, reflecting the role of flow limitation from vasospasm in the development of cerebral ischaemia.⁸

This condition is analogous to other vasospastic conditions including Raynaud's phenomenon and Prinzmetal's variant angina.³ Migraine, coronary events and smoking may be risk factors for IEICAV.^{4,5} Kaneko and colleagues postulated ICA sensitivity to head rotation,⁵ while Moeller *et al* suggested adrenergic overactivity affecting the cervical ICAs and demonstrated that metronomic deep breathing, presumably increasing parasympathetic outflow and the alpha-adrenergic antagonist prazosin alleviated vasospasm.¹ Stellate ganglion block produced only temporary amelioration of attack severity.⁸ Antithrombotics, gabapentin, corticosteroids, balloon angioplasty and stenting, intra-arterial vasodilators and calcium channel blockers have also been used with variable results, but no definitive treatment guidelines exist.^{3,6,7}

Author contribution. A.S.: data collection, writing the initial draft, revision, approval of the final manuscript.

S.W.: conceptualisation of the paper, data collection, review of the draft, critique, approval of the final manuscript.

Funding statement. No funding was received from any source.

Competing interests. The authors affirm that they have no conflicts of interest.

References

1. Moeller S, Hilz MJ, Blinzler C, et al. Extracranial internal carotid artery vasospasm due to sympathetic dysfunction. *Neurology*. 2012;78:1892–4. DOI: [10.1212/WNL.0b013e318258f7ab](https://doi.org/10.1212/WNL.0b013e318258f7ab).
2. Janzarik WG, Ringleb PA, Reinhard M, Rauer S. Recurrent extracranial carotid artery vasospasms: report of 2 cases. *Stroke*. 2006;37:2170–3. DOI: [10.1161/01.STR.0000231646.30541.d8](https://doi.org/10.1161/01.STR.0000231646.30541.d8).
3. Graham E, Orjuela K, Poisson S, Biller J. Treatment challenges in idiopathic extracranial ICA vasospasm: case report and review of the literature. *eNeurologicalSci*. 2021;22:100304. DOI: [10.1016/j.ensci.2020.100304](https://doi.org/10.1016/j.ensci.2020.100304).
4. Hirayama K, Hirayama T, Tahara J, et al. Cerebral infarct with idiopathic cervical internal carotid artery vasospasm: a case report and literature review. *Interdiscip Neurosurg*. 2018;14:161–3. DOI: [10.1016/j.inat.2018.08.008](https://doi.org/10.1016/j.inat.2018.08.008).
5. Kaneko M, Tateoka T, Kanemaru K, et al. Recurring cervical internal carotid artery vasospasm elicited by head rotation: illustrative case. *J Neurosurg Case Lessons*. 2022;4:CASE22254. DOI: [10.3171/CASE22254](https://doi.org/10.3171/CASE22254).
6. Wöpking S, Kastrup A, Lentschig M, Brunner F. Recurrent strokes due to transient vasospasms of the extracranial internal carotid artery. *Case Rep Neurol*. 2013;5:143–8. DOI: [10.1159/000354827](https://doi.org/10.1159/000354827).
7. Huisa BN, Roy G. Spontaneous cervical internal carotid artery vasospasm: case report and literature review. *Neurol Clin Pract*. 2014;4:461–4. DOI: [10.1212/CPJ.0000000000000067](https://doi.org/10.1212/CPJ.0000000000000067).
8. Yokoyama H, Yoneda M, Abe M, et al. Internal carotid artery vasospasm syndrome: demonstration by neuroimaging. *J Neurol Neurosurg Psychiatry*. 2006;77:888–9. DOI: [10.1136/jnnp.2005.079798](https://doi.org/10.1136/jnnp.2005.079798).