

# Primary Degenerative Dementia Without Alzheimer Pathology

Arthur W. Clark, Charles L. White III, Herbert J. Manz, Irma M. Parhad, Bernadette Curry, Peter J. Whitehouse, John Lehmann, and Joseph T. Coyle

**ABSTRACT:** To define the pathology in cases of non-Alzheimer primary degenerative dementia (non-AD PDD), we have studied autopsies from four medical centres accessioned in consecutive years since 1976. Neurochemical studies of the basal forebrain-cortical (BF-C) cholinergic system have been conducted in cases from which frozen tissue was available. Twenty-two cases (mean age 70 years, range 47-86) in which the history was consistent with PDD, but which did not meet anatomic criteria for AD, were selected. Approximately 70 cases of PDD, which were accessioned in the same years and met the anatomic criteria for AD, were excluded. The pathologic findings permitted a classification into six groups: Lewy body disease (LBD), 4 cases; Pick's disease, 6 cases; cortical degeneration with motor neuron disease (CDmnd), 2 cases; hippocampal and temporal lobe sclerosis, 3 cases; few or nonspecific abnormalities, 5 cases; other disorders, 2 cases. Our findings suggest that LBD and Pick's disease account for a large proportion of cases of non-AD PDD in the presenile age group, but that a large number of other disorders occasionally present as PDD. Careful examination of the motor systems, as well as cerebral structures related to cognitive function, is important in the neuropathologic evaluation. Lesions of the BF-C cholinergic system have been most consistent and severe in LBD, and have not been identified in CDmnd.

**RÉSUMÉ:** La démence primaire d'origine dégénérative sans les caractéristiques pathologiques de la maladie d'Alzheimer. Nous avons étudié du matériel d'autopsies accumulé depuis 1974, provenant de quatre centres médicaux, afin de préciser la pathologie chez les cas de démence primaire d'origine dégénérative de type non-Alzheimer (DPD non-MA). Nous avons procédé à des études neurochimiques du système cholinergique du cortex de la face inférieure du prosencéphale (C-IP) chez les cas pour lesquels du tissu congelé était disponible. Nous avons choisi 22 cas (âge moyen 70 ans, écart 47-86) qui avaient une histoire compatible avec une DPD, mais qui ne correspondaient pas aux critères anatomiques de la MA. Nous avons exclu à peu près 70 cas de DPD, accumulés au cours des mêmes années et qui rencontraient les critères anatomiques de la MA. Les constatations pathologiques nous ont permis de classer ces cas en six groupes: la maladie à corps de Lewy (MCL), 4 cas; la maladie de Pick, 6 cas; la dégénérescence corticale avec maladie du neurone moteur (DC mnm), 2 cas; la sclérose de l'hippocampe et du lobe frontal, 3 cas; peu d'anomalies ou des anomalies non spécifiques, 5 cas; d'autres affections, 2 cas. Ces observations nous autorisent à penser que la MCL et la maladie de Pick sont responsables d'une grande partie des cas de DPD non-MA chez les patients qui sont dans le groupe d'âge pré-sénile, mais que un grand nombre d'autres affections se présentent occasionnellement comme la DPD. Il est important d'examiner attentivement les systèmes moteurs ainsi que les structures cérébrales en rapport avec les fonctions cognitives lors de l'évaluation du système cholinergique du C-IP, qui sont les plus constantes et les plus sévères. Ces lésions sont absentes dans la (DC mnm).

*Can. J. Neurol. Sci. 1986; 13:462-470*

Alzheimer's disease (AD) is a common cause of dementia in middle and later life. The term primary degenerative dementia (PDD) has been used as a synonym for AD in clinical practice.<sup>1</sup> Clinical evaluation using established criteria for PDD can detect AD with a specificity of more than 80%,<sup>2,3</sup> and this percentage can probably be increased by choosing even more restrictive criteria for AD.<sup>4</sup>

Despite this reassuring record of clinical diagnosis, there are numerous cases of PDD which do not have the pathologic

features of AD at biopsy<sup>5,6,7</sup> or autopsy.<sup>2,3,7,8</sup> The clinician or the pathologist confronted with such cases may have difficulty in choosing further studies, because there has been no satisfactory classification of PDD without Alzheimer pathology. This deficiency has also impeded application of basic research strategies used in AD.

In an effort to define the spectrum of non-AD PDD, we conducted a study of autopsies in which the history was consistent with PDD. The cases which did not meet pathologic cri-

From the Departments of Pathology and Clinical Neurosciences, University of Calgary School of Medicine, Calgary (Drs. Clark, Parhad and Curry); The Department of Pathology, Southwestern Medical School, Dallas, Texas (Dr. White); The Departments of Pathology and Neurology, Georgetown University School of Medicine, Washington, D.C. (Dr. Manz); the Departments of Neurology and Neuroscience, Johns Hopkins University School of Medicine, Baltimore, Maryland (Dr. Whitehouse); the Department of Neurosciences, CIBA-GEIGY Corporation, Summit, New Jersey (Dr. Lehmann) and the Departments of Psychiatry, Neurosciences, Pharmacology and Pediatrics, Johns Hopkins University School of Medicine, Baltimore, Maryland (Dr. Coyle)

Reprint requests to: Dr. Arthur Clark, Department of Pathology, 11th Floor, Foothills Hospital, 1403 - 29th Street N.W., Calgary, Alberta, Canada T2N 2T9

teria for AD could be classified on the basis of neuropathologic features. Because these cases resembled AD clinically, and because lesions of the basal forebrain-cortical (BF-C) cholinergic system are believed to play a major role in the neuropsychologic deficits of AD, we have studied chemical and anatomic aspects of this system in cases from which appropriate material was available.

#### MATERIALS AND METHODS

Autopsy material from four medical centres, accessioned in consecutive years since 1976, served as the source of the case material. Cases were selected for study only if the clinical records indicated the presence of dementia consistent with PDD. Anatomic and chemical methods have been previously described.<sup>9,10,11,12</sup> The silver stains used (Bielschowsky, Naoumenko-Feigin, Sevier-Munger, and Bodian) were those in routine use by the participating laboratories for detection of NP and NFT. All cases selected had fewer than seven NP per mm<sup>2</sup> of neocortex, NFT were identified in the hippocampus of a few cases in groups I and V, but were rare in neocortex.

#### RESULTS

Twenty-two cases of PDD which did not meet anatomic criteria for Alzheimer's disease were identified and were classi-

fied according to the neuropathologic findings (groups I-VI). Approximately 70 cases which met anatomic criteria for AD, and which were identified in the autopsy material accessioned during the same years, were excluded from this study.

#### Group I. Lewy Body Disease

Clinical and pathological data on these four cases are shown in Tables 1A and 1B. Moderate numbers of NP were present in case I-1, but these were rare in the other three cases (Table 1B). Lewy bodies were numerous in the usual subcortical sites of all these cases.

In cases I-1 and I-2, our anatomic and chemical findings indicate severe damage to the BF-C cholinergic system. Maximum population density of neurons in the midportion of the NBM, expressed as neurons/mm<sup>2</sup>, were approximately a third those of controls (case I-1,  $54 \pm 8$ ; case I-2,  $58 \pm 8$ ; controls,  $167 \pm 29$ ; all values expressed as mean  $\pm$  SEM). Choline acetyltransferase (CAT) activity in neocortex was about one fifth that of controls (case I-1,  $1.02 \pm 0.22$ ; case I-2,  $0.97 \pm 0.08$ ; controls,  $5.35 \pm 1.40$  nmol/mg protein/hr, all values expressed as mean  $\pm$  SEM).<sup>13</sup>

#### Group II. Pick's Disease

We have subdivided these cases to correspond to groups A, B, and C of Constantinidis et al. (14; Tables 2A, 2B). In variant A,

Table 1: Lewy Body Disease

#### A. Clinical Data

Case Number	Age (yrs)	Sex	Duration of Dementia (yrs)	Clinical Diagnosis	Other Clinical Data
I-1	55*	F	(chronic)	AD	severe, progressive dementia
I-2	73	F	7	AD	Early difficulty following directions and dressing herself; subsequently, severe jargon aphasia, diffusely abnormal EEG; mild tremor, shuffling gait, rigidity, grasp reflexes.
I-3	63	M	20	AD	
I-4	79	M	5	AD	Transient delirium; fluctuating behavioral aberrations; subsequent loss of ability to provide for himself; diffusely abnormal EEG; CT: mild atrophy, left parietal "infarct".

\*approximate age

Table 1: Lewy Body Disease

#### B. Pathological Data

Case Number	Brain Wt (grams)	Gross Findings	Microscopic Findings
I-1	1060	Moderate cortical atrophy	4 NP/mm <sup>2</sup> of neocortex. NFT rare in neocortex; moderate number of NFT in hippocampus. Lewy body-like inclusions frequent in cortex; Lewy bodies in some remaining cells of NBM.
I-2	1180	Moderate cortical atrophy	Fewer than 1 NP/mm <sup>2</sup> of neocortex; no NFT in neocortex, small number in hippocampus. Moderate number of Lewy body-like inclusions in neocortex. Lewy bodies in some remaining cells of NBM.
I-3	1270	Minimal cortical atrophy. Enlarged ventricles.	Fewer than 1 NP/mm <sup>2</sup> of neocortex; rare NFT in temporal neocortex and hippocampus. Lewy bodies not identified in NBM; occasional NFT.
I-4	1255	Atrophy of the anterior third of superior temporal gyrus. No grossly apparent infarction. Acute meningitis and multiple small brain abscesses.	No NP or NFT in neocortex. Rare NFT in hippocampus. Frequent Lewy body-like inclusions in neocortex. Lewy bodies and moderate cell loss in NBM.

both Pick bodies and swollen chromatolytic neurons (SCN) were identified; in variant B, there were SCN but no Pick bodies. In our one case of variant C (IIc-1), where neither Pick bodies nor SCN were identified, the sharply circumscribed frontal atrophy (Figure 1), and a distribution of subcortical lesions similar to that in case IIa-3, led to its inclusion as a case of Pick's disease.

Studies of neocortical CAT in case IIb-1 and of representative sections of the NBM in cases IIb-1 and IIb-2 revealed no lesions of the BF-C cholinergic system.<sup>9</sup> In case IIa-2, representative sections of the NBM showed no difference from normal controls.

**Group III. Cortical Degeneration with Motor Neuron Disease (CDmnd)**

Clinical and pathological data are shown in Tables 3A and 3B. In neither case could we identify lesions of the BF-C cholinergic system. CAT activity in neocortex of case III-1 was  $3.78 \pm 0.92$  nmol/mg protein/hr (Controls,  $3.89 \pm 0.93$ , mean  $\pm$  SEM). Cell counts in the NBM were normal.<sup>15</sup>

**Group IV. Hippocampal and Temporal Lobe Sclerosis**

In case IV-1, loss of pyramidal cells from the hippocampus was marked, while lesions in neocortex were less severe. In cases IV-2 and IV-3, the relative severity was reversed, with

**Table 2: Pick's Disease**

**A. Clinical Data**

Case number	Age (yrs)	Sex	Duration of Dementia (yrs)	Clinical Diagnosis	Other Clinical Data
IIa-1	69	F	15	Chronic organic brain syndrome	Decorticate posturing terminally; in nursing home for several years.
IIa-2	78	M	11	Chronic organic brain syndrome due to cerebral atherosclerosis.	
IIa-3	69	F	7	AD	Memory loss, repetition of statements, impaired comprehension, impaired ability to carry out housework, disinhibited social behaviour, anomia, disorientation to place.
IIb-1	63	M	4	AD	Personality changes; rapid onset of impaired speech and comprehension; marked disorientation (Reference 9).
IIb-2	72	F	7	AD	Memory loss, bizarre behaviour, dysphasia (Reference 9).
IIc-1	64	M	11	AD	Occasional disorientation, impaired problem solving; memory loss; inappropriate social behaviour; perseveration of speech, dysphasia; marked disorientation; loss of ability to recognize family members.

**Table 2: Pick's Disease**

**B. Pathological Data**

Case Number	Brain Wt (grams)	Gross Findings	Microscopic Findings
IIa-1	1080	Profound temporal lobe atrophy, less severe frontal atrophy	No NP or NFT. Numerous Pick bodies in granule cells of dentate gyrus and pyramidal cells of hippocampus, numerous SCN in neocortex, extensive cell loss and gliosis in cortex.
IIa-2	825	Marked frontal and temporal gyral atrophy. Marked enlargement of ventricles.	3 NP/mm <sup>2</sup> of parietal and occipital neocortex only; no NFT; No NP or NFT in hippocampus. Pick bodies in dentate granule cells, hippocampal pyramidal cells, and cells of neocortex. Gliosis in frontal white matter. No apparent cell loss in NBM.
IIa-3	945	Sharply circumscribed frontal atrophy.	3 NP/mm <sup>2</sup> . Numerous Pick bodies and SCN in neocortex; severe cell loss in substantia nigra; gliosis and cell loss in neostriatum.
IIb-1	1300	Moderate frontal atrophy	Cortical degeneration with numerous SCN. (Reference 9)
IIb-2	1070	Moderate frontal atrophy, slight superior temporal atrophy.	Cortical degeneration with numerous SCN. (Reference 9)
IIc-1	1248	Sharply circumscribed frontal atrophy (Figure 1).	Fewer than 1 NP/mm <sup>2</sup> of neocortex; NFT rare. Cortical degeneration less than expected from extent of gross atrophy. Severe cell loss in substantia nigra, gliosis in neostriatum.

hippocampal damage less severe than the lesions of temporal cortex (Tables 4A and 4B). The possibility that IV-2 and IV-3 represent cases of Pick's disease is discussed below.

#### Group V. Few or Nonspecific Findings

Clinical and pathological data are shown in Table 5. The cases in this group were on the average older at the time of death ( $80 \pm 4$  years, mean  $\pm$  SEM) than cases in the other groups ( $67 \pm 8$  years).

#### Group VI. Other Disorders

Two different disorders are included in this group (Table 6). Multiple small infarcts associated with subcortical demyelination and axonal loss, and moderate loss of neurons from the NBM, were identified in case VI-1. In case VI-2, severe degeneration of subcortical white matter, descending motor pathways, thalamus, and other subcortical nuclei, were salient features; no infarcts were identified.

### DISCUSSION

In the cases of this report, the extent of Alzheimer-type degeneration was insufficient to account for the dementia. In all cases except those of group V, another form of CNS degeneration was prominent, and appeared to have played a major role in the cognitive dysfunction.

A retrospective study of autopsy material has certain limitations. Clinico-anatomic correlations cannot be as precise as in prospective studies.<sup>2,3</sup> In the present series, the clinical diagnoses rendered did not make explicit reference to a uniform set of criteria for PDD. Nonetheless, our results suggest that the standards of clinical evaluation in these cases were appropriate. The lesions we identified were those of chronic CNS degeneration, in most cases likely to be indistinguishable from AD on clinical grounds. A comparison of our findings with previous reports provides additional insight into this problem.

#### Lewy Body Disease

The term "Lewy body disease" (LBD)<sup>16</sup> encompasses most cases of idiopathic Parkinson's disease, but uses a pathologic feature rather than a clinical syndrome as the basis for the designation. Since many of these cases present with mental

disturbance rather than Parkinsonism as the dominant clinical manifestation,<sup>2,3,17-20</sup> use of the term LBD has certain advantages. Cortical Lewy body-like inclusions are found in a minority of cases, all of which also have classic Lewy bodies in the usual subcortical sites. The cortical inclusion bodies may thus represent trans-synaptic degeneration consequent to loss of subcortical input.<sup>21</sup>

Previous pathologic studies<sup>22,23</sup> have emphasized the coexistence of Alzheimer-type neuropathologic changes in the brains of patients with LBD. While some overlap between LBD and AD does exist,<sup>17,22-25</sup> it is equally clear that dementia is present in some cases of LBD with very few NP or NFT.<sup>2,3,20,25,27-29, present cases</sup>

Lesions of the BF-C cholinergic system are characteristic of these cases,<sup>27,29-35, present cases</sup> but lesions in other systems may contribute to the dementia.<sup>36</sup> In some LBD cases, BF-C cholinergic system lesions occur with very few NP or NFT.<sup>25,27,29, 32,37, present cases</sup> The lack of correlation between BF-C cholinergic lesions and AD type pathology is illustrated by our cases I-1 and I-2. Severe loss of cortical CAT activity and depletion of NBM neurons in each case was associated with moderate numbers of neocortical plaques in the first case and virtually none in the second.

#### Pick's Disease

The difficulty of distinguishing AD from Pick's disease on clinical grounds is well known.<sup>38</sup> Large autopsy series of Pick's disease cases have been published.<sup>14,39</sup> We include in this series a case (IIC-1) without Pick bodies or SCN, similar to the group C cases of a previous report.<sup>14</sup> The sharply circumscribed atrophy of frontal cortex in this case corresponds to Pick's lobar atrophy; and the involvement of subcortical nuclei closely resembled that in case IIA-3. Retention of such cases as a variant of Pick's disease both favors simplicity and emphasizes important distinctions. The pathological diagnosis of such cases remains problematic, however,<sup>9,40</sup> much like the diagnosis of "Creutzfeldt-Jakob disease" and related entities prior to 1960.

There are reports describing involvement of the BF-C cholinergic system in Pick's disease,<sup>41,42</sup> and others in which this system was studied and no significant loss of NBM neurons or CAT activity in cortex was identified.<sup>7,43-46, present cases IIA-2, IIB-1, IIB-2</sup> This variability from case to case may be related to the pathogenetic mechanism of cell loss in the NBM. Specifically, the loss of neurons in the basal forebrain in Pick's disease could be a late, retrograde consequence of cortical degeneration, and dependent on duration and severity of cortical involvement for its appearance. Cases of short duration with severe nbm cell loss have been reported, however.<sup>41</sup> Correlation of chemical and anatomic findings in cortex with cell counts in the NBM of individual cases will help clarify the significance and frequency of BF-C cholinergic system lesions in Pick's disease.

#### Cortical Degeneration Associated with Motor Neuron Disease (CDmnd)

Most cases with these features are probably related to amyotrophic lateral sclerosis.<sup>47-50</sup> Similar cases have been reported as Pick's disease with ALS,<sup>51,52</sup> Creutzfeldt-Jakob disease,<sup>50</sup> dementia with amyotrophic lateral sclerosis,<sup>47,48</sup> a distinct entity of dementia with motor neuron disease,<sup>53,54</sup> or as unusual

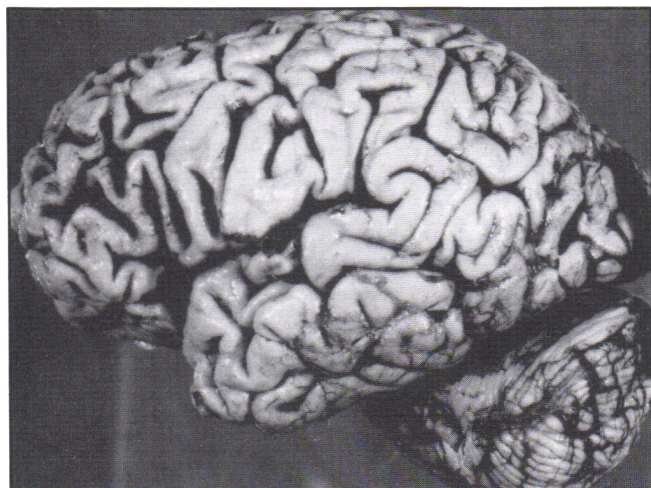


Figure 1 — Sharply circumscribed frontal atrophy in case IIC-1.



**Table 3: Cortical Degeneration with Motor Neuron Disease****A. Clinical Data**

Case Number	Age (yrs)	Sex	Duration of Dementia (yrs)	Clinical Diagnosis	Other Clinical Data
III-1	61	F	5	AD	Personality changes, impaired comprehension, dysarthria, progressive decrease in speech output, disorientation to time and place, hyperactive reflexes and ankle clonus, flexor plantaris; later, stooped, shuffling gait, cogwheel rigidity.
III-2	77	F	5	(dementia clinically consistent with AD)	Marked memory deficit, flat affect, little spontaneous speech, inappropriate answers to questions, hyperactive reflexes; progression to mutism and total supportive care.

**Table 3: Cortical Degeneration with Motor Neuron Disease****B. Pathological Data**

Case Number	Brain Wt (grams)	Gross Findings	Microscopic Findings
III-1	1100	Moderate frontal atrophy	No NP or NFT. Cortical neuron loss and rarefaction; cell loss and gliosis in dorsal caudate and substantia nigra; degeneration of lateral corticospinal tracts, loss of anterior horn cells; numerous Bunina body-type inclusions in motor neurons of spinal anterior horn and hypoglossal nucleus.
III-2	1190	Mild symmetric frontal lobe atrophy	Severe cortical degeneration, with neuronal loss and gliosis; severe amyloid angiopathy; fewer than 1 NP/mm <sup>2</sup> of cortex, NFT very rare in neocortex and hippocampus; loss of motor neurons, with occasional Bunina bodies and increased number of large axonal swellings in spinal anterior horns.

**Table 4: Hippocampal and Temporal Lobe Sclerosis****A. Clinical Data**

Case Number	Age (yrs)	Sex	Duration of Dementia (yrs)	Clinical Diagnosis	Other Clinical Data
IV-1	72	F	6	AD	Occasional disorientation downtown, memory loss, word-finding difficulty, slurred speech, confusion, nursing home placement 15 months before death.
IV-2	64	M	8	AD	Behaviour changes, loss of recent memory; no focal neurologic deficits; progressively unmanageable behaviour led to nursing home placement 6 months before death.
IV-3	70	M	6	AD	Forgetfulness and difficulty with manual skills; later confusion, disorientation to place, inappropriate behaviour; inability to perform simple calculations or read; severely limited speech output.

**Table 4: Hippocampal and Temporal Lobe Sclerosis****B. Pathological Data**

Case Number	Brain Wt (grams)	Gross Findings	Microscopic Findings
IV-1	1100	Minimal atherosclerosis, obvious cortical atrophy, shrunken and discolored mammillary bodies.	Severe loss of hippocampal pyramidal cells, extending from CA2 into subiculum; patchy, milder cell loss in temporal and other neocortex. Cell loss and gliosis in medial thalamus. No NFT or NP identified. No histologic features of Wernicke's encephalopathy. NBM shows no cell loss.
IV-2	1200	Minimal atherosclerosis, severe temporal and moderate frontal lobe atrophy.	Severe cell loss, rarefaction, gliosis in temporal neocortex; moderate cell loss in hippocampus; cell loss and gliosis in frontal neocortex less marked than in temporal. No NFT or NP identified.
IV-3	1020	No atherosclerosis, generalized atrophy, most marked in frontal and temporal regions; enlargement of ventricular system, most pronounced in temporal horn.	Severe cell loss and gliosis in temporal cortex, less severe in frontal cortex; moderate cell loss in hippocampus; no NFT; rare NP.

cases of dementia in which pathologic involvement of the motor neurons is discovered at autopsy.<sup>55</sup> A common pathogenesis and etiology may unite many of them. Their existence emphasizes the importance of carefully examining the motor system in cases of PDD. Data on the motor systems in classic Pick's disease and variants would help clarify the interface between Pick's disease and CDmnd.

Damage to cholinergic motor neurons is a hallmark of these cases. In contrast, no lesions of the BF-C cholinergic system have been identified,<sup>49,56</sup> findings in accord with our data. Thus the available evidence suggests that lesions of the BF-C cholinergic system do not play a significant role in the dementia of CDmnd.

Extensive amyloid angiopathy like that in case III-2 is commonly associated with NP, but the numbers are often small.<sup>57,58</sup> The rarity of NFT and NP in our case excluded the diagnosis of AD. The diffuse cortical degeneration and the dementia were more likely related to the neurodegenerative process than to the amyloid angiopathy, although a contribution of the latter is difficult to exclude.

### Hippocampal and Temporal Lobe Sclerosis

At least seven such cases have now appeared in reports on PDD,<sup>2,3, present cases</sup> but it is not clear that these cases represent a distinct entity. Preferential damage to amygdala, hippocampus, and temporal cortex can result from various disorders, and occasional cases of each might present as PDD. Disorders other than AD which can preferentially affect these structures include Pick's disease, limbic encephalitis, herpes simplex encephalitis, and ischemia.

In two of our three cases (IV-2 and IV-3), a preferential atrophy of anterior temporal and frontal regions suggested the possibility of Pick's disease on gross examination. Lesions of the hippocampus in these two cases were much less extensive than those of temporal neocortex. This order of severity is identical to that observed by Constantinidis in the Pick's disease cases of group C with atrophy predominantly in the temporal region; he noted that the hippocampus was routinely "spared" in these cases.<sup>14</sup> We did not classify cases IV-2 and IV-3 as Pick's disease because we could not document either a circumscribed lobar atrophy or the SCN or Pick bodies of that disorder.

**Table 5: Few or Nonspecific Abnormalities**

Case Number	Clinical Data	Pathological Data
V-1	74 year old man, 10 year history diagnosed "advanced AD".	Brain weight 1280 grams. Rare NFT, moderate number of NP (Fewer than 7 NP/mm <sup>2</sup> of neocortex).
V-2	81 year old woman; organic brain syndrome for 10 years; tardive dyskinesia.	Brain weight 1225 grams. Recent large left frontal infarct, older lacunar infarcts. Fewer than 1 NP/mm <sup>2</sup> of neocortex. 3 NFT/mm <sup>2</sup> in parts of hippocampus; occasional NFT in neocortex.
V-3	77 year old man with more than 30 year history of dementia, diagnosed AD.	No abnormal findings except very small numbers of NP and NFT.
V-4	82 year old woman with mild "senile organic brain syndrome" for several months; normal brain scan 2 months prior to death.	Brain weight 1090 grams. Slight frontal atrophy and increased size of ventricles, minimal atherosclerosis; very rare NP in cortex; proliferative changes in cortical vessels related to hypertension.
V-5	86 year old man with chronic dementia.	Brain weight 1300 grams. Sulcal widening, enlarged ventricles. No focal lesions. Fewer than 1 NP/mm <sup>2</sup> of cortex. Occasional NFT in hippocampus.

**Table 6: Other Disorders**

Case Number	Clinical Data	Pathological Data
VI-1	62 year old man, 6 year history of dementia, believed to be AD or Pick's disease; wide-based gait, ataxia, and urinary incontinence also developed.	Brain weight 1210 grams. Moderate cortical atrophy. Lacunar infarct in thalamus, other small infarcts in cortex. Trans-synaptic degeneration of both mammillary bodies. Large, discrete, relatively symmetric zones of subcortical demyelination with variable axonal loss but without cavitation. Demyelinated areas resembled plaques of multiple sclerosis in some areas, notably cerebellum, pons, and spinal cord. Congo red stains negative for amyloid angiopathy.
VI-2	47 year old man, 9 year history of dementia. "Blurred" vision. Personality change. Impaired calculations, poor coordination. Evaluation 6 years before death indicated advanced cerebral cortical atrophy without involvement of cerebellum or basal ganglia. Shuffling gait, slurred speech, wheelchair, then bedridden state with muscle "rigidity" preceded death.	Cortical biopsy 6 years before death showed no specific pathologic change. Brain weight 1139 grams. Extremely wide sulci, especially over frontal convexities; markedly enlarged ventricle; extensive atrophy and discoloration of subcortical white matter. Severe atrophy of thalamus, marked atrophy of caudate. Histologically, severe neuronal loss in several thalamic nuclei, severe degeneration of subcortical fibres and corticospinal tracts, swelling and chromatolysis of almost all neurons in nuclei basis pontis.

Limbic encephalitis may occur in the absence of detectable neoplasia.<sup>59</sup> Inflammatory cells may be sparse in the residual lesion, with neuronal loss and gliosis involving hippocampus, amygdala, and adjacent neocortex as the dominant neuropathological features.<sup>60,61</sup> Cortical and subcortical areas outside the limbic system are affected in some cases.<sup>61,62</sup> A number of reports have described cases with hippocampal sclerosis, in which limbic encephalitis was the final diagnosis<sup>59,61,63</sup> or was consistent with the data provided in the report.<sup>60,64</sup> Some cases of hippocampal sclerosis, such as our case IV-1, may represent sequelae of limbic encephalitis. The possibility of altered expression of herpes simplex encephalitis should also be considered in these patients; efforts at *in situ* hybridization may be warranted.

Volpe et al<sup>65</sup> have recently reported cases of dementia associated with bilateral medial temporal lobe ischemic lesions. Clinical and pathologic features in our cases did not support an ischemic cause. Atherosclerosis was minimal in the two cases where it was specifically mentioned; there was no clinical or pathologic evidence of significant hypertension; and the distribution of the lesions did not correspond to the territory of a particular vessel.

#### Few or Nonspecific Findings

Correlation between morphologic findings and the history of dementia was unsatisfactory in these cases. Small numbers of neuritic plaques, occasional small infarcts, and a few neurofibrillary tangles confined to the hippocampus were characteristic findings. Previous reports have included cases with little apparent pathologic change at autopsy.<sup>2,3,7,8</sup> The problem arises in a large percentage of biopsied cases.<sup>5-7</sup>

The average age in group V was greater than in other groups of this study. Nonspecific cell loss or other factors difficult to detect with standard microscopic evaluation may have contributed to the cognitive dysfunction. Moreover, we cannot exclude the possibility that depression, systemic illness, or medications played a role in one or more of the cases in this group.

#### Other

The first of our cases in this group resembled cases reported by Heffner et al,<sup>66</sup> but we were unable to document amyloid in cerebral vessels. Mechanisms described by Feigin<sup>67</sup> may have been of pathogenetic importance. The second case resembles some reported cases of thalamic degeneration,<sup>68</sup> but the severity of subcortical axonal destruction was distinctive.

These cases and other entities, such as progressive subcortical gliosis,<sup>69</sup> emphasize the difficulty of classifying PDD. Recent reports indicate that occasional cases of progressive supranuclear palsy,<sup>70</sup> of Creutzfeldt-Jakob disease,<sup>71</sup> of dementia with HTLV-III/LAV infection of the CNS,<sup>72</sup> and of neuronal intranuclear hyaline inclusion disease (Munoz-Garcia and Ludwin, present symposium) are difficult to distinguish from AD on clinical grounds.

#### Conclusion

Precision of clinical diagnosis in PDD may improve with use of neuropsychologic testing,<sup>73</sup> chemical studies of the cerebrospinal fluid,<sup>74</sup> and recent advances in brain imaging.<sup>75</sup> A clearer definition of the anatomic and chemical basis for non-AD PDD will facilitate these efforts. Previous reports relevant to this problem<sup>2,3,5,7,17,20,55,76-79</sup> have indicated the importance of LBD,<sup>2,3,17,20,79</sup> Pick's disease,<sup>7,76</sup> and CDmnd;<sup>55</sup> and the existence of

cases with hippocampal sclerosis.<sup>2,3</sup> In the present study, Pick's disease and Lewy body disease were the two major forms of non-AD PDD; but our findings and other reports indicate that a large number of other disorders occasionally present as PDD.

The BF-C cholinergic system is damaged in cases of LBD, and the lesions of this system may be important in the mental disturbances. There is no evidence for damage to this system in CDmnd. In Pick's disease, involvement of the NBM is variable and may occur later in the disease process, possibly as a result of retrograde degeneration following cortical damage.

#### ACKNOWLEDGEMENTS

This work was supported in part by a grant from the Alberta Mental Health Advisory Council (Dr. Clark).

#### REFERENCES

1. Reisberg B. Clinical presentation, diagnosis, and symptomatology of age-associated cognitive decline and Alzheimer's disease. In: Reisberg B, ed. *Alzheimer's Disease: The Standard Reference*. New York: The Free Press 1983; 173-187.
2. Sulkava R, Haltia M, Paetau A, et al. Accuracy of clinical diagnosis in primary degenerative dementia: correlation with neuropathologic findings. *J Neurol Neurosurg Psychiatr* 1983; 46: 9-13.
3. Mölsä PK, Paljärvi L, Rinne JO, et al. Validity of clinical diagnosis in dementia: A prospective clinicopathological study. *J Neurol Neurosurg Psychiatr* 1985; 48: 1085-1090.
4. Fox JH, Penn R, Clasen R, et al. Pathological diagnosis in clinically typical Alzheimer's disease (letter). *N Engl J Med* 1985; 313: 1419-1420.
5. Smith WT, Turner E, and Sim M. Cerebral biopsy in the investigation of presenile dementia. II. Pathological aspects. *Brit J Psychiatr* 1966; 112: 127-133.
6. Sims NR, Bowen DM, Smith CCT, et al. Glucose metabolism and acetylcholine synthesis in relation to neuronal activity in Alzheimer's disease. *Lancet* 1980; 1: 333-335.
7. Bowen DM, Benton JS, Spillane JA, et al. Choline acetyltransferase activity and histopathology of frontal neocortex from biopsies of demented patients. *J Neurol Sci* 1982; 57: 191-202.
8. Rossor M, Garrett NJ, Johnson AL, et al. A postmortem study of the cholinergic and GABA systems in senile dementia. *Brain* 1982; 105: 313-330.
9. Clark AW, Manz HJ, White CL III, et al. Cortical degeneration with swollen chromatolytic neurons: Its relationship to Pick's disease. *J Neuropathol Exp Neurol* 1986; 45: 268-284.
10. Bull G, Oderfeld-Novak B. Standardization of a radiochemical assay of choline acetyltransferase and a study of the activation of the enzyme in rabbit brain. *J Neurochem* 1971; 18: 935-941.
11. Fonnum F. A rapid radiochemical method for the determination of choline acetyltransferase. *J Neurochem* 1975; 24: 407-409.
12. Lowry OH, Rosebrough NJ, Farr AL, et al. Protein measurement with the Folin phenol reagent. *J Biol Chem* 1951; 193: 265-275.
13. Clark AW, Lehmann J. Dementia with widespread Lewy bodies: Studies of the neocortical cholinergic system. (Abstract), Canadian Association of Neuropathologists, 23rd Annual Meeting, Banff, Alberta, September 1983.
14. Constantinidis J, Richard J, Tissot R. Pick's disease. Histological and clinical correlations. *Europ Neurol* 1974; 11: 208-217.
15. Clark AW, Lehmann J, Whitehouse PJ, et al. Cortico-striatal degeneration (CSSD) mimicking Alzheimer's disease: Studies of the nucleus basalis of Meynert and cortical choline acetyltransferase. (Abstract) *J Neuropathol Exp Neurol* 1983; 42: 334.
16. Yoshimura M. Cortical changes in the Parkinsonian brain: A contribution to the delineation of "diffuse Lewy body disease". *J Neurol* 1983; 229: 17-32.
17. Woodard JS. Concentric hyaline inclusion body formation in mental disease: Analysis of twenty-seven cases. *J Neuropathol Exp Neurol* 1962; 21: 442-449.

18. Forno LS, Barbour PJ, Norville RL. Presenile dementia with Lewy bodies and neurofibrillary tangles. *Arch Neurol* 1978; 35: 818-822.
19. Yagishita S, Itoh Y, Amano N, et al. Atypical senile dementia with widespread Lewy type inclusions in the cerebral cortex. *Acta Neuropathol (Berl)* 1980; 49: 187-191.
20. Heilig CW, Knopman DS, Mastri AR, et al. Dementia without Alzheimer pathology. *Neurology* 1985; 35: 762-765.
21. Eggertson DE, Sima AAF. Dementia with cerebral Lewy bodies. A mesocortical dopaminergic defect? *Arch Neurol* 1986; 43: 524-527.
22. Hakim AM, Mathieson G. Dementia in Parkinson disease: a neuropathologic study. *Neurology* 1979; 29: 1209-1214.
23. Boller F, Mizutani T, Roessmann U, et al. Parkinson's disease, dementia and Alzheimer's disease: clinicopathological correlations. *Ann Neurol* 1980; 7: 329-335.
24. Rosenblum WI, Ghatak NR. Lewy bodies in the presence of Alzheimer's disease. *Arch Neurol* 1979; 36: 170-171.
25. Gaspar P, Gray F. Dementia in idiopathic Parkinson's disease: A neuropathological study of 32 cases. *Acta Neuropathol (Berl)* 1984; 64: 43-52.
26. Leverenz J, Sumi SM. Prevalence of Parkinson's disease in patients with Alzheimer's disease. (Abstract) *Neurology* 1984; 34 (Suppl 1): 101.
27. Mann DMA, Yates PO. Pathological basis for neurotransmitter changes in Parkinson's disease. *Neuropathol Appl Neurobiol* 1983; 9: 3-19.
28. Ball MJ. The morphological basis of dementia in Parkinson's disease. *Can J Neurol Sci* 1984; 11: 180-184.
29. Tagliavini F, Pilleri G, Bouras C, et al. The basal nucleus of Meynert in idiopathic Parkinson's disease. *Acta Neurol Scand* 1984; 70: 20-28.
30. Ruberg M, Ploska A, Javoy-Agid F, et al. Muscarinic binding and choline acetyltransferase activity in parkinsonian subjects with reference to dementia. *Brain Res* 1982; 232: 129-139.
31. Dubois B, Ruberg M, Javoy-Agid F, et al. A subcortico-cortical cholinergic system is affected in Parkinson's disease. *Brain Res* 1983; 288: 213-218.
32. Perry RH, Tomlinson BE, Candy JM, et al. Cortical cholinergic deficit in mentally impaired Parkinsonian patients (letter). *Lancet* 1983; 2: 789-790.
33. Candy JM, Perry RH, Perry EK, et al. Pathological changes in the nucleus of Meynert in Alzheimer's and Parkinson's disease. *J Neurol Sci* 1983; 59: 277-289.
34. Arendt T, Bigl V, Arendt A, et al. Loss of neurons in the nucleus basalis of Meynert in Alzheimer's disease, paralysis agitans, and Korsakoff's disease. *Acta Neuropathol (Berl)* 1983; 61: 101-108.
35. Whitehouse PJ, Hedreen JC, White CL III, et al. Basal forebrain neurons in the dementia of Parkinson disease. *Ann Neurol* 1983; 13: 243-248.
36. Hornykiewicz O, Kish SJ. Neurochemical basis of dementia in Parkinson's disease. *Can J Neurol Sci* 1984; 11: 185-190.
37. Nakano I, Hirano A. Parkinson's disease: Neuron loss in the nucleus basalis without concomitant Alzheimer's disease. *Ann Neurol* 1984; 15: 415-418.
38. Adams RD, Victor M. Principles of Neurology. Third edition. New York: McGraw-Hill 1985: 866-867.
39. Seitelberger F, Gross H, Pilz P. Pick's disease: A neuropathologic study. In: Hirano A, Miyoshi K, eds. *Neuropsychiatric Disorders in the Elderly*. New York: Igaku-Shoin 1981: 87-117.
40. Joachim CL, Morris JH, Schoene WC. Neuropathological findings in six cases of dementia with severe focal atrophy. (Abstract) *J Neuropathol Exp Neurol* 1986; 45: 361.
41. Uhl GR, Hilt DC, Hedreen JC, et al. Pick's disease (lobar sclerosis): Depletion of neurons in the nucleus basalis of Meynert. *Neurology* 1983; 33: 1470-1473.
42. Munoz-Garcia D, Ludwin SK. Classical and generalised variants of Pick's disease. A clinicopathological, ultrastructural, and immunocytochemical comparative study. *Ann Neurol* 1984; 16: 467-480.
43. Yates CM, Simpson J, Maloney AFJ, et al. Neurochemical observations in a case of Pick's disease. *J Neurol Sci* 1980; 48: 257-263.
44. Wood PL, Etienne P, Lal S, et al. A post-mortem comparison of the cortical cholinergic system in Alzheimer's disease and Pick's disease. *J Neurol Sci* 1983; 62: 211-217.
45. Tagliavini F, Pilleri G. Basal nucleus of Meynert. A neuropathological study in Alzheimer's disease, simple senile dementia, Pick's disease, and Huntington's chorea. *J Neurol Sci* 1983; 62: 243-260.
46. Case Records of the Massachusetts General Hospital (Case 16-1986). *N Engl J Med* 1986; 314: 1101-1111.
47. Hart MN, Cancilla PA, Frommes S, et al. Anterior horn cell degeneration and Bunina-type inclusions associated with dementia. *Acta Neuropathol (Berl)* 1977; 38: 225-228.
48. Hudson A. Amyotrophic lateral sclerosis and its association with dementia, Parkinsonism and other neurological disorders: A review. *Brain* 1981; 104: 217-247.
49. Horoupian DS, Thal L, Katzman R, et al. Dementia and motor neuron disease: Morphometric, biochemical, and Golgi studies. *Ann Neurol* 1984; 16: 305-313.
50. Salazar A, Masters C, Gajdusek DC, et al. Syndromes of amyotrophic lateral sclerosis and dementia: Relation to transmissible Creutzfeldt-Jakob disease. *Ann Neurol* 1983; 14: 17-26.
51. Brion S, Mikol J, Psimaras A. Recent findings in Pick's disease. In: Zimmerman HM, ed. *Progress in Neuropathology*, vol. 2. New York: Grune & Stratton, 1973; 421-452.
52. Brion S, Psimaras A, Chevalier JF, et al. L'association maladie de Pick et sclérose latérale amyotrophique. *L'Encephale* 1980; 6: 259-286.
53. Mitsuyama Y, Takamiya S. Presenile dementia with motor neuron disease in Japan: a new entity. *Arch Neurol* 1979; 36: 592-593.
54. Mitsuyama Y. Presenile dementia with motor neuron disease in Japan: Clinicopathological review of 26 cases. *J Neurol Neurosurg Psychiatr* 1984; 47: 953-959.
55. Hughes CP, Myers FK, Smith K, et al. Nosologic problems in dementia: A clinical and pathologic study of 11 cases. *Neurology* 1973; 23: 344-351.
56. Rogers JD, Brogan D, Mirra SS. The nucleus basalis of Meynert in neurological disease. A quantitative morphological study. *Ann Neurol* 1985; 17: 163-171.
57. Okazaki H, Reagan TJ, Campbell RJ. Clinicopathologic studies of primary cerebral amyloid angiopathy. *Mayo Clin Proc* 1979; 54: 22-31.
58. Mandybur TI. Cerebral amyloid angiopathy: The vascular pathology and complications. *J Neuropathol Exp Neurol* 1986; 45: 79-90.
59. Daniel SE, Love S, Scaravilli F, et al. Encephalomyeloneuropathy in the absence of a detectable neoplasm: Clinical and postmortem findings in three cases. *Acta Neuropathol (Berl)* 1985; 66: 311-317.
60. Duyckaerts C, Derouesne C, Signoret JL, et al. Bilateral and limited amygdalohippocampal lesions causing a pure amnesic syndrome. *Ann Neurol* 1985; 18: 314-319.
61. Henson RA, Urich H. Encephalomyelitis with carcinoma. In: Henson RA, Urich H. *Cancer and the Nervous System*. London: Blackwell 1982; 314-345.
62. Brierley JB, Corsellis JAN, Hierons R, et al. Subacute encephalitis of later adult life mainly affecting the limbic areas. *Brain* 1960; 83: 357-368.
63. Case Records of the Massachusetts General Hospital (Case 30-1985). *N Engl J Med* 1985; 313: 249-257.
64. Schubert T, Friede RL. Transneuronal mammillary atrophy. *J Neurol* 1979; 221: 67-72.
65. Volpe BT, Petito CK. Dementia with bilateral medial temporal lobe ischemia. *Neurology* 1985; 35: 1793-1797.
66. Heffner RR, Porro RS, Olson ME, et al. A demyelinating disorder associated with cerebrovascular amyloid angiopathy. *Arch Neurol* 1976; 33: 501-506.
67. Feigin I, Popoff N. Neuropathological changes late in cerebral edema: The relationship to trauma, hypertensive disease and Binswanger encephalopathy. *J Neuropathol Exp Neurol* 1963; 22: 500-511.
68. Martin JJ. Thalamic degenerations. In: Vinken PJ, Bruyn GW, eds. *Handbook of Clinical Neurology*, vol. 21. New York: Elsevier 1975; 587-604.
69. Neumann MA, Cohn R. Progressive subcortical gliosis, a rare form of presenile dementia. *Brain* 1967; 90: 405-418.
70. Davis PH, Bergeron C, McLachlan DR. Atypical presentation of progressive supranuclear palsy. *Ann Neurol* 1985; 17: 337-343.
71. Brown P, Johnson PR, Cathala F, et al. Creutzfeldt-Jakob disease



- of long duration: Clinicopathological characteristics, transmissibility, and differential diagnosis. *Ann Neurol* 1984; 16: 295-304.
72. Mirra SS, Anand R, Spira TJ. HTLV-III/LAV infection of the central nervous system in a 57-year-old man with progressive dementia of unknown cause. (Letter) *N Engl J Med* 1986; 314: 1191-1192.
  73. Fuld PA, Katzman R, Davies P, et al. Intrusion as a sign of Alzheimer dementia: Chemical and pathological verification. *Ann Neurol* 1982; 11: 155-159.
  74. Tune L, Gucker S, Folstein M, et al. Cerebrospinal fluid acetylcholinesterase activity in senile dementia of Alzheimer type. *Ann Neurol* 1985; 17: 46-48.
  75. Jagust WJ, Friedland RP, Budinger TF. Positron emission tomography with <sup>18</sup>F Fluorodeoxyglucose differentiates normal pressure hydrocephalus from Alzheimer-type dementia. *J Neurol Neurosurg Psychiat* 1985; 48: 1091-1096.
  76. Neumann MA, Cohn R. Degenerative cerebral diseases and their relation to aging. *In: Proceedings of the VIIIth International Congress of Neuropathology*. Amsterdam: Excerpta Medica 1975; 75-78.
  77. Tomlinson BE, Blessed G, Roth M. Observations on the brains of non-demented old people. *J Neurol Sci* 1968; 7: 331-356.
  78. Tomlinson BE, Blessed G, Roth M. Observations on the brains of demented old people. *J Neurol Sci* 1970; 11: 205-242.
  79. Perl DP, Pendlebury WW, Bird ED. Detailed neuropathologic evaluation of banked brain specimens submitted with a clinical diagnosis of Alzheimer's disease (Abstract). *In: Wurtman RJ, Corkin SH, Growdon JH, eds. Proceedings of the Third Meeting of the International Study Group on the Treatment of Memory Disorder Associated with Aging*. Center for Brain Sciences and Metabolism Charitable Trust 1984; 463.