


# Is there still a role for nasal closure in hereditary haemorrhagic telangiectasia?

Robert Bickerton<sup>1</sup> , Benjamin Kennard<sup>1</sup>, Nikita Mehtani<sup>1</sup>, Elizabeth Bullock<sup>1</sup>, Talisa Ross<sup>1,2</sup>, Vikas Acharya<sup>1</sup> and Catherine Rennie<sup>1</sup>

<sup>1</sup>Department of Ear, Nose and Throat Surgery, Imperial College Healthcare Trust, London, UK and <sup>2</sup>EvidENT Team, University College London, London, UK

## Main Article

Robert Bickerton takes responsibility for the integrity of the content of the paper

**Cite this article:** Bickerton R, Kennard B, Mehtani N, Bullock E, Ross T, Acharya V, Rennie C. Is there still a role for nasal closure in hereditary haemorrhagic telangiectasia? *J Laryngol Otol* 2025;**139**:118–124. <https://doi.org/10.1017/S0022215124001300>

Received: 10 March 2024  
Revised: 22 May 2024  
Accepted: 29 May 2024  
First published online: 21 October 2024

### Keywords:

bevacizumab; epistaxis; hereditary haemorrhagic telangiectasia; HHT; nasal closure; quality of life; rhinology

### Corresponding author:

Robert Bickerton;  
Email: [r.bickerton1@nhs.net](mailto:r.bickerton1@nhs.net)

## Abstract

**Objective.** Hereditary haemorrhagic telangiectasia (HHT) is characterised by recurrent, severe epistaxis. While nasal closure is a relatively well-established treatment for HHT patients with intractable epistaxis, recent studies highlight the efficacy of bevacizumab in this subgroup. We aim to evaluate the effectiveness of nasal closure for patients with contraindications to bevacizumab.

**Methods.** A case series of five patients with HHT and severe refractory transfusion-dependent epistaxis who were treated with nasal closure.

**Results.** All patients had subjective improvement in epistaxis. Haemoglobin concentrations increased in all patients, with none requiring transfusion for epistaxis post-operatively. Four patients experienced complete cessation in epistaxis. Four returned positive Glasgow Benefit Inventory scores.

**Conclusion.** Nasal closure appears to be a safe and effective option for the management of epistaxis in patients with severe, refractory HHT-related epistaxis. Treatment improved quality of life, reduced severity of epistaxis and increased haemoglobin concentrations. Nasal closure should be considered for HHT patients with severe, refractory epistaxis, particularly in cases where bevacizumab is contraindicated.

## Introduction

Hereditary haemorrhagic telangiectasia (HHT) is a rare autosomal-dominant inherited disorder characterised by widespread mucocutaneous telangiectasias and visceral arteriovenous malformations. It affects approximately 1 in 6000 Europeans.<sup>1</sup>

Common genetic mutations include ENG (52 per cent), ACVRL1 (44 per cent) and SMAD4 (2 per cent), each having overlapping phenotypes with the latter additionally predisposing to gastrointestinal malignancies.<sup>2</sup> Downstream signalling results in upregulation of vascular endothelial growth factor (VEGF), causing endothelial proliferation and the characteristic arteriovenous malformations and telangiectasia.<sup>3</sup>

Presence of these malformations in the nasal mucosa cause recurrent and severe epistaxis which typically has a significant impact on the patient's quality of life.<sup>4</sup> Telangiectasias are thin-walled and lack contractile elements, so bleeding can be challenging to control.<sup>5</sup>

Diagnosis is based on the Curaçao criteria (Figure 1). Certain diagnosis requires three of the following criteria: recurrent spontaneous epistaxis, mucocutaneous telangiectasia, visceral malformations, family history (first-degree relative).<sup>6</sup> Genetic testing for the aforementioned mutations is used to confirm the diagnosis and variant.

Management of recurrent epistaxis in patients with HHT is challenging, requiring a multidisciplinary approach with haematologists, otolaryngologists, geneticists, respiratory physicians, hepatologists, paediatricians and clinical nurse specialists.<sup>1</sup> Conservative, medical and surgical treatments are frequently used in tandem.

Patients are educated in first aid and may be provided with methods to reduce the severity of nosebleeds at home. Medical management with topical moisturising therapy or rotating antibacterial creams can be beneficial.<sup>7</sup> Two randomised controlled trials have shown oral tranexamic acid significantly reduces the severity of nosebleeds.<sup>8,9</sup>

Bevacizumab (Avastin®) is increasingly being used for refractory cases. It prevents formation of new vascular malformations in the nasal mucosa by inhibiting vascular endothelial growth factor (VEGF) and therefore acts as an anti-angiogenic agent.

A recent international multi-centre study, the InHIBIT-Bleed study, found reduced epistaxis severity, increased haemoglobin levels and reduced requirement for blood transfusions with systemic use.<sup>10</sup> However, the study is limited by its retrospective nature, resulting in heterogeneous delivery of intervention across sites. Additionally, the lack of randomisation increased the risk of confounding factors, which could have affected outcomes. The study identified six severe adverse events amongst participants, possibly, probably or certainly related to the treatment.

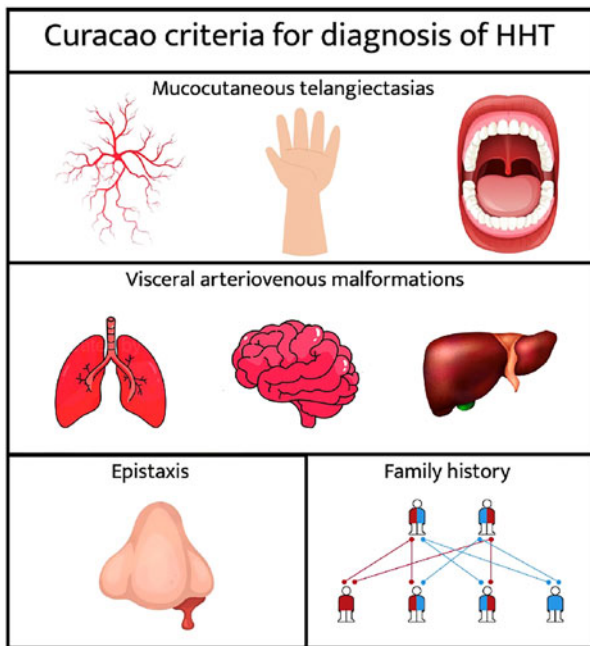


Figure 1. Curacao criteria for diagnosis of HHT.

Studies have also shown only a short-term benefit from bevacizumab, in addition to no perceivable effect on frequency and duration of epistaxis episodes in a recent systematic review and meta-analysis.<sup>11</sup> Furthermore, bevacizumab is contraindicated in patients with arteriopathy (atherosclerotic disease with a history of ischaemic complications), risk factors for or recent thromboembolic events and severe pulmonary hypertension.<sup>12,13</sup>

Surgical management traditionally includes ablation of vascular malformations either with potassium titanyl phosphate (KTP)/argon/blue laser, radiofrequency, electrosurgery or coblation.<sup>14</sup> Repeated ablative procedures can lead to septal perforation; and the laser tends to cause less surrounded thermal damage to tissues than electrocautery or coblation. Should ablative therapies fail, patients are considered for septodermoplasty in which nasal mucosa is covered with split-thickness skin flaps.<sup>15</sup>

In recent years, nasal closure has been used with increasing frequency for severe refractory epistaxis in HHT, but there is limited research on its efficacy. Austen Young first described nasal closure in 1967 as a treatment for atrophic rhinitis.<sup>16</sup> Two flaps are raised and sutured together to close the nasal vestibule. A modified three-flap technique, the Lund-modification of Young's procedure, was first pioneered in the late 1990s and is used for patients with severe refractory epistaxis in HHT.<sup>17</sup>

Theoretically, nasal closure prevents the drying of nasal mucosa caused by constant airflow, thus reducing the frequency of epistaxis.<sup>18</sup> Lund et al. found dramatic improvements in subjective epistaxis severity and post-operative quality of life in their case series,<sup>19</sup> with similar results among other large centres.<sup>20–23</sup>

For the past three years, we have been performing nasal closure for HHT patients with severe transfusion-dependent epistaxis which persists despite optimal medical and surgical management. Due to concurrent co-morbidities, a number of these patients were ineligible for bevacizumab therapy. Here, we present a case series evaluating the effectiveness of nasal closure in the management of severe transfusion-dependent epistaxis through a combination of patient reported and objective outcome measures.

## Materials and methods

This is a retrospective case series of patients undergoing nasal closure for epistaxis secondary to HHT.

### Patient selection

Patients who underwent nasal closure between 2020 and 2022 were identified from our cohort of HHT patients under follow up via their electronic medical records. All patients gave informed consent for participation in the study, and all patient data were anonymised. All identified were eligible for inclusion.

### Outcomes

Patients were contacted and asked about the frequency of blood transfusion since they underwent nasal closure; this was compared with clinic documentation of pre-operative blood transfusion. Haemoglobin concentration pre-operatively and 3, 6 and 12 months post-operatively was collected from hospital and primary care records.

Pre-operative and post-operative Epistaxis Severity Score (ESS) scores (Appendix 1) were ascertained from clinic documentation or via telephone call. Finally, patients were asked to complete a Glasgow Benefit Inventory (GBI) to evaluate the change in quality of life post-operatively (Appendix 2).

### Statistical analysis

Paired *t*-tests were performed on the pre- versus post-operative ESS data using a *p* value less than 0.05 to indicate statistical significance.

### Surgical technique

Modified nasal closure is performed by making a circumferential incision at the mucocutaneous junction and raising three retrograde flaps. Meticulous care is taken to avoid provoking epistaxis. The nasal vestibule is then closed by joining these flaps with absorbable suture (Figure 2).

## Results and analysis

Five patients underwent nasal closure at our centre between 2020 and 2023.

The cohort consisted of two women and three men aged between 44 and 76 years at the time of interview. Patients were generally co-morbid (Table 1): two patients had severe pulmonary hypertension and three had severe cardiovascular co-morbidity with history of thromboembolic events. These co-morbidities contraindicated the use of bevacizumab in all patients. The follow-up period ranged from 14 to 34 months.

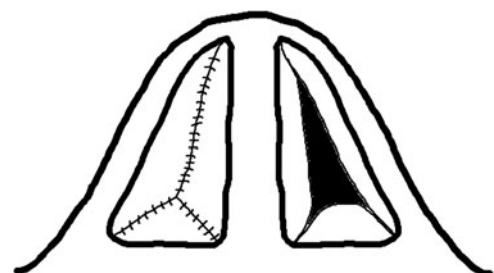


Figure 2. Modified young's procedure technique; patient's left nostril has the three mucocutaneous flaps being raised; the patient's right nostril is closed.

**Table 1.** Individual patient descriptions

Patient no. Age (years)/sex	Previous treatment	Indication	Co-morbidities	Hb		ESS		GBI
				Pre-	Post-	Pre-	Post-	
1 72/M	Young's early 2000s, reversal of left nostril closure in Feb 2020 (poor sleep).	Subsequent heavy epistaxis requiring weekly transfusion, transfusion reactions; reclosure April 2020.	TAVI/pacemaker for severe congenital aortic stenosis, mitral regurgitation, 50% left ventricular ejection fraction; ischaemic heart disease, essential hypertension, hepatocellular carcinoma (surveillance)	68	137	10	0	83
2 65/M	Multiple KTP lasers, optimal medical management. Large septal perforation from repeated ablative procedures.	Monthly transfusions.	Severe pulmonary hypertension, hepatic arteriovenous malformations	79	151	6	0	47
3 76/M	Multiple KTP lasers, optimal medical management.	Twice monthly transfusions, severe cardiovascular co-morbidity worsened by anaemia.	Ischaemic heart disease, 2 previous myocardial infarctions treated with percutaneous coronary interventions, atrial fibrillation, several previous transient ischaemic attacks, hypertension, chronic obstructive pulmonary disease	86	145	10	2	44
4 68/F	Multiple KTP lasers, optimal medical management.	Monthly iron and blood transfusion.	Hepatic arteriovenous malformations, atrial fibrillation, cerebrovascular event	76	106	6	0	78
5 44/F	Multiple KTP lasers, bilateral sphenopalatine artery ligations, optimal medical management.	Severe pulmonary hypertension worsened by anaemia, high risk general anaesthetic; closure as a definitive procedure to avoid worsening co-morbidities and avoid repeat general anaesthetics for laser procedures.	Severe pulmonary hypertension	79	104	7	0	-6

ESS = Epistaxis Severity Score; GBI = Glasgow Benefit Inventory; Hb = haemoglobin; KTP = potassium titanyl phosphate.

The indication for surgery in all cases was severe transfusion-dependent refractory epistaxis. In addition, one case (patient 5) was performed as a definitive procedure to prevent epistaxis-related anaemia from worsening severe pulmonary hypertension. This procedure was performed at a specialist centre with intensive care support.

Four patients underwent bilateral nasal closure. One patient had re-closure of one nostril performed following a left unilateral Young's reversal procedure two months prior. After re-opening of the nostril, this patient suffered severe epistaxis requiring weekly transfusion and developed transfusion reactions, hence, the re-closure two months later.

Mean haemoglobin concentration pre-operatively was 81 mg/dl<sup>3</sup> (range 68–96); between 6 and 12 months post-operatively, it was 128.2 mg/dl<sup>3</sup> (range 102–151) (Figure 3). All patients demonstrated an increase in their haemoglobin concentration post-operatively, with a mean increment of 47.2 mg/dl<sup>3</sup>. The post-operative haemoglobin data were incomplete for one patient due to retrospective collection.

The majority of patients required at least once-monthly blood transfusions pre-operatively with a mean of 1.8

transfusions per month. No patients required a blood transfusion for anaemia secondary to epistaxis at any point post-operatively. Two patients required admission and blood transfusion after nasal closure due to bleeding from gastrointestinal arterio-venous malformations.

All patients had a reduction in ESS. The mean ESS prior to surgery was 7.8 (range 6–10); the mean after surgery was 0.4 (range 0–2). The mean reduction in ESS was 7.4. These findings demonstrated a statistically significant reduction in ESS post-operatively (paired *t*-test; *t* = -9.89, *p* = 0.0006). Four of five patients reported an ESS of 0 post-operatively, representing complete cessation of epistaxis for these patients.

The GBI is calculated from 18 questions and represents health-related quality of life. Scores range between -100 (maximum negative) and +100 (maximum positive). The mean GBI was +49.2 (range -6–83) with four of five patients returning positive GBI scores. One patient returned a weakly negative GBI of -6.

Three of nine closed nostrils developed unilateral pinhole defects which required re-closure (Figure 4). Two were re-closed operatively 7 and 9 months after the initial

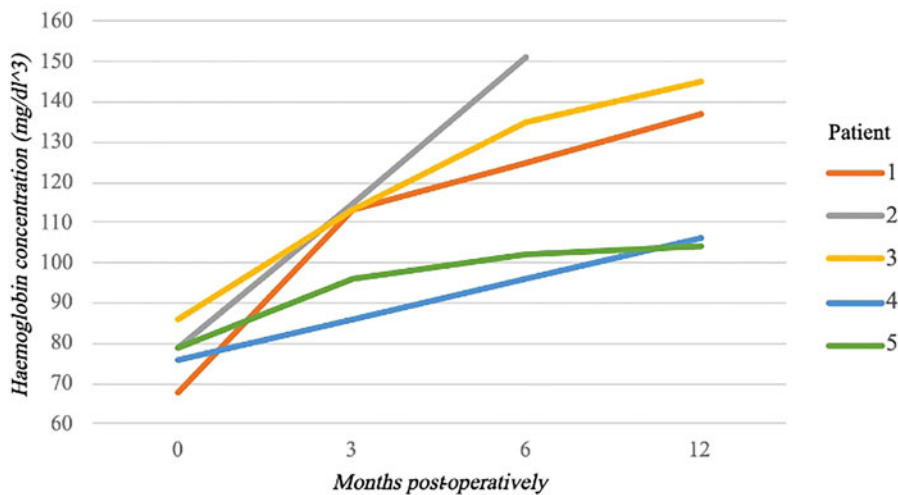


Figure 3. Individual post-operative haemoglobin trends.

operation. One used petroleum jelly to close the pinhole to good effect. Operations were otherwise uncomplicated.

## Discussion

Our results demonstrate that nasal closure appears to be a safe and effective management option for severe refractory epistaxis in HHT. This is a particularly important consideration in patients for whom bevacizumab is contraindicated. Additionally, the exact efficacy of bevacizumab remains difficult to determine in the long term.

We found that nasal closure was effective in reducing the frequency and severity of epistaxis in patients with HHT, as well as in increasing haemoglobin concentrations and reducing the need for blood transfusions. Patients generally reported an improved health-related quality of life post-operatively. These findings support the use of nasal closure as an effective management option for HHT patients with transfusion-dependent epistaxis refractory to optimal medical and surgical management, whose co-morbidities contraindicate the use of bevacizumab.

In 2022, the European Reference Network for Rare Vascular Diseases (VASCERN) published guidelines on when and how to use bevacizumab for epistaxis in HHT. Contraindications include severe pulmonary hypertension (World Health Organisation [WHO] grade 2 and above) and severe arteriopathy<sup>12</sup>; all our patients therefore had contraindications for bevacizumab use. It is likely that many HHT patients, in whom there is high cardiorespiratory co-morbidity,<sup>24</sup> will similarly have contraindications to bevacizumab. Nonetheless, we would advocate for modified nasal closure being considered for all patients

with transfusion-dependent epistaxis, particularly those whose co-morbidity contraindicates bevacizumab. Furthermore, given the relatively short-term impact of bevacizumab displayed in the existing literature, we would support the use of a shared decision-making approach, counselling the patient on the pros and cons of both treatments.

Our use of patient reported outcome measures ensured a direct and unbiased measure of the patient's real-world experience after surgery.<sup>25</sup> The GBI is a validated patient reported outcome measure which is widely used in research evaluating otorhinolaryngological interventions.<sup>26</sup> Four of five of our participants returned significantly positive GBI scores, with an average score of +49.2. These findings imply that, for our patients, nasal closure has a higher level of patient satisfaction (according to mean GBI score) when compared to other common ear/nose/throat (ENT) procedures, such as cochlear implant (+38.4), stapes surgery (+29.9), tonsillectomy (+27.0) or vestibular schwannoma surgery (-4.8).<sup>27</sup>

The one patient with limited improvement in GBI score, patient 5, presented a complex case. Although her epistaxis was less profuse, she had severe pulmonary hypertension exacerbated by anaemia secondary to epistaxis. Nasal closure was therefore recommended to address the anaemia. This operation was successfully performed at a tertiary centre with specialist intensive care support, and the patient has since maintained her haemoglobin levels and had no further epistaxis.

The ESS is a validated tool which provides a standardised and objective way to measure the severity of epistaxis.<sup>28</sup> In our cohort, ESS was reduced in all patients by a statistically significant average of 7.4 out of a possible 10 points. This reduction is also clinically significant, as it exceeds the minimal clinically important difference in ESS, which has been determined to be 0.71.<sup>29</sup>

The decision for nasal closure should involve careful consideration by both patient and clinician. Although the procedure has the potential to dramatically improve and potentially stop epistaxis, it results in the inevitable consequence of oblige mouth-breathing and impairment of taste and smell. It is therefore imperative to provide robust pre-operative counselling to patients, with the decision for surgery taking place over multiple clinic contacts. We are fortunate to have three patients who volunteer to speak with prospective surgical candidates, answering questions and addressing misconceptions. This ensures patients are thoroughly well-informed prior to consenting and adequately prepared for the physical consequences post-operatively.

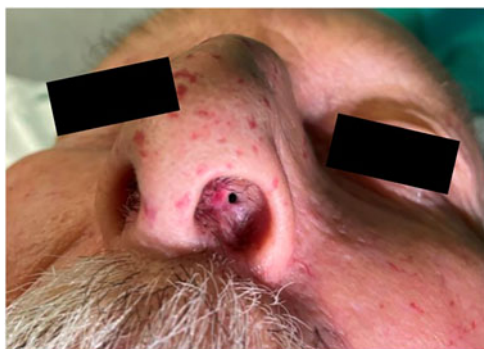

Figure 4. Pinhole reopening.



The study is limited by its small size, retrospective design and consequent incomplete data on haemoglobin trends for one patient. We used several outcome measures, both subjective and objective, to offset this limitation and provide a comprehensive evaluation on the impact of nasal closure for our patients.

- Modified nasal closure is an effective option for the management of refractory transfusion-dependent epistaxis in patients with HHT.
- For patients with transfusion-dependent epistaxis secondary to HHT, particularly those whose co-morbidities contraindicate bevacizumab, nasal closure should be considered as a definitive treatment option.
- While recent studies highlight the efficacy of bevacizumab in this subgroup, the exact efficacy of bevacizumab remains difficult to determine in the long term.
- There remains to be a lack of controlled evidence regarding the use of nasal closure for refractory epistaxis in HHT, and larger controlled studies assessing long-term outcomes are required.

There remains to be a lack of controlled evidence regarding the use of nasal closure for refractory epistaxis in HHT, although all cohorts appear to have similar positive findings. This paucity of quality evidence would be addressed with larger controlled studies assessing long-term outcomes.

## Conclusions

In conclusion, this study provides evidence that modified nasal closure is an effective option for the management of refractory transfusion-dependent epistaxis in patients with HHT. We found an improvement in quality of life, incremented haemoglobin concentrations and reduced transfusion requirement in patients post-operatively. For all patients with severe transfusion-dependent epistaxis secondary to HHT, particularly those whose co-morbidities contraindicate bevacizumab, nasal closure should be considered as a definitive treatment option. Further research is required to confirm these findings and to evaluate the long-term outcomes of this procedure.

**Acknowledgements.** We thank all patients included in the study, particularly those who are generous enough with their time to talk with potential surgical candidates.

**Conflicting interests.** None to declare.

**Funding.** None to declare.

**Ethical statement.** This retrospective chart review study involving human participants was in accordance with the ethical standards of the institutional and national research committee and with the 1964 Helsinki Declaration and its later amendments or comparable ethical standards.

**Authorship contribution.** Robert Bickerton: methodology, data acquisition and analysis, writing - original draft and revisions. Benjamin Kennard: writing - review and editing. Nikita Mehtani: methodology. Elizabeth Bullock: methodology. Talisa Ross: writing - review and editing. Vikas Acharya: conceptualisation, methodology, writing - review and editing. Catherine Rennie: overall supervision, conceptualisation, writing - review and editing, final approval of article prior to submission.

## References

- 1 Shovlin CL, Buscarini E, Sabbà C, Mager HJ, Kjeldsen AD, Pagella F, *et al.* The European Rare Disease Network for HHT Frameworks for management of hereditary haemorrhagic telangiectasia in general and speciality care. *Eur J Med Genet* 2022;**65**:104370
- 2 McDonald J, Stevenson DA. *Hereditary Hemorrhagic Telangiectasia*. Seattle, Washington: University of Washington, 2021
- 3 Thalgott JH, Dos-Santos-Luis D, Hosman AE, Martin S, Lamandé N, Bracquart D, *et al.* Decreased expression of vascular endothelial growth

factor receptor 1 contributes to the pathogenesis of hereditary hemorrhagic telangiectasia type 2. *Circulation* 2018;**138**:2698–712

- 4 AAssar OS, Friedman CM, White RI Jr. The natural history of epistaxis in hereditary hemorrhagic telangiectasia. *Laryngoscope* 1991;**101**:977–80
- 5 McDonald J, Bayrak-Toydemir P, Pyeritz RE. Hereditary hemorrhagic telangiectasia: An overview of diagnosis, management, and pathogenesis. *Genet Med* 2011;**13**:607–16
- 6 McDonald J, Bayrak-Toydemir P, DeMille D, Wooderchak-Donahue W, Whitehead K. Curaçao diagnostic criteria for hereditary hemorrhagic telangiectasia is highly predictive of a pathogenic variant in ENG or ACVRL1 (HHT1 and HHT2). *Genet Med* 2020;**22**:1201–5
- 7 Whitehead KJ, Sautter NB, McWilliams JP, Chakinala MM, Merlo CA, Johnson MH, *et al.* Effect of topical intranasal therapy on epistaxis frequency in patients with hereditary hemorrhagic telangiectasia. *JAMA* 2016;**316**:943–51
- 8 Geithoff UW, Seyfert UT, Kübler M, Bieg B, Plinkert PK, König J. Treatment of epistaxis in hereditary hemorrhagic telangiectasia with tranexamic acid - A double-blind placebo-controlled cross-over phase IIIB study. *Thromb Res* 2014;**134**:565–71
- 9 Gaillard S, Dupuis-Girod S, Boutitie F, Rivière S, Morinière S, Hatron P-Y, *et al.* Tranexamic acid for epistaxis in hereditary hemorrhagic telangiectasia patients: A European cross-over controlled trial in a rare disease. *J Thromb Haemost* 2014;**12**:1494–502
- 10 Al-Samkari H, Kasthuri RS, Parambil JG, Albitar HA, Almodallal YA, Vázquez C, *et al.* An international, multicenter study of intravenous bevacizumab for bleeding in hereditary hemorrhagic telangiectasia: The InHIBIT-Bleed study. *Haematologica* 2020;**106**:2161–9
- 11 Chen H, Zhang Z, Chen X, Wang C, Chen M, Liao H, *et al.* Meta-analysis of efficacy and safety of bevacizumab in the treatment of hereditary hemorrhagic telangiectasia epistaxis. *Front Pharmacol* 2023;**14**:1089847
- 12 Dupuis-Girod S, Shovlin CL, Kjeldsen AD, Mager H-J, Sabba C, Droege F, *et al.* European Reference Network for Rare Vascular Diseases (VASCERN): When and how to use intravenous bevacizumab in Hereditary Haemorrhagic Telangiectasia (HHT)? *Eur J Med Genet* 2022;**65**:104575
- 13 Buscarini E, Botella LM, Geithoff U, Kjeldsen AD, Mager HJ, Pagella F, *et al.* Safety of thalidomide and bevacizumab in patients with hereditary hemorrhagic telangiectasia. *Orphanet J Rare Dis* 2019;**14**:28
- 14 Faughnan ME, Mager JJ, Hettis SW, Palda VA, Lang-Robertson K, Buscarini E, *et al.* Second International Guidelines for the Diagnosis and Management of Hereditary Hemorrhagic Telangiectasia. *Ann Intern Med* 2020;**173**:989–1001
- 15 Rimmer J, Lund VJ. A modified technique for septodermoplasty in hereditary hemorrhagic telangiectasia. *Laryngoscope* 2014;**124**:67–9
- 16 Young A. Closure of the nostrils in atrophic rhinitis. *J Laryngol Otol* 1967;**81**:515–24
- 17 Lund VJ, Howard DJ. Closure of the nasal cavities in the treatment of refractory hereditary haemorrhagic telangiectasia. *J Laryngol Otol* 1997;**111**:30–3
- 18 Gluckman JL, Portugal LG. Modified Young's procedure for refractory epistaxis due to hereditary hemorrhagic telangiectasia. *Laryngoscope* 1994;**104**:1174–7
- 19 Lund VJ, Darby Y, Rimmer J, Amin M, Husain S. Nasal closure for severe hereditary haemorrhagic telangiectasia in 100 patients. The Lund modification of the Young's procedure: A 22-year experience. *Rhinology* 2017;**55**:135–41
- 20 Thomson RS, Molin NL, Whitehead KJ, Ashby S, Johnson L, Ward PD, *et al.* The effects of nasal closure on quality of life in patients with hereditary hemorrhagic telangiectasia. *Laryngoscope Investig Otolaryngol* 2018;**3**:178–81
- 21 Andersen JH, Kjeldsen AD. Patient-recorded benefit from nasal closure in a Danish cohort of patients with hereditary haemorrhagic telangiectasia. *Eur Arch Otorhinolaryngol* 2020;**277**:791–800
- 22 Richer SL, Geithoff UW, Livada N, Ward PD, Johnson L, Mainka A, *et al.* The Young's procedure for severe epistaxis from hereditary hemorrhagic telangiectasia. *Am J Rhinol Allergy* 2012;**26**:401–4
- 23 Ichimura K, Kikuchi H, Imayoshi S, Yamauchi T, Ishikawa K. Are patients with severe epistaxis caused by hereditary hemorrhagic telangiectasia satisfied with nostril closure surgery? *Auris Nasus Larynx* 2012;**39**:59–64
- 24 Droege F, Thangavelu K, Stuck BA, Stang A, Lang S, Geithoff U. Life expectancy and comorbidities in patients with hereditary hemorrhagic telangiectasia. *Vasc Med* 2018;**23**:377–83

25 Nelson EC, Eftimovska E, Lind C, Hager A, Wasson JH, Lindblad S. Patient reported outcome measures in practice. *BMJ* 2015;**350**:7818

26 Kubba H, Swan IRC, Gatehouse S. The Glasgow Children's Benefit Inventory: A new instrument for assessing health-related benefit after an intervention. *Ann Otol Rhinol Laryngol* 2004;**113**:980-6

27 Hendry J, Chin A, Swan IRC, Akeroyd MA, Browdoing GG. The Glasgow Benefit Inventory: A systematic review of the use and value of an otorhinolaryngological generic patient-recorded outcome measure. *Clin Otolaryngol* 2016;**41**:259-75

28 Hoag JB, Terry P, Mitchell S, Reh D, Merlo CA. An epistaxis severity score for hereditary hemorrhagic telangiectasia. *Laryngoscope* 2010;**120**:838-43

29 Yin LX, Reh DD, Hoag JB, Mitchell SE, Mathai SC, Robinson GM, et al. The minimal important difference of the epistaxis severity score in hereditary hemorrhagic telangiectasia. *Laryngoscope* 2016;**126**:1029-32

**Appendix 1. Epistaxis Severity Score (ESS) and method for calculation**

Answer each question about your symptoms as they have occurred over the past three months.

1. How often do you TYPICALLY have nose bleeding?
2. How long does your TYPICAL nose bleeding last?
3. Would you describe your TYPICAL nose bleeding intensity as gushing or pouring?
4. Have you sought medical attention for your nose bleeding?
5. Are you anemic (low blood counts) currently?
6. Have you received a red blood cell transfusion SPECIFICALLY for nose bleeding?

Question	Response	Multiplied by:	Coefficient	Result
1	Less than monthly	0	x	0.14 (0.70 Den)
	Once per month	1		
	Once per week	2		
	Several per week	3		
	Once per day	4		
	Several per day	5		
2	< 1 minute	0	x	0.25 (1.00 Den)
	1-5 minutes	1		
	6-15 minutes	2		
	16-30 minutes	3		
	> 30 minutes	4		
3	No	0	x	0.25 (0.25 Den)
	Yes	1		
4	No	0	x	0.30 (0.30 Den)
	Yes	1		
5	No	0	x	0.20 (0.20 Den)
	Yes	1		
6	No	0	x	0.31 (0.31 Den)
	Yes	1		
TOTAL =			Denominator (Sum Den)	Raw Score

$$\text{Normalized HHT-ESS} = \left[ \frac{\text{Raw Score}}{\text{Denominator (2.71)}} \right] \times 10$$

## Appendix 2. Glasgow Benefit Inventory (GBI)

### Patient Questionnaire – Glasgow Benefit Inventory (GBI)

How to complete this Questionnaire:

- This questionnaire is designed to find out what sort of effects your recent operation (young's procedure) has had on your lifestyle, general well-being, etc.
- Some of the effects below may apply to you, some may not.
- Please answer all questions by selecting the number that best reflects how your nosebleeds and other related symptoms have affected you since your operation

Please Note: some of the questions are scored in reverse order (i.e. 5 to 1, rather than 1 to 5), so please read the statement and the scores carefully.

1= much worse      2= a little worse      3= no change      4= a little better      5= much better

Situation	Degree of Problem
Has the result of the operation affected the things you do?	1 2 3 4 5
Have the results of the operation made your overall life better or worse?	5 4 3 2 1
Since the operation, have you felt more or less optimistic about the future?	5 4 3 2 1
Since your operation, do you feel more or less embarrassed when with a group of people?	1 2 3 4 5
Since your operation, do you have more or less self-confidence?	5 4 3 2 1
Since your operation, have you found it easier or harder to deal with company?	5 4 3 2 1
Since your operation, do you feel that you have more or less support from your friends?	5 4 3 2 1
Have you been to your GP, for any reason, more or less often, since your operation?	1 2 3 4 5
Since your operation, do you feel more or less confident about job opportunities?	5 4 3 2 1
Since your operation, do you feel more or less self-conscious?	1 2 3 4 5
Since your operation, are the more or fewer people who really care about you?	5 4 3 2 1
Since you had the operation, do you catch colds or infections more or less often?	1 2 3 4 5
Have you had to take more or less medicine for any reason, since your operation?	1 2 3 4 5
Since your operation, do you feel better or worse about yourself?	5 4 3 2 1
Since your operation, do you feel that you've had more or less support from your family?	5 4 3 2 1
Since your operation, are you more or less inconvenienced by your health problem?	1 2 3 4 5
Since your operation, have you been able to participate in more or fewer social activities?	5 4 3 2 1
Since operation, have you been more or less inclined to withdraw from social situations?	1 2 3 4 5