

## Bilateral Symmetrical Brain Lesions in Tricyclic Antidepressant Overdosage

LAILA M. SABET

**SUMMARY:** *The cerebral pathology in a case of tricyclic antidepressant overdose by amitriptyline is described. A review of the literature of similar cases is summarized. The relation of the cerebral lesions to the development of a hypertensive episode possibly induced by amitriptyline is discussed.*

**RÉSUMÉ:** *Nous décrivons la pathologie cérébrale consécutive à un surdosage d'antidépresseur tricyclique (amitriptyline). Nous résumons les cas semblables glanés de la littérature. Nous discutons également de la relation possible entre les lésions cérébrales et le développement d'un épisode hypertensif peut-être dû à l'amitriptyline.*

The pathophysiological effects and clinical features of overdosage with tricyclic antidepressants have been described in detail (Moraguerra, 1977; Petit, 1977; Bilgi, 1979). However, published accounts of morphological changes in the brain are scarce and lacking in detail. We are not aware of a clear description of distinctive lesions occurring as a result of overdosage with those widely used drugs. Previously published cases of fatal tricyclic antidepressant overdose in which the brain has been examined are summarized in table 1. Recently we have studied at autopsy a patient with distinctive brain lesions which appear to have been the result of self-administered tricyclic antidepressant. This account is published so that others encountering such cases may establish if these are consistent findings.

### CLINICAL HISTORY

A 38 years old woman diagnosed as manic depressive psychosis, mainly depressive, of 6 years duration, was admitted to the hospital in coma. She had four previous admissions for depression, two of them precipitated by suicide attempts. On the day of admission, she was found by her husband lying on the bathroom floor unconscious. Beside her was an empty bottle of Etrafon F (amitriptyline) which was full (25 tablets) about two days previously. It was estimated that the patient had swallowed at least 14 tablets (a total amount of 350 mg amitriptyline and 56 mg perphenazine). On admission she responded only to painful stimuli. Her pupils were dilated and unequal. She had several convulsive seizures and atrioventricular dissociation with cardiac arrhythmias. She was mechanically ventilated. Table 2 illustrates the medications she was given, and her blood pressure records. She had two cardiac arrests, the second of which was irreversible. Death took place 38 hours after admission, approximately 43 hours after the ingestion of the antidepressant.

### Laboratory Investigations:

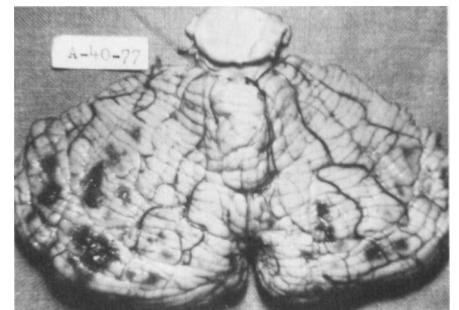
Blood samples taken during autopsy were analysed for the presence of various drugs including Etrafon F, as well as carbon monoxide and alcohol, but showed negative results (the test for the antidepressant was a crude one). Unfortunately, no tissue was sent for toxicology.

### Autopsy:

Marked venous congestion and interstitial hemorrhages were present in the lungs, liver, spleen, kidneys and stomach. The stomach showed superficial ulceration of the mucosa, with fragmentation of the mucosal glands and polymorphonuclear leukocytic infiltration. No other pathological changes were seen in any of the internal organs, and no evidence of vasculitis or disseminated intravascular thrombosis was found.

### Brain:

The brain was swollen. Several discrete blotchy areas of discoloration up to 1 cm in diameter were present on the dorsal and ventral aspects of the cerebellum bilaterally (Fig. 1).



**Figure 1** — Discrete hemorrhagic foci are seen on the dorsal aspect of the cerebellum bilaterally.

On section, scattered foci of necrosis were seen in the caudate nuclei and putamen bilaterally (Fig. 2). The globus pallidus showed hemorrhagic necrosis throughout most of its substance bilaterally.

From the Department of Pathology, St. Claire's Mercy Hospital, St. John's, Newfoundland.

Reprint requests to Dr. L. M. Sabet, Health Sciences Centre, Department of Pathology, London, Canada N6A 5C1.

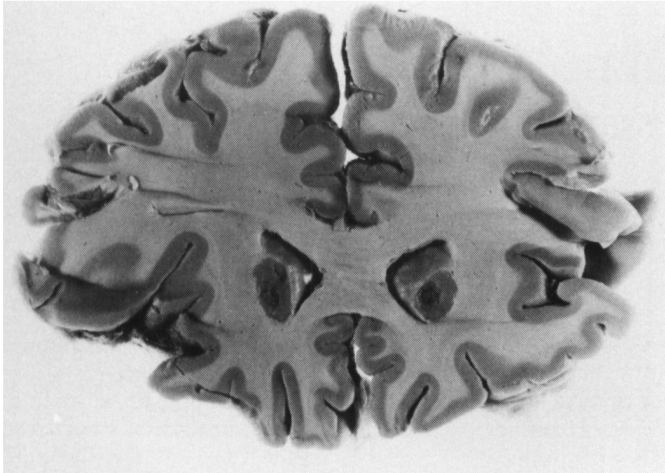


Figure 2 — Brain: foci of necrosis involve the right and left putamen.

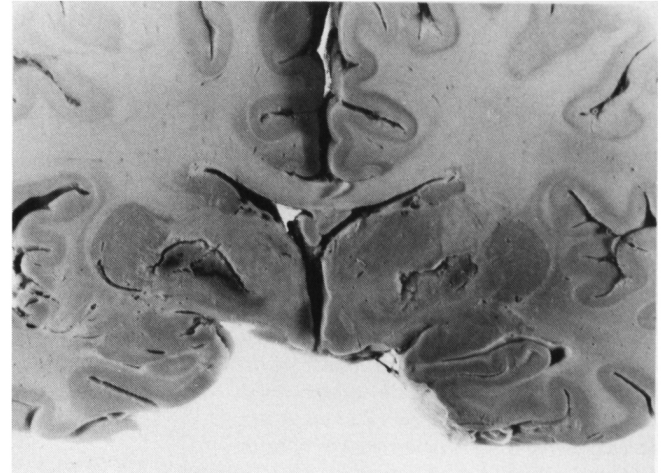


Figure 3 — Brain: necrosis and hemorrhage in the globus pallidus bilaterally.

(Fig. 3). The cerebral cortex, white matter, thalami, midbrain, pons and medulla appeared normal. The cerebellar lesions were confined to the superficial cortex.

Histologically, the lesions in the striatum and pallidum were confirmed as recent necrosis with varying degrees of hemorrhage. Cellular reaction was slight or absent. The cerebral blood vessels in and around the lesions showed no abnormality. The changes in the cerebellum were scattered

recent cortical hemorrhages. The hemorrhages were mostly superficial to the granular cell layer, appearing to split off the molecular layer. Purkinje cells in the vicinity of these hemorrhages showed acute anoxic changes. Elsewhere, they were normal. Sparse subarachnoid hemorrhage was present.

DISCUSSION

The microscopic features indicate that the brain lesions were recent

(absence of gliosis, astrocytosis, and lipid laden macrophages), and occurred during the patient's terminal illness. The lesions were unlike those usually seen in anoxic encephalopathy. There were no cerebral cortical or hippocampal lesions, and the cerebellar lesions were focal and not diffuse.

The cerebral lesions in this patient appear to have a distinctive pattern,

TABLE I  
*Cerebral Pathology in Tricyclic Antidepressant Poisoning Related to Dose and Period of Survival*

Author	Type of TCA*	Time between Ingestion & Death	Dosage	Cerebral Pathology
Edwards, 1966	Imipramine	3½ hrs.	625 mg	No significant gross abnormality.
Haqqani, 1974 Case I	Clomipramine Hcl	about 24 hrs.	234 capsules	Hyperemia of the meninges with slight cerebral edema.
	Clomipramine Hcl	24 hrs.	unknown	Localised degeneration of the brain related to former leucotomy.
Fatteh, 1968	Imipramine (Tofranil (R))	24 hrs.	875 mg	Neuronal degenerative changes in cerebral cortex with perivascular hemorrhage.
Williams, 1971	Amitriptyline	30 hrs.	1600 mg (1.6 gm)	Cerebral edema with many small subarachnoid hemorrhages.
Greenblatt, 1974	Protriptyline Hcl	**30 hrs. after admission	unknown	Cerebral edema.

\*Tricyclic Antidepressant

\*\*Ingestion occurred several hours before admission.

TABLE 2  
*Medication and Blood Pressure*

Time	Blood Pressure	Decadron	Other Medications
First day in hospital.			
Admission 1845 hr.	80 systolic.		
2000 hr.	90 systolic.		Antilirium 4 mg (physostigmine)
2300 hr.	80 systolic.	12 mg	Antilirium 4 mg (2 mg twice)
Second day 0300 hr.	90/75	4 mg	
0700 hr.	115/75	4 mg	
1100 hr.	175/105	4 mg	
1200 hr.	170/120		
1500 hr.	155/105	4 mg	
1900 hr.	160/100	4 mg	
2300 hr.	160/105	4 mg	Xylocaine 50 mg Sodium bicarbonate 1 ampoule
Third day 0300 hr.	130/80	4 mg	
0700 hr.	170/95	4 mg	
Death 0840 hr.			

A total of 3500 cc 5%\* D/S and 4500 cc 5%\*\* D/W were administered over the period in hospital.

\*Dextrose Saline  
\*\*Dextrose Water

with bilateral roughly symmetrical involvement of the caudate and lenticular nuclei. In distribution and character, they resembled carbon monoxide poisoning (Schwedenberg, 1959), although the anoxic changes which accompany the latter were absent.

It appears that the cerebral lesions were related to the amitriptyline overdose although their pathogenesis cannot be explained. None of the medications given to the patient in the hospital (table 2) is known to produce these changes. Cerebral changes associated with tricyclic antidepressants have been described (table 1), although they were not of the same magnitude as in the present case. One is tempted to

suggest that the severity of the cerebral lesions could be related to the period of survival between the ingestion of the drug and the occurrence of death. The longer the period the more the pathological changes are likely to become apparent grossly. Our case had the longest survival (43 hrs.) compared to the cases listed in table 1. Another interesting observation was the development of a hypertensive episode in the patient (table 2) several hours after the ingestion of the amitriptyline. The patient had been normotensive prior to the terminal event. Although hypertension is not a common complication of tricyclic antidepressants, it has been described in the literature (Noble and Matthew,

1969; Hesso, 1971). Whether this hypertensive episode contributed to the cerebral pathology needs further investigations.

Although the presence of amitriptyline in the blood was not documented the circumstantial evidence and the clinical picture strongly suggest that she had an overdose of amitriptyline.

Further detailed brain examinations on patients dying from tricyclic antidepressant overdose may reveal whether these findings are consistent.

#### ACKNOWLEDGEMENTS

I wish to express my gratitude to Dr. G. Matheson, Professor of neuropathology, Memorial University of Newfoundland, for his valuable help in reviewing the text, and to Mrs. Judy Thomas for typing the manuscript.

#### REFERENCES

- BILGI, C., CAMPBELL, R. (1979). Cardiovascular effects of tricyclic and tetracyclic antidepressants. *Can. Fam. Physician*, 25, 619-625.
- EDWARDS, J. (1966). Fatal imipramine overdosage. *Med. J. Aust.*, 1, 839-840.
- FATTEH, A., BLANKE, R., MANN, G. (1968). Death from imipramine poisoning. *J. Forensic Sci.*, 13, 124-128.
- GREENBLATT, D.J. et al (1974). Multiple complications and death following protriptyline overdose. *JAMA*, 229, 556-557.
- HAQQANI, M.T., GUTTERIDGE, D.R. (1974). Two cases of clomipramine hydrochloride (Anafranil) poisoning. *Forensic Sci.*, 3(1), 83-87.
- HESSOV, I. (1971). Hypertension during clomipramine therapy. *Br. Med. J.*, 1, 406.
- MAROGUERRA, A.S. (1977). Poisoning with tricyclic antidepressant drugs. *Clin. Toxicol.*, 10(2), 149-158.
- NOBLE, J., MATTHEW, H. (1969). Acute poisoning by tricyclic antidepressants. *Clin. Toxicol.*, 2, 403-421.
- PETIT, J.M. et al (1977). Tricyclic antidepressant plasma levels and adverse effects after overdose. *Clin. Pharm. Ther.*, 21(1), 47-51.
- SCHWEDENBERG, T.H. (1959). Leukoencephalopathy following carbon monoxide asphyxia. *J. Neuropath. & Experim. Neurol.*, 18, 597-608.
- WILLIAMS, R.B., SHERTER, C. (1971). Cardiac complications of tricyclic antidepressant therapy. *Ann. Intern. Med.*, 74, 395-398.