

# Cardiology in the Young

*Cardiology in the Young*  
46<sup>th</sup> Annual Meeting of the Association for  
European Paediatric and Congenital Cardiology, AEPC  
with joint sessions  
with the Japanese Society of Pediatric Cardiology  
and Cardiac Surgery  
Istanbul, Turkey, May 23–26, 2012



**Supplement Editor:**  
Alpay Celiker  
Acibadem University,  
Istanbul, Turkey

Submit your paper online  
<http://mc.manuscriptcentral.com/cty>

**CAMBRIDGE**  
UNIVERSITY PRESS

# Cardiology in the Young

journals.cambridge.org/CTY

## Editor-in-Chief

Professor Edward J. Baker

Oxford Radcliffe Hospitals NHS Trust, John Radcliffe Hospital, Headington, Oxford, OX3 9DU, UK

## Emeritus Founding Editors

Dr G. William Henry

Chapel Hill, USA

Professor Robert H. Anderson

University College, London, UK

## Associate Editors

Allen D. Everett, Baltimore, MD

Jeffrey P. Jacobs, St Petersburg, FL

## International Editor

Professor Hiromi Kurosawa, Tokyo Women's Medical University, Japan

## Supplements Editor

Jeffrey P. Jacobs, St Petersburg, FL

## Images Editor

Roxane McKay, Memphis, TN

## Founding Editors

Anton E. Becker, Amsterdam; Giancarlo Crupi, Bergamo; Arthur Garson Jr, Charlottesville, VA; Fernando Lucchese, Porto Alegre; Lucio Parenzan, Bergamo; the late Atsuyoshi Takao, Tokyo; Michael Tynan, London

## International Editorial Board

Lindsey D. Allan (London)

Maurice Beghetti (Geneva)

Lee N. Benson (Toronto)

Per G. Bjørnstad (Oslo)

Anthony C. Chang (Orange, CA)

David Cooper (Cincinnati, OH)

Tjark Ebels (Groningen)

Timothy Feltes (Columbus, OH)

J. William Gaynor (Philadelphia, PA)

Allan Goldman (London)

Willem A. Helbing (Rotterdam)

John Hess (Munich)

Eero Jokinen (Helsinki)

Tom Karl (Brisbane)

Doff B. McElhinney (Boston, MA)

Luc Mertens (Toronto)

Cleonice de C. Mota (Belo Horizonte)

Jane Newburger (Boston, MA)

Edgardo E. Ortiz (Quezon City)

Daniel Penny (Melbourne)

Andrew N. Redington (Toronto)

Girish S. Shirali (Charleston, SC)

Norman H. Silverman (Palo Alto, CA)

Giovanni Stellin (Padova)

András Szatmári (Budapest)

Hideki Uemura (London)

Steven A. Webber (Pittsburgh, PA)

James L. Wilkinson (Melbourne)

Shi-Joon Yoo (Toronto)

*Cardiology in the Young* is indexed and abstracted in Index Medicus/MEDLINE; Current Contents/Clinical Medicine; Research Alert; Sci Search; EMBASE/Excerpta Medica

**Commissioning Editor:** Dan Edwards

**Production Editor:** Nicki Marshall

**Design and Production:** MPS Limited, Bangalore

**Printed & Bound:** Latimer Trend, Plymouth

Published by Cambridge University Press (Journals), Edinburgh Building, Shaftesbury Road, Cambridge CB2 8RU, UK  
Tel: +44 (0)1223 326491; Fax: +44 (0)1223 325802; E-mail: dedwards@cambridge.org

## Cambridge Journals Online

For further information about this journal please go to the journal website at:

[journals.cambridge.org/CTY](http://journals.cambridge.org/CTY)



**CAMBRIDGE**  
UNIVERSITY PRESS

# The Organising Committee

## Scientific Committee (AEPC Council)

### President

Shakeel Qureshi

### Secretary – General

Katarina Hanséus

### Scientific Secretary

Joseph de Giovanni

### Treasurer

Jörg-Ingolf Stein

### Councillors

Juan V. Comas

Konrad Brockmeier

Sylvie Di Filippo

Georgia Sarquella Brugada

## JSPCCS Organising Committee

Dr. Toshio Nakanishi

President of the JSPCCS

Professor and Chief of Pediatric Cardiology Heart Inst. Women's Medical University Tokyo, Tokyo, Japan

Dr Koichiro Niwa

Department of Cardiology, St. Luke's International Hospital, Tokyo, Japan

Dr. Isao Shiraishi

Pediatric Cardiology, National Cerebral and Cardiovascular Center

Dr. Motoyoshi Kawataki

Department of Neonatology, Kanagawa Children's Hospital, Kanagawa, Japan

Dr. Toshihide Nakano

Department of Cardiovascular Surgery, Fukuoka Children's Hospital, Fukuoka, Japan

## Local Organising Committee

### Chairman

Alpay Çeliker

### Members

Sema Özer

Rukiye Eker Ömeroğlu

Nazmi Narin

Deniz Oğuz

Adnan Uysalel

Süleyman Özkan

## Congress Secretariat

### Opening Hours

Wednesday	23.05.2012	07:30–18:30
Thursday	24.05.2012	07:30–18:30
Friday	25.05.2012	07:30–18:30
Saturday	26.05.2012	08:00–14:00

## **PCO**

### **SERENAS INTERNATIONAL TOURISM CONGRESS ORGANIZATION SERVICES**

Mrs. Ebru Mumcuođlu  
Pakdil Sok. No:5 Yukarı Dudullu, Ümraniye, 34775  
Istanbul - Turkey  
E-mail info@aepc2012.org  
URL: www.serenas.com.tr

## **Venue**

HARBIYE MILITARY MUSEUM AND CULTURAL CENTER  
Address: Askerî Müze ve Kültür Sitesi Komutanlığı Harbiye- Şişli, Istanbul/Turkey  
Phone: +90 (212) 233 27 20

## **Sponsors and Exhibitors**

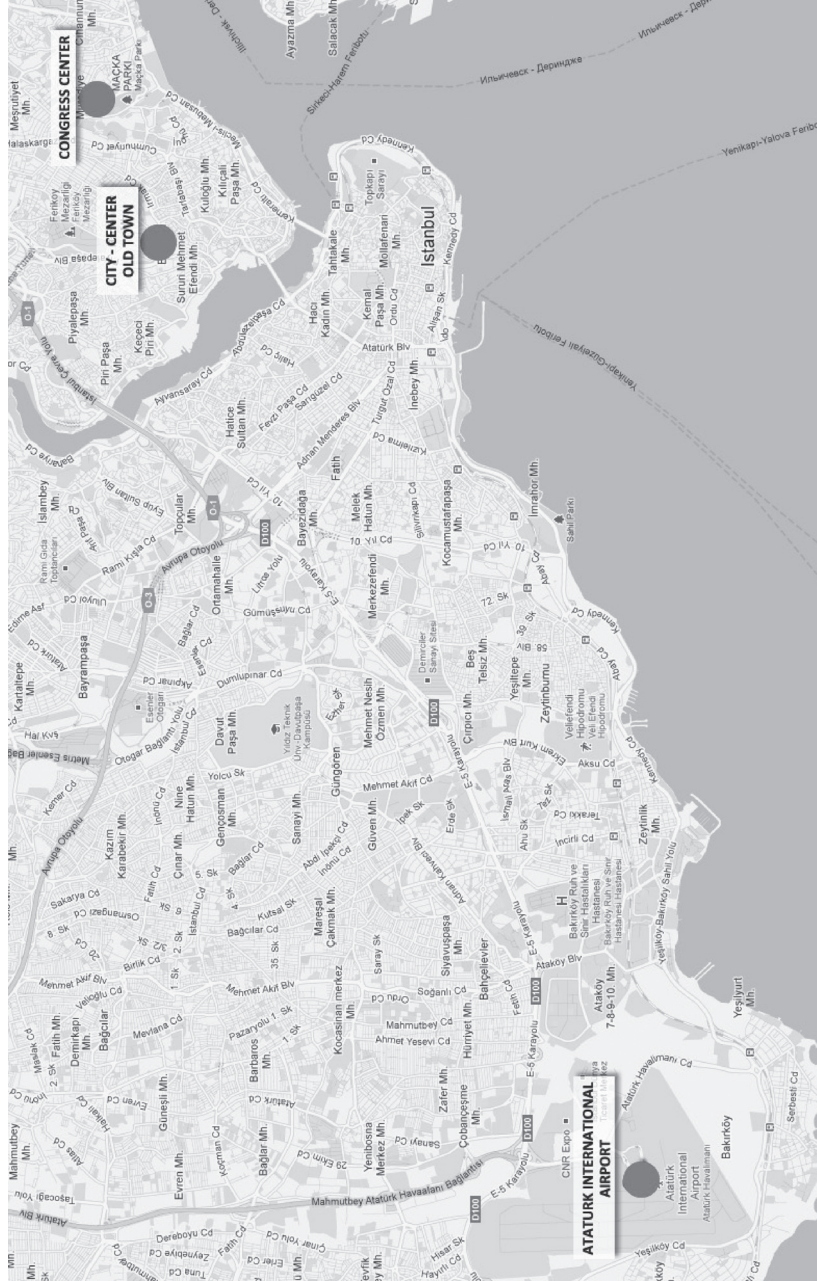The AEPC would like to give special thanks to all Sponsors and Exhibitors of the 46th Annual Meeting.

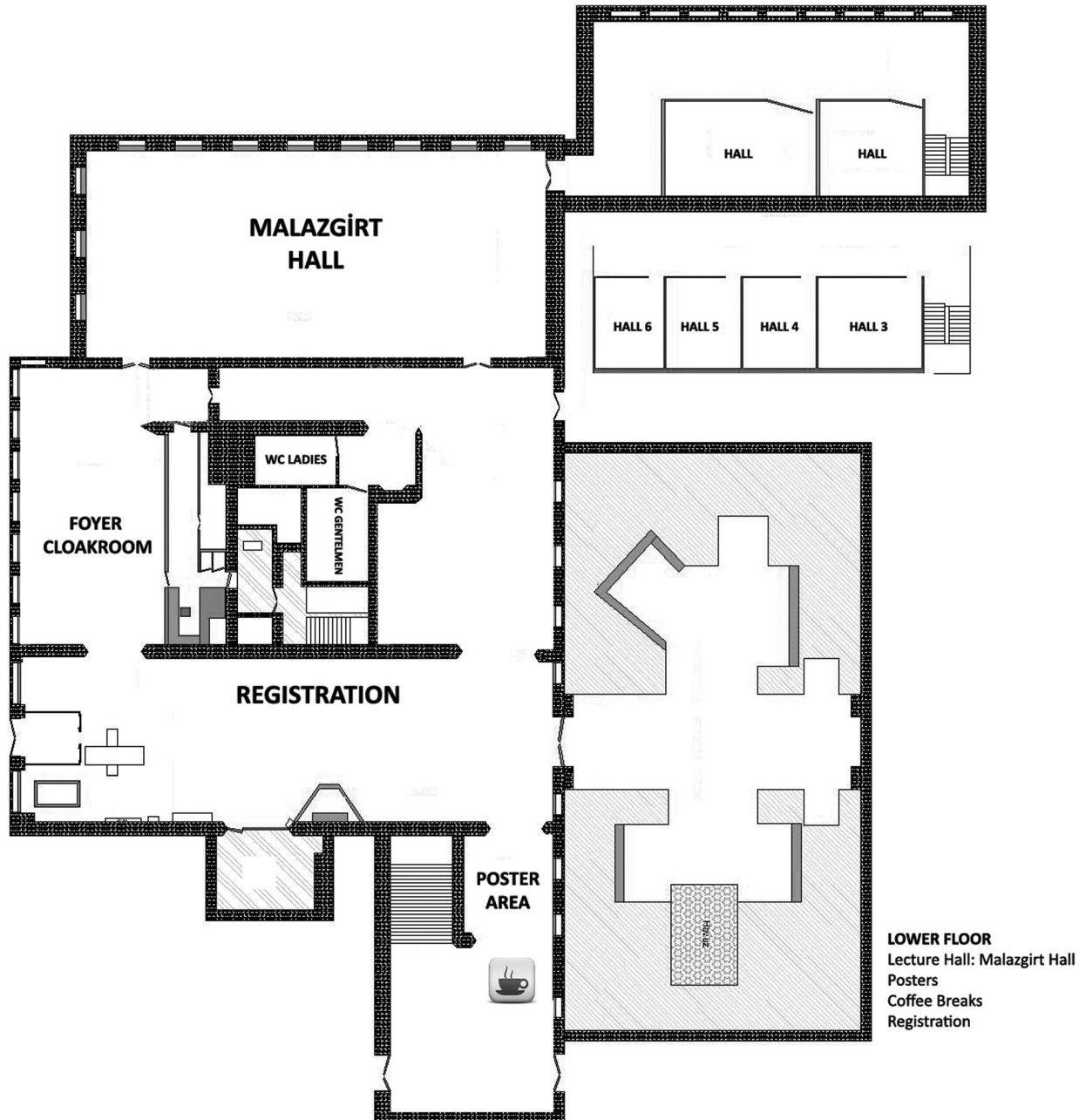
MEDTRONIC GLOBAL  
ACTELION PHARMACEUTICALS  
EDWARDS LIFESCIENCES  
ABBOTT GLOBAL  
BAYER SCHERING  
PFM MEDICAL  
SIEMENS AG  
AGA (ST. JUDE)  
GORE (W.L. GORE) CREATIVE TECH.  
GE MEDICAL  
OSYPKA  
HEART MEDICAL EUROPE BV (ON BEHALF OF NUMED DISTRIBUTOR MEDISIS)  
MEDINTEK  
CIRCLE CARDIOVASCULAR IMAGING B.V.  
PFIZER  
VENTRIPPOINT  
MEDTRONIC SURGICAL DEPARTMENT  
VENART BIOINTEGRAL SURGICAL  
PARVULUS SUISSE SA

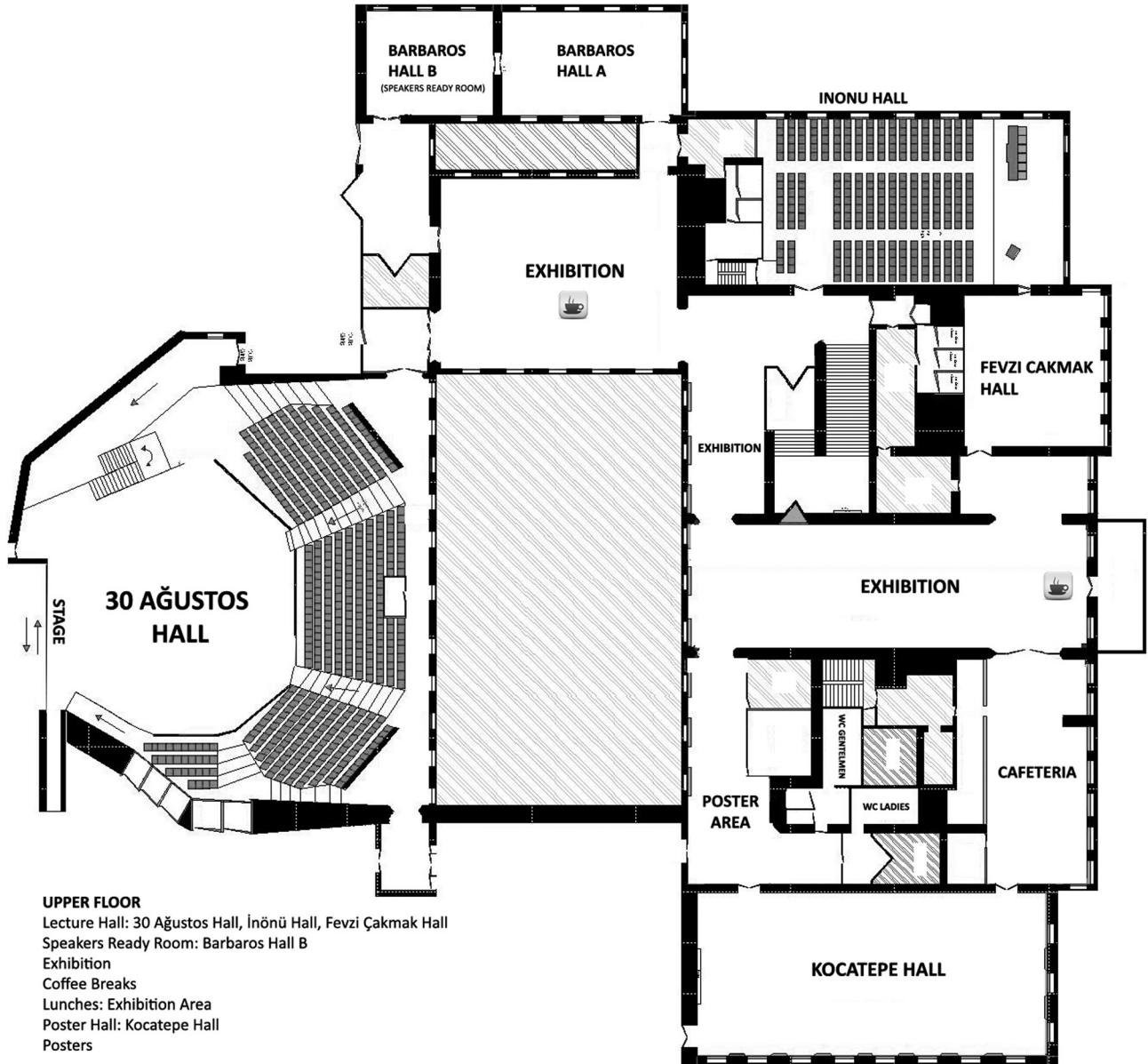
Distance from major hotels  
0-1 km (5-10 minutes walking distance)

Distance from city centre  
located in the city centre

Distance from airport  
30 km (30 minutes from city centre by car, taxi)







# Agenda

## AEPC Business Meeting Istanbul

Thursday, May 24, 2011

1. Welcome Address by the President (Shak Qureshi)
2. Obituary
3. Report of the President (Shak Qureshi)
4. Report of the Secretary-General (K. Hanseus)
5. Report of the Scientific Secretary (J. deGiovanni)
6. Report of the Treasurer (J. Stein)
7. News from the Working groups
  - Coding Committee (R. Franklin)
  - Cardiac Dysrhythmia and Electrophysiology (N. Blom)
  - Fetal Cardiology (J. Carlos Areias)
  - Genetics and Basic Science of Congenital Heart Defects (Matthias Gorenflo)
  - Paediatric Cardiovascular Intensive Care (E. Lechner)
  - Cardiac Imaging (J. Marek)
  - Interventional Cardiology (G. Butera)
  - Cardiovascular Morphology (A. Angelini)
  - Congenital Heart Surgery (B. Maruszewski)
  - Psycho-Social Care from Fetus to Adult (F. Casey)
  - GUCH Task Force (A. Szatmari)
  - Preventive Cardiology (E. Jokinen)
  - Junior members (B. Bonello)
8. Report from the Advisory Board/National delegates (K. Hanseus)
9. Introduction of New Members (K. Hanseus)
10. Election of President-Elect (K. Hanseus)
11. Replacement of Council members
12. World Congress of Paediatric Cardiology and Cardiac Surgery, Cape Town, 2013 (C. Hugo-Hamman)
13. Future Meetings (K. Hanseus)
  - 2013 London
  - 2014 Helsinki
  - 2015 Prague (Czech Republic), Rome (Italy) or the Island of Kos (Greece)
14. Other business?



23 MAY, 2012

PROGRAMME AT A GLANCE

30 AGUSTOS HALL

08:30 - 10:15  
Update Course:  
Fetal Cardiology

10:45 - 12:30  
Update Course:  
Fetal Cardiology

13:45 - 15:30  
Update Course:  
Fetal Cardiology

16:00 - 18:00  
Opening Ceremony  
and Mannheim  
Lecture

18:00 - 20:00  
Welcome reception

INONU HALL

10:00 - 13:00  
Scientific Advisory  
Committee

14:00-16:00  
Coding Committee

FEVZI CAKMAK HALL

09:00 - 12:30  
National Delegates  
Meeting

14:00-16:00  
Professional Advisory  
Committee

24 MAY, 2012

PROGRAMME AT A GLANCE

KOCATEPE HALL

HALL 1

MALAZGIRT HALL 2

MALAZGIRT HALL 1

FEVZI CAKMAK HALL

INONU HALL

30 AGUSTOS HALL

<p><b>08:00-09:00</b> WG Business Meeting: Cardiac Imaging</p>	<p><b>08:00-09:00</b> WG Business Meeting: Cardiac Dysrhythmia and Electrophysiology</p>	<p><b>08:00-09:00</b> WG Business Meeting: Cardiovascular Morphology</p>	<p><b>08:00-09:00</b> WG Business Meeting: Fetal Cardiology</p>	<p><b>08:00-09:00</b> WG Business Meeting: Paediatric cardiovascular Intensive care</p>	<p><b>08:00-09:00</b> WG Business Meeting: Prevention</p>
<p><b>09:00-10:30</b> Plenary Session: Emerging management strategies for neonatal cardiac emergencies</p>		<p><b>10:30-11:30</b> Mechanical Circulatory Support in Children</p>	<p><b>11:30-13:00</b> Abstract Session 2 Basic Science/Genetics</p>		
<p><b>11:30-13:00</b> Cardiac imaging in evolution</p>	<p><b>11:30-13:00</b> Arrhythmia in postoperative congenital heart disease</p>	<p><b>11:30-13:00</b> Abstract Session 1 Intervention I</p>			
<p><b>13:10-14:20</b> INDUSTRY SYMPOSIUM</p>		<p><b>13:10-14:20</b> INDUSTRY SYMPOSIUM</p>			
<p><b>14:30-16:00</b> Pediatric pulmonary hypertension present and future</p>	<p><b>14:30-16:00</b> Fetal heterotaxy- new aspects on embryology, morphology, prenatal diagnosis</p>	<p><b>14:30-16:00</b> Abstract Session 3 Dysrhythmia/ electrophysiology</p>	<p><b>14:30-16:00</b> Anatomic exhibition 1: Hands on session</p>		
<p><b>16:30-18:00</b> Joint Session: WG Dysrhythmia, Basic Science and Morphology</p>	<p><b>16:30-18:00</b> Abstract Session 4 Surgery and Intensive Care</p>	<p><b>16:30-18:00</b> Joint Session: WG Physiosocial and GUCH Task Force</p>			
<p><b>18:00-20:30</b> AEPC Business Meeting</p>					

**10:30-11:30**  
Poster Walk 1

**10:30-11:30**  
Poster Walk 2

PROGRAMME AT A GLANCE

25 MAY, 2012

KOCATEPE HALL

MALAZGIRT HALL 2

MALAZGIRT HALL 1

FEVZI CAKMAK HALL

INONU HALL

30 AGUSTOS HALL

<p><b>08:00-09:00</b> WG Business Meeting: GUCH Task Force</p>	<p><b>09:00-10:30</b> JSPCCS/AEPC session: Persistent Arterial Trunk</p>	<p><b>07:30-09:00</b> WG Business Meeting: Interventional Cardiology</p>	<p><b>09:00-10:30</b> Intensive Care Group Meeting</p>	<p><b>08:00-09:00</b> WG Business Meeting: Psycho-Social Care from Fetus to Adult</p>	<p><b>09:00-10:30</b> WG Fetal-Puzzle the experts</p>	<p><b>08:00-09:00</b> WG Business Meeting: Genetics and Basic Science</p>	<p><b>09:00-10:30</b> Abstract Session 5 General Cardiology I</p>	<p><b>08:00-09:00</b> WG Business Meeting: Congenital Heart Surgery</p>	<p><b>10:30-11:30</b> Poster Walk 3</p>	<p><b>10:30-11:30</b> Poster Walk 4</p>
<p><b>11:30-13:00</b> Young Investigator Award</p>	<p><b>13:10-14:20</b> INDUSTRY SYMPOSIUM</p>	<p><b>11:30-13:00</b> Joint Session: WG Intervention and GUCH Task Force- VSD in adulthood in all its aspects</p>	<p><b>10:30-11:30</b> Management of PAH in the intensive care</p>	<p><b>11:30-13:00</b> Joint Session: WG Genetics and Basic Science- Hypertrophic Cardiomyopathy</p>	<p><b>13:00-14:00</b> Junior Meeting</p>	<p><b>14:30-16:00</b> Anatomic exhibition 2: Workshop on Fetal Cardiovascular Anatomy</p>	<p><b>14:30-16:00</b> Abstract Session 7 Fetal</p>	<p><b>16:30-18:00</b> Abstract Session 9 General Cardiology II</p>	<p><b>18:00-20:00</b> SECPCC Business Meeting</p>	
<p><b>14:30-16:00</b> AEP/EAFTS session: Controversies in Coarctation Management</p>	<p><b>16:30-18:00</b> WG Prevention: Why do we need prevention?</p>	<p><b>14:30-16:00</b> Abstract Session 6 Imaging</p>	<p><b>16:30-18:00</b> Abstract Session 8 Intervention II</p>	<p><b>18:00-20:00</b> TCPCCS Business Meeting</p>						

PROGRAMME AT A GLANCE

26 MAY, 2012

INONU HALL

09:00-10:30  
Joint Session:  
WG Intensive Care and  
Intervention

11:00-12:30  
Abstract Session 10 GUCH

30 AGUSTOS HALL

09:00-10:30  
Hereditary Arrhythmia  
Syndromes:  
An Update

11:00-12:30  
Interventions:  
Failures, Complications  
and Successes

12:30-13:30  
Keynote Lecture and  
Closing Remarks



*46th Annual Meeting of the  
Association for European Paediatric and  
Congenital Cardiology,  
Istanbul, Turkey,  
May 23–26, 2012*

## **SCIENTIFIC PROGRAMME**

---

### **WEDNESDAY 23 MAY 2012**

**We 8:30-15:30**

#### **UPDATE FETAL CARDIOLOGY COURSE**

**We 08:30-10:15  
30 Ağustos Hall**

#### **Update Course: Fetal Cardiology**

*Chair: Adriana C. Gittenberger-de Groot (Leiden, NL), Funda Öztunç (Istanbul, TR)*

08:30

Overview

*Jose Carlos Areias*

08:45

Imaging the first trimester heart: Ultrasound correlation with morphology

*Monique Jongbloed / Monique Haak*

09:10

Changing physiology in the first to third trimester fetal circulation

*Joanna Dangel*

09:30

Second trimester diagnosis: screening standards and outcomes

*Sally-Ann Clur*

09:50

Cardiac function: Assessing new technologies

*Doff McElhinney*

**We 10:15-10:45**

#### **Coffee Break**

**We 10:45-12:30  
30 Ağustos Hall**

#### **Update Course: Fetal Cardiology**

*Chair: Ulrike Herberg (Bonn, DE), Helena Gardiner (London, UK)*

10:45

Overview

*Mats Mellander*

11:00

Therapy of tachyarrhythmia: Can you select the best treatment?

*Gurleen Sharland*

11:15

Congenital heart block: current thoughts on management morphologic spectrum and role of intervention

*Teresa Alvarez*

11:30

Critical aortic stenosis

*Gerald Tulzer / Adam Kolesnik*

11:45

Closed interatrial septum

*Doff McElhinney / Annalisa Angelini*

12:00

Critical pulmonary stenosis

*Doff McElhinney / Annalisa Angelini*

12:15

Round table to discuss evidence on selection for success

*Mellander, Tulzer, McElhinney, Alvarez, Kolesnik, Angelini, Oepkes*

**We 12:30-13:45**

#### **Lunch**

**We 13:45-15:30  
30 Ağustos Hall**

#### **Update Course: Fetal Cardiology**

*Chair: Ulrike Salzer-Muhar (Vienna, AT), Frank Casey (Belfast, IR)*

13:45

Overview

*Frank Casey*

- 14:00 Extracardiac malformations-associations and importance  
*Dick Oepkes*
- 14:20 Living with CHD: Quality of life in early adult life  
*Maria Emilia Areias*
- 14:40 Roundtable with examples proposed by chairs for discussion  
*Casey, Oepkes, Areias, McElhinney*
- 15:00 Closing Remarks: Round up three sessions  
*Helena Gardiner*

**We 10:00-13:00**  
**Inönü Hall** **Scientific Advisory Committee**

**We 14:00-16:00**  
**Inönü Hall** **Coding Committee**

**We 9:00-12:30**  
**Fevzi Çakmak Hall** **National Delegates Meeting**

**We 14:00-16:00**  
**Fevzi Çakmak Hall** **Profesional Advisory Committee**

**We 16:00-18:00**  
**30 Ağustos Hall** **Opening Ceremony and Mannheimer Lecture**  
*Chair: Shakeel Qureshi (London, UK), Alpay Çeliker (Istanbul, TR)*

16:00 Pediatric Cardiology in South America  
*Roberto Canessa*

**We 18:00-20:00**  
**30 Ağustos Hall** **Welcome Reception**

#### THURSDAY 24 MAY 2012

**Th 08:00-09:00**  
**30 Ağustos Hall** **WG Business Meeting: Cardiac Imaging**

**Th 08:00-09:00**  
**Inönü Hall** **WG Business Meeting: Cardiac Dysrhythmia and Electrophysiology**

**Th 08:00-09:00**  
**Fevzi Çakmak Hall** **WG Business Meeting: Cardiovascular Morphology**

**Th 08:00-09:00**  
**Malazgirt Hall 1** **WG Business Meeting: Fetal Cardiology**

**Th 08:00-09:00**  
**Malazgirt Hall 2** **WG Business Meeting: Paediatric Cardiovascular Intensive Care**

**Th 08:00-09:00**  
**HALL 1** **WG Business Meeting: Prevention**

**Th 09:00-10:30**  
**30 Ağustos Hall** **Plenary Session: Emerging Management Strategies for Neonatal Cardiac Emergencies**  
*Chair: Mario Carminati (Milan, IT), Satoshi Yasukochi (Nagano, JP)*

09:00 Surgery for the unusual anatomy—Primary repair vs palliation, covering aortic atresia, the very complex transposition, absent pulmonary valve and the borderline Left Ventricle  
*David Barron*

09:25 Intervention: RVOT stents, palliation for coarctation, duct stenting, hybride and intervnetion in premature babies  
*Dietmar Schranz*

09:50 Impact of antenatal diagnosis, optimal delivery conditions.  
*Motoyoshi Kawataki*

**Th 10:30-11:30** **Coffee Break, Exhibition**

**Th 10:30-11:30**  
**Kocatepe Hall** **Poster Walk 1**  
*Chair: Caroline Ovaert (Brussels, BE), Mathias Emmel (Koeln, DE)*

- PW1-1 Genetic background of long QT syndrome in infants, children, and adolescents  
*Yoshinaga M., Kucho Y., Horigome H., Ushinohama H., Ishikawa S., Yoshikane Y.*
- PW1-2 Cryoablation of Mahaim Pathways in Children  
*Ergul Y., Ozturk E., Akdeniz C., Tanidir I.C., Tola H.T., Tuzcu V.*
- PW1-3 Histopathological characterization of cryolesions at growing myocardium  
*Kriebel T., Schneider, H.E., Stahl M., Quentin T., Sigler M., Steinmetz M., Müller M., Paul T.*
- PW1-4 Sensing malignancy: Prodromal signs of post-transplant lymphoproliferative disease in pediatric heart transplant recipients  
*Lehner A., Kohler S., Huebner M., Lang N., Kozlik-Feldmann R., Netz H.*
- PW1-5 The three year experience in treatment of dilated cardiomyopathy by bone marrow derived cell intramyocardial implantation in childhood  
*Bergmane I., Ozolins V., Lubaua I., Erglis A., Lasis A.*
- PW1-6 Aetiology, Presentation, and Outcomes of Hypertrophic Cardiomyopathy in Childhood in Wales  
*Uzun O., Seddon T., Babaoglu K., Ayhan Y.I., Wilson D.G.*
- PW1-7 The natural history of patients with scimitar syndrome: an Italian multi-centric study of the Italian society of pediatric cardiology  
*Vida V.L., Padrini M., Bondanza S., Butera G., Marasini M., Pilati M., Pongiglione G., Prandstraller D., Russo M.G., Santoro G., Spadoni I., Milanese O.*
- PW1-9 Comparison of the effect of inhaled with intravenous anaesthetic on pulmonary vascular resistance measurement at cardiac catheterisation  
*Tulloh R., Beringer R., Morgan G., White M.*
- PW1-10 Clinical classification of congenital heart disease associated pulmonary hypertension. Does it work for pediatrics? Analysis of the TOPP registry (Tracking outcome and practice in pediatric pulmonary hypertension)  
*Beghetti M., Schulze-Neick I., Barst R.J., Kronmal D., Berger R.M.F., Humpl T.*
- PW1-11 Circulating Endothelial Cell Levels Decrease after Vasodilator Therapy and are a Biomarker of Deterioration in Pediatric Pulmonary Hypertension.  
*Bonnet D., Lévy M., Mauge L., Gaussem P., d'Audigier C., Celermajer D., Smadja D.M.*
- PW1-12 Hospitalization for Lower Respiratory Tract Infection Increases the Risk of Childhood Respiratory Morbidity Among Children with Congenital Heart Disease  
*Vo P., Szabo S.M., Gooch K.G., Korol E.E., Bradt P., Mitchell I., Levy A.R.*

**Th 10:30-11:30**  
**Kocatepe Hall**

**Poster Walk 2**

*Chair:* Lazslo Cornyei (Budapest, HU), Nazmi Narin (Kayseri, TR)

- PW2-1 Laser capture microdissection and comparative microarray expression analysis identified vessel-specific molecular markers of the ductus arteriosus and aorta in fetal rats  
*Bokenkamp R., Van Brempt R., Van Munsteren J.C., van de Wijngaert I., De Hogt R., Finos L., Goeman J., Gittenberger-de Groot A.C., Poelmann R., Blom N.A., DeRuiter M.C.*
- PW2-2 Pediatric Usage of a Newly Available Handheld (Einthoven Lead I) Web Based Event Recorder [ER] (Zenicor EKG-2 TM): First Results  
*Will J.C., Usadel L., Opgen-Rhein B., Weiss K., Haverkämper G., Herrmann S., Kelm M., Bader C., Panagiotou E., Fröhlich C., Kieslich M., Schmitz L., Berger F.*
- PW2-3 Long-term survival after paediatric cardiac surgery in patients with congenital heart defects  
*Sunnegardh J., Berggren H., Synnergren M.*
- PW2-4 Evidence of Seasonality in Births of Patients with Congenital Heart Disease Who Require Subsequent Surgical Repair  
*McCrinkle B.W., Stenyk L., Sidhu S., Manhiot C.*
- PW2-5 Social and health related coping strategies of parents of children with operated congenital heart disease  
*Markova M.I., Kaneva-Nencheva A., Angelova D., Tzonzarova M.*
- PW2-6 Reduced pulmonary diffusing capacity is highly increasable in Fontan patients  
*Idorn L., Hanel B., Jensen A.S., Juul K., Reimers J.I., Nielsen K.G., Søndergaard L.*
- PW2-7 Structural brain changes in teenagers with essential arterial hypertension  
*Plotnikova I., Usov V., Plotnikov M., Kovalev I.*
- PW2-8 Exercise Training Improves Activity and Psychosocial Wellbeing in Adolescents with Congenital Heart Disease (CHD)  
*Morrison M.L., Sands A.J., McCusker C.G., McKeown P.P., McMahon M., Gordon J., Craig B.G., Casey F.A.*

- PW2-9 Quality of life in school-age survivors of severe congenital heart disease: results from the UK Collaborative Study of Congenital Heart Defects (UKCSCHD)  
*Day T.G., Dezateux C., Wade A., Bull C., Wren C., Knowles R.*
- PW2-10 Truncal valve function in children following primary correction of common arterial trunk. A long term longitudinal single centre study  
*Chaloupecký V., Krupičková S., Škovránek J., Marek J., Tláskal T., Gebauer R., Reich O., Tomek T., Janoušek J.*
- PW2-11 Exercise capacity and biventricular function in adult patients with repaired tetralogy of Fallot.  
*Bálint O.H., Környei, L., Fischer D., Köhalmi D., Szatmári A., Temesvári A.*
- PW2-12 Reference Values of Aortic Augmentation Index in a Large Healthy Population Aged 3-18 Years  
*Hidvégi E., Illyés M.*

**Th 10:30-11:30**  
**Fevzi Çakmak Hall**

**Mechanical Circulatory Support in Children**

*Chair:* Hashim Abdul-Khaliq (Homburg, DE), Süleyman Özkan (İstanbul, TR)

- 10:30 Extracorporeal membrane oxygenation in neonates, infants and young children  
*Ergin Koçyıldırım*
- 10:55 Current applications and future trends in mechanical circulatory support in children  
*Egemen Tüzün*

**Th 11:30-13:00**  
**30 Ağustos Hall**

**Cardiac Imaging in Evolution**

*Chair:* Owen Miller (London, UK), Ornella Milanese (Padua, IT)

- 11:30 Echocardiography: from visible to invisible  
*Jan Marek*
- 11:50 Cardiac magnetic resonance: Live guidance and assistance for interventions  
*Titus Kuehne*
- 12:10 CT and congenital heart disease; is there a need for this?  
*Joachim Eichhorn*
- 12:30 Modelling and remodelling the heart: experience in pediatric heart disease  
*William Helbing*

**Th 11:30-13:00**  
**İnönü Hall**

**Arrhythmia in Postoperative Congenital Heart Disease**

*Chair:* Jan Janousek (Prague, CZ), Thomas Kriebel (Göttingen, DE)

- 11:30 Arrhythmia substrates in postoperative CHD  
*Monique Jongbloed*
- 11:50 Ventricular arrhythmia in tetralogy of Fallot: role of catheter ablation  
*Thomas Paul*
- 12:10 Catheter ablation of IART in patients with CHD  
*Joachim Hebe*
- 12:30 Surgical treatment of atrial arrhythmia in Fontan patients  
*Marcus Haw*

**Th 11:30-13:00**  
**Fevzi Çakmak Hall**

**Abstract Session 1: Intervention I**

*Chair:* Caroline Ovaert (Leuven, BE), John Thomson (Leeds, UK)

- 11:30 Significance of Premature Restriction or Closure of Foramen Ovale in the Fetus  
O2-1 *Uzun O., Babaoglu K., Ayhan Y.I., Massias S., Conner C., Beattie B.*
- 11:40 Relief of early post-operative Sano Shunt stenosis in neonates with hypoplastic left heart syndrome  
O2-2 *Eicken A., Genz T., Fakler U., Kasnar-Samprec J., Schreiber C., Hess J.*
- 11:50 Freedom from Antihypertensive Medication after Balloon Dilatation with Stent Implantation in Patients with Coarctation of the Aorta  
O2-3 *Galvão P., Matos Silva M., Amador P., Figueiredo C., Cordeiro S., Maymone Martins F., Francisco A., Anjos R.*
- 12:00 Mitral valve replacement in children: long-term results and risk factors influencing outcome  
O2-4 *Krupickova S., Skovranek J., Reich O., Chaloupecký V., Tlaskal T., Hucin B., Gebauer R., Bartakova H., Janousek J.*
- 12:10 Over-the-wire-technique device implantation: extended experience in difficult cases.  
O2-5 *Butera G., Castaldi B., MacDonald S.T., Fesslova V., Saracino A., Calaciura R., Carminati M.*
- 12:20 Hemocompatible Carbon Based Biosurfaces for Cardiovascular Implants  
O2-6 *Aktas C., Kenar H., Miro M.M., Anschütz D., Löw K., Schütt J., Brück S., Haidar A., Karaöz E., Abdul-Khaliq H.*



- 12:30  
O2-7 Left Pulmonary Artery Stenting in the Palliated Hypoplastic Left Heart  
*Noonan P., Anderson B., Ramchandani B., Reinhardt Z., Miller P., Dhillon R., Mehta C., Stumper O.*
- 12:40  
O2-8 Is stenting of pulmonary artery branch stenoses helpful to reduce the amount of pulmonary regurgitation in patients with Tetralogy of Fallot?  
*Degener F., Laser K.T., Haas N.A., Matthies W., Sandica E., Körperich H., Burchert W., Kececioglu D.*
- Th 11:30-13:00  
Malazgirt Hall 1** **Abstract Session 2: Basic Science/Genetics**  
*Chair: Damien Bonnet (Paris, FR), Birgit Donner (Dusseldorf, DE)*
- 11:30  
O3-1 Reversible Pulmonary Trunk Banding. VIII. Glucose-6-Phosphate Dehydrogenase Activity of Adult Goat Myocardium Submitted to Ventricular Retraining  
*Assad R.S., Miana L.A., Fonseca-Alaniz M.H., Abduch M.C.D., Silva G.J.J., Oliveira F.S., Krieger J.E., Moreira L.F.P.*
- 11:40  
O3-2 An activable adhesive for patch closure of cardiovascular defects  
*Lang N., Pereira M.N., Friehs I., Vasilyev N., Ablasser K., O’Cearbhaill E., Xu C., Yamauchi H., Hammer P., Wasserman S., Karp J.M., del Nido P.J.*
- 11:50  
O3-3 Deficiency of the cardiac potassium channel TASK-1 results in a LQTS phenotype and alters heart rate variability  
*Donner B.C., Petric S., Clasen L., van Weßel C., Ding Z., Schmidt K.G.*
- 12:00  
O3-4 Cardiovascular malformation spectrum of CHD7 mutations in CHARGE syndrome  
*Bonnet D., Parisot P., Bajolle F., Goudefroye G., Lyonnet S., Attié-Bitach T.*
- 12:10  
O3-5 Identification of novel genetic risk loci associated with fetal outcome in congenital heart block  
*Görge S., Ding B., Salomonsson S., Klareskog L., Hamsten A., Hillert J., Alfredsson L., Olsson T., The Swedish Congenital Heart Block Study Group, Kockum I., Wahren-Herlenius M.*
- 12:20  
O3-6 Propofol administration to the fetal-maternal unit reduced myocardial injury in late-preterm lambs subjected to severe prenatal asphyxia and cardiac arrest  
*Seehase M., Houthuizen P., Jellema R.K., Collins J.J.P., Bekers O., Breuer J., Kramer B.W.*
- 12:30  
O3-7 Echocardiographic assessment of normal embryonic and fetal mouse heart development  
*Hahurij N.D., Jongbloed M.R.M., Calkoen E.E., Gittenberger-de Groot A.C., Poelmann R., van Munsteren J.C., Steendijk P., Blom N.A.*
- 12:40  
O3-8 Mesenchymal stem cells improve functional and morphological integration of induced pluripotent stem-cell derived cardiomyocytes into ventricular tissue  
*Khalil M., Rubach M., Hannes T., Udink ten Cate F., Choi Y., Neef K., Pillekamp F., Hescheler J., Brockmeier K., Adelman R.*
- Th 13:00-14:30** **Lunch**
- Th 14:30-16:00  
30 Ağustos Hall** **Pediatric Pulmonary Hypertension Present and Future**  
*Chair: Maurice Beghetti (Geneva, CH), Sylvio Di Filippo (Lyon, FR)*
- 14:30  
CHD-PAH in children- A similar disease to PAH in Adults  
*Rolf Berger*
- 14:50  
Intervening in PAH-CHD- Optimal timing  
*Maurice Beghetti*
- 15:10  
Treat and repair- is it possible?  
*Ingram Schulze Neick*
- 15:30  
What THALES showed us? The outcomes of the registry  
*Gül Sagin Saylam*
- Th 14:30-16:00  
Inönü Hall** **Fetal Heterotaxy—New Aspects on Embryology, Morphology, Prenatal Diagnosis**  
*Chair: Helena Gardiner (London,UK), Adriana C. Gittenberger-de Groot (Leiden, NL)*
- 14:30  
Normal cardiac development and embryology of heterotaxy  
*Monique Jongbloed*
- 14:45  
Morphology of (the normal heart and) heterotaxy syndrome  
*Adam Kolesnik*
- 15:00  
Discussion
- 15:15  
Cardiac and extracardiac sonographic findings in fetal heterotaxy-what does it mean for the fetus? (including intrauterine course; implications on prenatal counselling)  
*Ulrike Herberg*

- 15:30 Perinatal management and long term outcome for the neonate with heterotaxy (focus on long term, risk of surgery, associated anomalies)  
*Doff McElhinney*
- 15:45 Round Table Discussion
- Th 14:30-16:00**  
**Fevzi Çakmak Hall**
- Abstract Session 3: Dysrhythmia/Electrophysiology**  
*Chair: Joachim Hebe (Bremen, DE), Juha Matti Happonen (Helsinki, FI)*
- 14:30 The Brugada Syndrome in children: presentation and outcome of proband patients.  
O1-1 *Dewals W., Benatar A., Sarkozy A., De Asmundis C., Brugada P.*
- 14:40 Loss of sodium channel function-like phenotypes: Diagnostic and therapeutic aspects  
O1-2 in children  
*Chockalingam P., Clur S.A.B., Breur J.M.P.J., Kriebel T., Paul T., Rammeloo L.A., Wilde A.A.M., Blom N.A.*
- 14:50 Tachyarrhythmia following Norwood Operation: A Single Center Experience  
O1-3 *Gist K.M., Erickson B.A., Schuchardt E.L., Morose M., Kaufman J., Da Cruz E., Mitchell M.B., Campbell D.N., Jaggars J., McCanta A.C.*
- 15:00 Cryoablation with an 8-mm Tip Catheter for Supraventricular Tachycardia Substrates in Children  
O1-4 *Tanidir I.C., Akdeniz C., Ergul Y., Tola H.T., Kiplapinar N., Tuzcu V.*
- 15:10 Cryoablation of Antroseptal Accessory Pathways in Children with Limited Fluoroscopy Exposure  
O1-5 *Akdeniz C., Tola H.T., Ergul Y., Saygi M., Kiplapinar N., Tuzcu V.*
- 15:20 Outcome of Complete Heart Block Diagnosed in Fetal and Postnatal Life  
O1-6 *Uzun O., Babaoglu K., Jones H.M., Wiener J., Conner C., Beattie B.*
- 15:30 Minimal- Invasive Transcutaneous Epicardial Pacemaker-Lead Implantation—A Novel  
O1-7 Approach To Avoid Thoracotomy  
*Hacke P., Schmitt B., Priestersbach H., Ewert P., Berger F., Peters B.*
- 15:40 Clinical profile and follow-up data of patients included in the European Registry for ICD and  
O1-8 CRT devices in Pediatrics and Adults with Congenital Heart Disease (Euripides): An Interim Report  
*Janoušek J., Kučera F., Hebe J., Pflaumer A., Kolb C., Bauersfeld U. + [for the Working Group Cardiac Dysrhythmias and Electrophysiology of the AEPC, Working Group for Adults with Congenital Heart Defect of the ESC and the Competence Network Congenital Heart Disease.]*
- Th 14:30-16:00**  
**Malazgirt Hall 1**
- Anatomic Exhibition 1: Hands on Session**  
*Chair: Annalisa Angelini (Padua, IT), Nazan Özbarlas (Adana, TR)*
- 14:30 The common atrioventricular junction and its anatomic variants  
*Lucile Houyel*
- Th 16:00-16:30**  
**Coffee Break, Posters and Exhibition**
- Th 16:30-18:00**  
**30 Ağustos Hall**
- Joint Session: WG Dysrhythmia, Basic Science and Morphology**  
*Chair: Beatrijs Bartelds (Groningen, NL), László Környei (Budapest, HU)*
- 16:30 Development of the AVN  
*Antoon Moorman*
- 16:50 The AV conduction system in normal and abnormal hearts  
*Monique Jongbloed*
- 17:10 AV conduction disease: Genetic aspects  
*Patrice Bauvagnet*
- 17:30 Catheter ablation of AVNRT  
*Juha Matti Happonen*
- Th 16:30-18:00**  
**Inönü Hall**
- Abstract Session 4: Surgery and Intensive Care**  
*Chair: Ricardo Munoz (Pittsburgh, USA), Adnan Uysalel (Ankara, TR)*
- 16:30 New generation decellularized biological valve as pulmonic conduit in congenital heart surgery  
O4-1 *Ozkan S., Salihoglu E., Ozcobanoglu S., Celiker A.*
- 16:40 Incidence of interventions after Norwood operation: Comparison of Sano and modified Blalock  
O4-2 Taussig shunt  
*Photiadis J., Fischbach J., Sinzobahamvya N., Schindler E., Schneider M., Hraška V., Asfour B.*
- 16:50 Does posterolateral thoracotomy with cardiopulmonary bypass play a role in the surgical  
O4-3 management of aortic coarctation?  
*Sandrio S., Eichhorn J., Gorenflo M., Karck M., Loukanov T.*

- 17:00  
O4-4 Early surgical outcome of a new modification for Senning procedure  
*Salihoglu E., Ozkan S., Ozcobanoglu S., Celiker A.*
- 17:10  
O4-5 Transposition of the great arteries with intact ventricular septum. Arterial Switch Operation in patients one month of age or older.  
*Ly M., Garcia E., Kalfa D., Rousin R., Lebret E., Belli E.*
- 17:20  
O4-6 Outcome of the Ross procedure in 100 Children and Adults : Low mortality, excellent survival but frequent reinterventions during mid-term follow-up  
*Zimmermann C., Attenhofer Jost C.H., Prêtre R., Müller C., Greutmann M., Seifert B., Weber R., Valsangiacomo Büchel E.R., Kretschmar O., Dave H.*
- 17:30  
O4-7 Valved patches for closure of ventricular septal defects in patients with severe right ventricular pressure overload  
*Francisco A., Teixeira A., Nogueira G., Maymone M., Abecasis M., Neves J.P., Anjos R.*
- 17:40  
O4-8 ECMO in the perioperative course of pediatric heart surgery  
*Matoussi Z., Henaine R., Ducreux C., Veyrier M., Sassolas F., Metton O., Ninet J., Di Filippo S.*
- 17:50  
O4-9 Subsequent nitric oxide with inhaled iloprost versus inhaled iloprost alone in pulmonary hypertension following cardiac surgery in children with congenital heart disease  
*Harimurti G.M., Budiwardhana N., Marwali E.M.*

**Th 16:30-18:00**  
**Fevzi Çakmak Hall**

**Joint Session: WG Physiosocial and GUCH Task Force**  
*Chair: Frank Casey (Belfast, IR), Katya de Groote (Gent, BE)*

- 16:30 Have we been able to improve long term Psychosocial outcomes in major Congenital Heart Disease  
*Elisabeth Utens*
- 16:55 Impact of Exercise on Physical and Psychosocial well-being in Adolescents with Congenital Heart Disease  
*Louise Morrison*
- 17:20 Obstacles I have faced because of my heart problem!!!  
*Patient from Turkey*

**Th 18:00-20:30**  
**30 Ağustos Hall**

**AEPC Business Meeting**  
*Chair: Shakeel Qureshi (London, UK), Katarina Hanseus (Lund, SE)*

**FRIDAY 25 MAY 2012**

**Fr 08:00-09:00**  
**30 Ağustos Hall**

**WG Business Meeting: GUCH Task Force**

**Fr 07:30-09:00**  
**Inönü Hall**

**WG Business Meeting: Interventional Cardiology**

**Fr 08:00-09:00**  
**Fevzi Çakmak Hall**

**WG Business Meeting: Psycho-Social Care from Fetus to Adult**

**Fr 08:00-09:00**  
**Malazgirt Hall 1**

**WG Business Meeting: Genetics and Basic Science**

**Fr 08:00-09:00**  
**Malazgirt Hall 2**

**WG Business Meeting: Congenital Heart Surgery**

**Fr 09:00-10:30**  
**30 Ağustos Hall**

**JSPCCS/AEPC Session: Persistent Arterial Trunk**  
*Chair: Isao Shiraishi (Tokyo, JP), Konrad Brockmeier (Cologne, DE)*

- 09:00 Anatomical variants: truncal valve, unbalanced ventricles, Trunk from RV, interruption/AP window  
*Annalisa Angelini*
- 09:20 Long term results for repair of Persistent Arterial Trunk  
*Toshio Nakanishi*
- 09:40 What the surgeon wants to know from the imager  
*Gerardus Bennink*
- 10:00 Surgical timing, techniques and results. Is there a role for palliation and when?  
*Toshihide Nakano*

**Fr 09:00-10:30**  
**Inönü Hall**

**Intensive Care Group Meeting**  
*Chair: Evelyn Lechner (Linz, AT), Joan Sanchez de Toledo (Barcelona, SP)*

- 09:00 Diversity of PCICU's in Europe  
*Nikolaus Haas*
- 09:20 Impact of interdisciplinary on quality improvement and after initiatives in the cardiac ICU  
*Eduardo Da Cruz*
- 09:40 Challenging case in PCICU: Fighting for survival in a neonate with cyanotic heart disease.  
Unusual pathways  
*Ricardo Munoz*
- 10:00 Challenging case in PCICU: All by the books but no success...  
*Nikolaus Haas*

**Fr 09:00-10:30**  
**Fevzi Çakmak Hall**

**WG Fetal-Puzzle the Experts**

*Chair:* Joanna Dangel (Warsaw, PL), Jose Carlos Areias (Porto, PT)

- 09:00 Doff McElhinney, Teresa Alvarez, Gerald Tulzer, Damien Bonnet  
*Experts*
- 10:30 Case 1  
*Sally-Ann Clur*
- 10:45 Case 2  
*Ulrike Herberg*
- 11:00 Case3  
*Joanna Dangel*
- 11:15 Case 4  
*Helena Gardiner*
- 11:30 Case 5  
*Gurleen Sharland*
- 11:45 Case 6  
*Joanna Dangel*

**Fr 09:00-10:30**  
**Malazgirt Hall 1**

**Abstract Session 5: General Cardiology I**

*Chair:* Giacomo Pongiglione (Rome, IT), Rana Olguntürk (Ankara, TR)

- 09:00  
O10-1 Evaluation of Coronary Artery Abnormalities and Sudden Death Risk in Williams Syndrome Patients Using Myocardial Perfusion Scintigraphy and CT Angiography  
*Dindar A., Ergul Y., Nisli K., Kayserili H., Karaman B., Basaran S., Dursun M., Yilmaz E., Unal S.N.*
- 09:10  
O10-2 ECG risk score: a significant advance in the risk stratification of paediatric patients with hypertrophic cardiomyopathy  
*Östman-Smith I., Fernlund E., Larsson P., Sjöberg G., Rydberg A.*
- 09:20  
O10-3 High Prevalence of Sarcomeric Mutations in a Pediatric Cohort of Hypertrophic Cardiomyopathy  
*Vázquez-Álvarez M.C., Medrano-López C., Blanco-Soto P., Rodríguez-Ogando A., Centeno-Jiménez M., Camino-López M., Monserrat-Iglesias L., Orera-Clemente M., Maroto-Álvaro E. [The MyEstela Study Group]*
- 09:30  
O10-4 Origin, genotype and clinical phenotype of the Long QT Syndrome R518X/KCNQ1 mutation in Sweden  
*Winbo A., Stattin E.L., Nordin C., Persson J., Diamant U.B., Jensen S.M., Rydberg A.*
- 09:40  
O10-5 Unexpected Sudden Cardiac Death Under School Supervision in Japan  
*Ayusawa M., Sumitomo N., Abe Y., Nakamura T., Fukuhara J., Ichikawa R., Matsumura M., Kanamaru H., Okada T., Itoh S., Mugishima H.*
- 09:50  
O10-6 Neurodevelopmental outcome at one year of age after neonatal cardiac surgery for severe congenital heart disease in relation to perioperative cerebral magnetic resonance imaging  
*Knirsch W., Bertholdt S., Batinic K., Liamlahi R., Makki M., Kellenberger C., Scheer I., von Rhein M., Schmitz A., Bernet V., Hug M.I., Dave H., Latal B.*
- 10:00  
O10-7 Outcomes associated with occlusive thrombosis and its management in pediatric patients after cardiac surgery  
*McCrindle B.W., Brandao L.R., Sivarajan V.B., Schwartz S.M., Williams S., Collins T.H., Manlhiot C.*
- 10:10  
O10-8 Long-term survival after univentricular heart surgery  
*Sunnegardh J., Berggren H., Synnergren M.*

**Fr 10:30-11:30**

**Coffee Break, Exhibition**

**Fr 10:30-11:30**

**Fevzi Çakmak Hall**

**Management of PAH in the Intensive Care**

*Chair:* Brigitte Stiller (Freiburg, DE), Rolf Berger (Groningen, NL)

- 10:30 Impact of pulmonary arterial hypertension in children with congenital heart defect in the intensive care unit.  
*Brigitte Stiller*  
Aerosolized iloprost treatment in the intensive care unit  
*Matthias Gorenflo*
- 10:50 Current approaches to the perioperative management of PAH  
*Alain Fraisse*

**Fr 10:30-11:30**

**Kocatepe Hall**

**Poster Walk 3**

*Chair:* Katya De Groote (Gent, BE), Deniz Oğuz (Ankara, TR)

- PW3-1 Long-term follow-up of patients with left lung perfusion abnormalities following transcatheter closure of patent ductus arteriosus  
*Demir F., Celebi A., Sartas T., Erdem A., Demir H., Yucel I.K., Dedeoğlu R.*
- PW3-2 Use of Covered Cheatham-Platinum (CCP) stents in congenital heart disease  
*Gewillig M., Vanagt W.Y., Boshoff D., Cools B., Heying R., Troost E., Budts W.*
- PW3-3 Transcatheter PDA-closure in (pre-term) newborns below 3 kg of weight  
*Jux C., Billinger K., Behnke-Hall K., Mazhari N., Schranz D.*
- PW3-4 Stenting of the Right Ventricular Outflow Tract  
*Stumper O., Reinhardt Z., Noonan P., Ramchandani B., Miller P., Dhillon R., Mehta C., Bohle V., de Giovanni J.V.*
- PW3-5 Closure of extracardiac Fontan fenestration with covered stents  
*Goreczny S., Dryzek P., Moszura T., Moll J.J., Sysa A., Moll J.A.*
- PW3-6 Retrograde transcatheter closure of ventricular septal defects using the Amplatzer duct occluder II device  
*Sreeram N., Penumatsa R., Arramraju S., Karunakar V., Koneti N.R.*
- PW3-7 Femoral vein occlusion in infants undergoing cardiac catheterisation pre-cavopulmonary shunt procedure  
*Gali V., Mirza R., Kudumula V., Noonan P., Stumper O., de Giovanni J.V., Dhillon R., Miller P., Mehta C., Ramchandani B., Bohle V.*
- PW3-8 Importance of coronary artery anatomy and variation in percutaneous pulmonary valve implantation \*former:P-313\*  
*Haas N.A., Moysich A., Laser K.T., Görg R., Kececioglu D*
- PW3-9 Transcatheter closure of secundum atrial septal defect associated with deficient rims other than the antero superior using Amplatzer devices.  
*Kammache I., Assaidi A., Mancini J., Habib G., Fraisse A.*
- PW3-10 Outcome after Fetal Diagnosis of Hypoplastic Left Heart Syndrome: The Toronto Experience of 267 Patients  
*Wertaschnigg D., Cavalle-Garrido T., Chitayat D., Ryan G., Chaturvedi R., Seed M., Golding F., van Arsdell G., Jaeggi E.*
- PW3-11 Prenatal cardiac diagnosis and the 'Postcode Lottery'; has UK NHS FASP (fetal anomaly screening protocol) made any difference yet?  
*Bu'Lock F., Peek G.J., Eltayb H., Shebani S.O.*
- PW3-12 Effect of changes to UK fetal cardiac screening protocols across the spectrum of congenital heart disease requiring intervention in the first year of life  
*Bu'Lock F., Peek G.J., Eltayb H., Shebani S.O.*

**Fr 10:30-11:30**

**Kocatepe Hall**

**Poster Walk 4**

*Chair:* Otto Krogman (Duisburg, DE), Ina Michel-Behnke (Wien, AT)

- PW4-1 Hypothermia after hypoxia is neuroprotective possibly via upregulation of cold shock proteins RBM3 and CIRP  
*Schmitt K.R.L., Rosenthal L.-M., Berger F., Tong G.*
- PW4-2 Weaning from ventricular assist device in non – myocarditis pediatric heart failure patients.  
*Thul J., Schranz D., Akintuerk H.*
- PW4-3 Cardiac catheterization yields significant information and improves outcome in otherwise unidentifiable hemodynamic instability early after congenital heart surgery  
*Fakler U., Cesna S., Eicken A., Genz T., Balling G., Hörer J., Hess J.*

- PW4-4 Going down, going slow-Esmolol as potent myocardial protector in rescue cardiac extracorporeal membrane oxygenation (ECMO)  
*Hutter D., Kadner A., Pfammatter J.-P., Pavlovic M., Wagner B.*
- PW4-5 Topsy-Turvy Heart: Very rare rotational heart anomaly with tracheobronchial anomalies  
*Erek E., Guzeltas A., Ozturk N., Kiyani G., Karakoc F., Akalin F., Odemis O., Arsan S.*
- PW4-6 Non-invasive three-dimensional pressure maps by flow-sensitive MRI: comparison of measurement accuracy compared to invasive catheterization in patients with aortic coarctation  
*Riesenkampff E., Meier S., Schubert S., Al-Wakeel N., Ewert P., Hennemuth A., Berger F., Peitgen H.-O., Kuehne T.*
- PW4-7 The influence of respiration on blood flow in children – validation by realtime MR velocity mapping at 3 Tesla  
*Laser K.T., Barth P., Al-Ali R., Esdorn H., Peterschröder A., Fischer M., Moysich A., Haas N.A., Gieseke J., Burchert W., Kececioglu D., Körperich H.*
- PW4-8 Assessment of Diffuse Myocardial Fibrosis Using Small-Animal Look-Locker Inversion Recovery T1 Mapping  
*Messroghli D., Nordmeyer S., Dietrich T., Riesenkampff E., Al-Wakeel N., O H-Ici D., Berger F., Kuehne T.*
- PW4-9 The role of Semi-Supine Cycle Ergometry Stress Echocardiography in Decision Making for Surgery in Children with Aortic Insufficiency  
*De Souza A.M., Potts J.E., Potts M.T., De Souza E.S., Cochrane J.M., Hennessey S.T., Sandor G.G.S*
- PW4-10 Assessment of Ventricular Pressure-Volume Relations and Myocontractility by Real Time Three Dimensional Transesophageal Echocardiography Coupled with Diagnostic Catheterization  
*Nordmeyer S., Kutty S., Padiyath A., Gribben P., Li L., Gao S., Drvol L., Lof J., Danford D.A., Berger F., Kuehne T.*
- PW4-11 An child-focused educational program allows INR stability and safety in children treated with VKA.  
*Bonnet D., Bajolle F., Lasne D., Elie C., Boudjemline Y.*
- PW4-12 Clinical Experience with Thrombolytic Therapy using Low Dose of Tissue Plasminogen Activator in the Management of Intracardiac and Major Vessels Thrombosis  
*Rodríguez A., Zunzunegui J.L., Santiago M.J., Ballesteros F., Álvarez M., Rodríguez R., Panadero E., Lopez Herce J, Maroto E.*

**Fr 11:30-13:00**  
**30 Agustos Hall**

**Young Investigator Award**

*Chair:* Jan Marek (London, UK),

*Jury:* Toshio Nakanishi (Tokyo, JP); Toshihide Nakano (Fukuoka, JP), Dietmar Schranz (Giessen, DE)

- 11:30  
O5-1 Analysis of Immunological Function of Infants with Congenital Heart Disease after Cardiopulmonary Bypass Surgery: Evaluation the Optimum Timing of Vaccination  
*Takanashi M., Nakahata Y., Ogihara Y., Honda T., Ando H., Kimura S., Miyaji K., Ishii M.*
- 11:45  
O5-2 Diagnostic value of parental electrocardiographic screening in congenital and childhood, non-immune, isolated atrioventricular block.  
*Baruteau A.E., Behaghel A., Fouchard S., Villain E., Thambo J.B., Marçon F., Gournay V., Rouault F., Chantepie A., Guillaumont S., Godart F., Bonnet C., Fraisse A., Schleich J.M., Lussion J.R., Dulac Y., Chatel S., Dina C., Schott J.J., Daubert J.C., Le Marec H., Mabo P., Probst V.*
- 12:00  
O5-3 Impaired TGF- $\beta$  mediated cardiac healing in patients with right ventricular dilatation after repair of tetralogy of Fallot  
*Luijnenburg S.E., Cheng C., van de Kamp E.H., Schreuder M.P.R., Chrifi I., Roos-Hesselink J.W., de Rijke Y.B., Mulder B.J.M., Vliegen H.W., Duckers H.J., Helbing W.A.*
- 12:15  
O5-4 Abnormal vascular load relates to impaired relaxation in patients with Fontan circulation  
*Nakagawa R., Senzaki H., Masutani S., Saiki H.*
- 12:30  
O5-5 Staged Fontan procedure ameliorates Ventricular hyper-fibrogenesis in the patients with single ventricular circulation  
*Saiki H., Sugimoto M., Seki M., Masutani S., Kajino M., Senzaki H.*
- 12:45  
O5-6 Fetal laterality disturbance: Single centre experience of 227 cases spanning three decades  
*Jones C.B., Simpson J.M., Miller O.I., Sharland G.K.*

**Fr 11:30-13:00**  
**Inönü Hall**

**Joint Session: WG Intervention and GUCH Task Force- VSD in adulthood in all its aspects**

*Chair:* Grażyna Brzezinska-Rajszyś (Warsaw, PL), Davide Marini (Turin, IT)

- 11:30 What should we do with the adults who still have a congenital VSD?  
*Massimo Chessa*

- 11:50 Small VSD: infective endocarditis prophylaxis and should they be closed after endocarditis?  
*Derise Boshoff*
- 12:10 Residual and iatrogenic post-surgical VSD  
*Alain Fraisse*
- 12:30 Post-myocardial infarction VSD  
*Mark Turner*

**Fr 11:30-13:00** **Joint Session: WG Genetics and Basic Science- Hypertrophic Cardiomyopathy**  
**Fevzi Çakmak Hall** *Chair: Mathias Gorenflo (Heidelberg, DE), Ingegerd Ostman-Smith (Gothenburg, SE)*

- 11:30 Genetic tools in the diagnosis of hypertrophic cardiomyopathy.  
*Patrice Bouvagnet*
- 11:45 ECHO and ECG in Hypertrophic Cardiomyopathy: What's new?  
*Juan Pablo Kaski*
- 12:05 Risk factors for adverse arrhythmic events in patients with hypertrophic cardiomyopathy.  
*Eric Rosenthal*
- 12:20 Impact of pre-symptomatic screening diagnosis of hypertrophic cardiomyopathy through family screening  
*Ewa-Lena Bratt*
- 12:35 The patient with hypertrophic cardiomyopathy—Strategies to prevent sudden death  
*Ingegerd Ostman-Smith*
- 12:55 Discussion

**Fr 13:00-14:30** **Lunch**

**Fr 13:00-14:00** **Junior Meeting**  
**Malazgirt Hall**

**Fr 14:30-16:00** **AEPC/EACTS Session: Controversies in Coarctation Management**  
**30 Ağustos Hall** *Chair: Joerg Stein (Innsbruck, AT), Juan Comas (Madrid, SP)*

- 14:30 Transverse arch hypoplasia  
*Andres Eicken*
- 14:50 The premature baby with coarctation  
*Mathias Emmel*
- 15:10 Which coarctations should not be operated on?  
*Juan Comas*
- 15:30 Which coarctation should not have an intervention?  
*Shakeel Qureshi*

**Fr 14:30-16:00** **Abstract Session 6: Imaging**  
**Inönü Hall** *Chair: Emanuela Valsangiacomo-Buechel (Zurich, CH), Otto Krogman (Duisburg, DE)*

- 14:30 Multiparametric assessment of the Right Ventricle by echocardiography in adult patients with repaired tetralogy of Fallot undergoing pulmonary valve replacement: a comparative study with MRI.  
*Selly J.B., Iriart X., Roubertie F., Mauriat P., Thambo J.B*
- 14:40 Determinants and Clinical Significance of Flow via the Fenestration in the Fontan Pathway: A Multimodality Study  
*Grosse-Wortmann L., Dragulescu A., Drolet C., Chaturvedi R., Kotani Y., Mertens L., Taylor K., La Rotta G., van Arsdell G., Redington A., Yoo S.-J.*
- 14:50 Assessment of intraatrial lateral tunnel anatomy and venous blood flow in children with hypoplastic left heart syndrome in Fontan circulation  
*Voges I., Jerosch-Herold M., Scheewe J., Hart C., Gabbert D.D., Hansen T., Kramer H.-H., Rickers C.*
- 15:00 Abnormal blood flow pattern in the aorta and pulmonary trunk of patients with Transposition of the Great Arteries operated with Atrial Baffle Switch  
*Nordmeyer S., Messroghli D., Berger F., Kuehne T., Riesenkampff E.*
- 15:10 The role of Dipyridamole stress echocardiography in the diagnosis of coronary pathology after the arterial switch operation for Transposition of the great arteries  
*Spadoni I., Terrazzi M., Lunardini A., Scebba L., Ait-Ali L., De Lucia V., Mazzone A., Giusti S.*
- 15:20 Temporal and spatial accuracy of 3D real time echocardiography in the neonatal and pediatric setting-Validation studies using small moving and pulsative phantoms  
*Herberg U., Faller J., Klebach C., Breuer J.*

- 15:30  
O6-7 Tissue motion annular displacement (TMAD) of the mitral valve using two dimensional speckle tracking echocardiography predicts left ventricular ejection fraction in normal children.  
*Black D., Bryant J., Peebles C., Hanson M.A., Vettukattil J.*
- 15:40  
O6-8 Evaluation of complex congenital heart disease and associated complications in newborns, infants and small children using multi-detector CT (MDCT) – An 11-years-experience at 5 centers  
*Eichhorn J.G., Ley S., Loukanov T., Fink C, Cheatham J, Long F, Helbing W.A., Gorenflo M.*
- Fr 14:30-16:00**  
**Fevzi Çakmak Hall** **Abstract Session 7: Fetal**  
*Chair: Gurleen Sharland (London, UK), Klaus Schmidt (Dusseldorf, DE)*
- 14:30  
O7-1 Efficacy and impact of a nation-wide prenatal cardiac screening program  
*Tomek V., Škovránek J., Gilik J., Janoušek J.*
- 14:40  
O7-2 The differential insertion of the atrioventricular valves: a plane-dependent echocardiographic feature for normal fetal hearts  
*Adriaanse B.M.E., Bartelings M.M., Vugt J.M.G., Gittenberger-De Groot A.C., Haak M.C.*
- 14:50  
O7-3 Congenital heart defects in twin pregnancies  
*Bonnet D., Raimondi F., Bajolle F., Stirnemann J., Ville Y., Le Bidois J., Fermont L.*
- 15:00  
O7-4 Cardiovascular function after successful treatment of intrauterine twin-to-twin transfusion syndrome – a 10-year long-term follow-up  
*Herberg U., Bolay J., Maschke C., Hecher K, Bartmann P., Breuer J.*
- 15:10  
O7-5 Features and outcomes of fetuses with tricuspid atresia  
*Fesslova V., Brankovic J., Boschetto C., Piazza L., Butera G., Arcidiacono C., Negura D., Micheletti A., Chessa M., Giamberti A., Pomé G., Carminati M., Frigiola A.*
- 15:20  
O7-6 Hypoplastic Left Heart Syndrome with Restrictive Atrial Septum: Echocardiographic Criteria for the Need of In-Utero Catheter Intervention and First Results of Human Fetal Atrial Stenting  
*Jaeggi E., Ryan G., Seed M., Chaturvedi R.*
- 15:30  
O7-7 Outcome after Fetal Diagnosis of Ebstein's Anomaly and Dysplasia of the Tricuspid Valve: A Single Center Experience  
*Wertaschnigg D., Manlhiot C., Baliulis G., Kotani Y., Jaeggi M., Dragulescu A., McCrindle B.W., van Arsdell G., Jaeggi E.*
- 15:40  
O7-8 Neonatal management of critical aortic stenosis after in-utero valvuloplasty: role of Ross-Konno operation  
*Tulzer G., Arzt W., Gitter R., Sames E., Wertaschnigg D., Veit I., Mair R.*
- Fr 14:30-16:00**  
**Malazgirt Hall** **Anatomic Exhibition 2: Workshop on Fetal Cardiovascular Anatomy**  
*Chair: Nynke Elzenga (Groningen, NL), Adriana Gittenberger-de Groot (Leiden, NL)*
- 14:30 Anatomy of the normal fetal thorax, including other organs visible in fetal echocardiography: lungs, trachea, esophagus.  
*Adam Kolesnik, Cezary Niszczoła*
- 14:50 Anatomy of the fetal heart in embryonic and fetal periods.  
*Adam Kolesnik, Cezary Niszczoła*
- 15:10 Anatomy of the fetal circulation  
*Adam Kolesnik, Cezary Niszczoła*
- 15:30 Anatomy of fetal cardiovascular interventions  
*Adam Kolesnik, Cezary Niszczoła*
- Fr 16:00-16:30**  
**Coffee Break, Posters and Exhibition**
- Fr 16:30-18:00**  
**30 Ağustos Hall** **WG Prevention: Why do we need prevention?**  
*Chair: Eero Jokinen (Helsinki, FI), Robert Dalla Pozza (Munich, DE)*
- 16:30 Epidemiology of cardiovascular disease in Europe  
*Eero Jokinen*
- 16:50 Onset of cardiovascular disease during gestation  
*Adriana Gittenberger-de Groot*
- 17:10 Risk factors for cardiovascular disease in childhood and youth  
*Renate Oberhoffer*
- 17:30 Preventional programmes in Europe  
*Andreas Petropulos*



**Fr 16:30-18:00**

**Inönü Hall**

**Abstract Session 8: Intervention II**

*Chair:* Jochen Weil (Munich, DE), Rui dos Anjos (Carnaxide, PT)

- 16:30  
08-1  
16:40  
08-2  
16:50  
08-3  
17:00  
08-4  
17:10  
08-5  
17:20  
08-6  
17:30  
08-7  
17:40  
08-8
- Towards a fully absorbable percutaneous ASD closure device  
*Jux C., Billinger K., Kaltbeitzel D., Schwiager T., Herden C., Schneider M.*
- Self-expanding stent Sinus superflex Visual to create an unrestrictive atrial communication in infants  
*Cools B., Louw J.J., Heying R., Boshoff D., Eyskens B., Gewillig M.*
- Multimodality 3D-Imaging for 3D-Guidance of catheter-based interventions in congenital heart disease  
*Glöckler M., Koch A., Dittrich S.*
- A 10-year single-centre experience in percutaneous interventions for multistage treatment of hypoplastic left heart syndrome  
*Moszura T., Dryzek P., Goreczny S., Mazurek-Kula A., Moll J.J., Sysa A., Bobkowski W., Moll J.A., Qureshi S.A.*
- Off-label Use of Percutaneous Pulmonary Valved Stents in the RVOT  
*Boshoff D., Cools B., Heying R., Troost E., Budts W., Louw J.J., Eyskens B., Gewillig M.*
- Melody transcatheter pulmonary valve implantation. Results from the Registry of the Italian Society of Pediatric Cardiology (SICP)  
*Butera G., Milanese O., Spadoni I., Piazza L., Donti A., Ricci C., Agnoletti G., Pangrazi A., Chessa M., Carminati M.*
- Percutaneous arterial duct stabilization in low-weight newborns (<2.5 kgs) with congenital heart disease and duct-dependent pulmonary circulation.  
*Santoro G., Castaldi B, Gaio G, Pignatiello M, Sorrentino R, Paolillo C, Russo M.G.*
- Stent Fenestration of the Failing Fontan Circulation – a single centre experience  
*Ramchandani B., Noonan P., Bhole V., Miller P., Dhillon R., Mehta C., de Giovanni J.V., Stumper O.*

**Fr 16:30-18:00**

**Fevzi Çakmak Hall**

**Abstract Session 9: General Cardiology II**

*Chair:* Andre Bozio (Lyon, FR), Sema Özer (Ankara, TR)

- 16:30  
09-1  
16:40  
09-2  
16:50  
09-3  
17:00  
09-4  
17:10  
09-5  
17:20  
09-6  
17:30  
09-7  
17:40  
09-8
- Clinical utility of Egami score system in patients with Kawasaki disease to predict coronary artery abnormality  
*Ishii M., Ogihara Y., Ogata S., Takanashi M., Honda T., Ando H., Sato K., Nakahata Y.*
- Vulnerability of Coronary Circulation after Norwood Type Operation  
*Saiki H., Seki M., Ishido H., Masutani S., Senzaki H.*
- Implications of Early Aortic Stiffening in Patients with Transposition of the Great Arteries after Arterial Switch Operation  
*Rickers C., Voges I., Jerosch-Herold J., Hedderich J., Hart C., Andrade A., Pham M., Gabbert D.D., Scheid M., Scheewe J., Kramer H.-H.*
- Coronary orifices patterning in outflow tract defects: a marker of outflow tract rotation during cardiac development.  
*Houyel L., Bajolle F., Laux D., Capderou A., Parisot P., Bonnet D.*
- Assessment of pulmonary endothelial function during invasive testing in children and adolescents with idiopathic pulmonary arterial hypertension  
*Apitz C., Zimmermann R., Kreuder J., Latus H., Jux C., Schranz D.*
- Effect of pulmonary vasodilators on clinical and Echocardiographic parameters in children with primitive pulmonary hypertension  
*Di Filippo S., Ducreux C., Joly H., Veyrier M., Bakloul M., Sassolas F., Bozio A., Di Filippo S.*
- Current medical treatment in Pediatric Pulmonary Hypertension (PH)-Insights from the Global Registry Tracking Outcomes and Practice in Pediatric Pulmonary Hypertension (TOPP)  
*Humpl T., Barst R.J., Kronmal R., Berger R.M.F., Moore D., Fasnacht Boillat M.S., Zuk M., Beghetti M., Schulze-Neick I.*
- Characteristics of PAH associated with pretricuspid shunts in the registry of the French PAH network  
*Bonnet D., Jaïs X., Rottat L., Szezepanski I., Lévy M, Gressin V, Sitbon O., Simonneau G.*

**Fr 18:00-20:00**

**Inönü Hall**

**TCPCCS Business Meeting**

**Fr 18:00-20:00**

**Fevzi Çakmak Hall**

**SECPCC Business Meeting**

**Fr 21:00-24:00**

**Gala Dinner-At “Said Halim Pasha Mansion”**

## SATURDAY 26 MAY 2012

- Sa 09:00-10:30**  
**30 Agustos Hall**
- Hereditary Arrhythmia Syndromes: An Update**  
*Chair:* Fabrizio Drago (Rome, IT), Katarina Hansesus (Lund, SE)
- 09:00 ECG screening for hereditary arrhythmias in neonates  
*Konrad Brockmeier*
- 09:15 Denervation therapy for malignant VT/VF syndromes  
*Michael Ackerman*
- 09:30 Device therapy in hereditary arrhythmias  
*Nico Blom*
- 09:45 New ECG signs: Early repolarisation syndrome  
*Juhani Junttila*
- Sa 09:00-10:30**  
**Inönü Hall**
- Joint Session: WG Intensive Care and Intervention**  
*Chair:* Eduardo Da Cruz (Denver, USA), Maria Del Mar Rodriguez (Granada, SP)
- 09:00 Patient on ECMO: timing and diagnostic workup  
*Brigitte Stiller*
- 09:15 The cyanotic patient early after operation  
*Cecile Tissot*
- 09:30 The hemodynamically unstable patient early after an operation  
*Evelyn Lechner*
- 09:45 The patient with chronic effusions after cavopulmonary shunts  
*Ina Michel-Behnke*
- 10:00 The patient who can not be weaned off ventilation  
*Joan Sanchez de Toledo*
- Sa 10:30-11:00**  
**Coffee Break, Posters and Exhibition**
- Sa 11:00-12:30**  
**30 Agustos Hall**
- Interventions: Failures, Complications and Successes**  
*Chair:* Gianfranco Butera (Milan, IT), Andreas Eicken (Munich, DE)
- Sa 11:00-12:30**  
**Inönü Hall**
- Abstract Session 10: GUCH**  
*Chair:* Andras Szatmari (Budapest, HU), Eric Meijboom (Lausanne, CH)
- 11:00 O11-1 The impact of acoustic radiation force impulse sonoelastography to assess the liver stiffness in patients after Fontan procedure  
*Yasukochi S., Takigiku K., Tazawa S., Watanabe S., Mori H., Odanaka Y., Akazawa Y., Harada Y., Sakamoto T.*
- 11:10 O11-2 Right atrial size is a strong predictor of arrhythmia in patients with repaired tetralogy of Fallot.  
*Bonello B., Kempky A, Uebing A, Li W, Kilner P.J, Pennell D.J, Gatzoulis M.A, Diller G.P, Babu-Narayan S.V.*
- 11:20 O11-3 Closure of Atrial Septal Defect in the adult.  
*Nyboe C., Olsen M.S., Nielsen-Kudsk J.E., Hjortdal V.E.*
- 11:30 O11-4 Long-term outcome of discrete subaortic stenosis in adults: a multicenter study  
*Van der Linde D., Takkenberg J.J.M., Rizopoulos D., Heuvelman H.J., Witsenburg M., Budts W., Van Dijk A.J.P., Bogers A.J.J.C., Yap S.C., Silversides C.K., Oechslin E.N., Roos-Hesselink J.W.*
- 11:40 O11-5 Ross Procedure: Prevalence and predictors of aortic autograft dysfunction and aortic dilatation in 97 patients during mid-term follow-up  
*Zimmermann C., Weber R., Greutmann M., Dave H., Valsangiacomo Büchel E.R., Prêtre R., Müller C., Seifert B., Kretschmar O., Attenhofer Jost C.H.*
- 11:50 O11-6 Long term outcome of arterial switch operation performed in neonates with the transposition of the great arteries.  
*Michalak K.W., Moll J.A., Młodzik K., Moll M., Moszura T., Dryżek P., Kopala M., Moll J.J.*
- 12:00 O11-7 Can the echocardiography and NT-proBNP replace magnetic resonance imaging to study the right ventricle in volume overload?  
*Balducci A., Hasan T., Donti A., Gesuete V., Fabi M., Urru M., Prandstraller D., Formigari R., Ragni L., Pace C.N., Gargiulo G., Picchio F.M., Bonvicini M.*
- 12:10 O11-8 Cerebrovascular findings on MRI compared to medical history in patients with cyanotic congenital heart disease  
*Jensen A.S., Thomsen C., Idorn L., Søndergaard L.*

Sa 12:30-13:30  
30 Ağustos Hall

**Keynote Lecture and Closing Remarks**

Chair: Shakeel Qureshi (London, GB), Alpay Çeliker (Istanbul, TR)

12:30

Riding with the kids. Pros, cons and hitchhiking  
*Egemen Tüzün*

**WEDNESDAY, MAY 23 TO SATURDAY, MAY 26, 2012**

08:00-18:00

**Posters**

**Arrhythmia/electrophysiology**

- P-1 Pharmacologic cardiac resynchronization in children.  
*Paech C., Flosdorff P., Gebauer R.A.*
- P-2 Optimal Dose Of Adenosine Effective For Treating Supraventricular Tachycardia In Children  
*Qureshi A.U., Sadiq M.*
- P-3 Effects of flecainide therapy on arrhythmias and inappropriate shocks in children with catecholaminergic polymorphic ventricular tachycardia  
*Jacquemart C., Massin M.*
- P-4 Prevalence, Mutation Spectrum and Cardiac Phenotype of the Jervell and Lange-Nielsen Syndrome in Sweden  
*Winbo A., Stattin E.L., Diamant U.B, Jensen S.M., Rydberg A.*
- P-5 Gastrointestinal symptoms, signs and associated iron-deficiency anaemia in the Jervell and Lange-Nielsen Syndrome -Clinical Phenotype Beyond the SurdoCardiac Syndrome  
*Winbo A., Sandström O., Palmqvist R., Rydberg A.*
- P-6 Diagnosis of Congenital Long QT Syndrome: Do all Clinically Suspected Patients warrant Genetic Testing?  
*Chockalingam P., Hofman N., van den Berg M.P., van den Heuvel F., Clur S.A.B., Blom N.A., Wilde A.A.M.*
- P-7 Outcome of children and adolescents undergoing invasive testing for asymptomatic Wolff-Parkinson-White preexcitation  
*Kubus P., Vit P., Gebauer R.A., Materna O., Janoušek J.*
- P-8 Management Of T-Wave Oversensing After Extracardiac ICD Implantation In A Pediatric Patient With Brugada Syndrome  
*Kriebel T., Buob A., Raus E., Schneider, H.E., Krause U., Sigler M., Paul T.*
- P-9 Paroxysmal tachycardia with wide QRS complexes, right bundle branch block pattern and left axis deviation: A seldom electrophysiological mechanism.  
*Kriebel T., Schneider, H.E., Krause U., Sigler M., Steinmetz M., Paul T.*
- P-10 Handheld ECG in analysis of arrhythmia and HRV in children with Fontan circulation.  
*Alenius Dahlqvist J., Karlsson M., Wiklund U., Hörnsten R., Rydberg A.*
- P-11 Radiofrequency catheter ablation for atrial tachycardia in patients with complex congenital heart disease after intracardiac operation  
*Toyohara K., Takeuchi D., Nakanishi T.*
- P-12 Predictive factors for future symptoms and dropout in patients with long QT syndrome in a single pediatric cardiovascular center in Japan  
*Yoshinaga M., Kucho Y., Ninomiya Y., Tanaka Y.*
- P-13 Assessment of Performance of various QT correction formulae in Infants and Children  
*Benatar A., Dewals W., Decraene T., Feenstra A.*
- P-14 Assessment of AV Conduction Following Cryoablation of Atrioventricular Nodal Reentrant Tachycardia in Children  
*Kiplapinar N., Ergul Y., Akdeniz C., Saygi M., Ozyilmaz I., Tuzcu V.*
- P-15 Catheter Ablation of Ventricular Tachycardia in Children Using a Limited Fluoroscopy Approach  
*Akdeniz C., Ozyilmaz I., Ergul Y., Ozturk E., Tanidir I.C., Tuzcu V.*
- P-16 Combination of sinus node dysfunction and intestinal pseudo-obstruction in children and young adults: about 11 cases of this undiscribed association  
*Chetaille Ph., Côté JM., Houde C., Andelfinger G.*
- P-17 Idiopathic ventricular arrhythmias in children: factors determining the state of intracardiac hemodynamics  
*Chernyshev A., Kovalev I., Zavadovsky K., Popov S.*
- P-18 Minimally Invasive Method for Epicardial Implantation of Implantable Cardioverter Defibrillators in Children  
*Ergul Y., Haydin S., Saygi M., Ozyilmaz I., Ozturk E., Akdeniz C., Tuzcu V.*

- P-19 Cardiac Resynchronization in a 1½ Year Old Girl With Dilated Cardiomyopathy  
*Hauser J., Pees C., Khazen C., Zimpfer D., Michel-Behnke I.*
- P-20 Electrophysiological properties of the atrioventricular node, slow and fast pathway in children at long term follow up after slow pathway radiofrequency catheter ablation  
*Sileikiene R., Zebiene M., Kasparaviciene J., Ziteliene A, Sileikyte V.*
- P-21 Radiofrequency Ablation and Cryoablation in Patients with Multiple Arrhythmic Focus  
*Akin A., Karagöz T., Ertuğrul İ., Aykan H.H., Özer S., Alehan D., Özkutlu S.*
- P-22 Ablation of right-sided accessory pathways in children and patients with congenital heart disease using a new 3D Mapping system (NavX- Velocity ®)  
*Schoen P., Ammar S., Reents T., Fichtner S., Pavaci H., Hess J., Deisenhofer I., Hessling G.*
- P-23 Multidisciplinary approach in patients with supraventricular arrhythmias late after Fontan surgery: Transcatheter and surgical ablation.  
*Foresti S., Giamberti A., Carminati M., Cappato R., Negura D., Micheletti A., Lupo P.P., Ali H., De Ambroggi G., Heles M., Chessa M.*
- P-24 Management of neonates with congenital complete heart block – a tertiary paediatric cardiothoracic unit experience  
*Starling L.D., Vyas D., Penford G., Saeed I., Till J., Slavik Z., Desai A.*
- P-25 Arrhythmia characterization in catecholaminergic polymorphic ventricular tachycardia and CPVT-related phenotypes in children – a single centre experience  
*Szepesváry E., Környei L., Szatmári A.*
- P-26 Lead extraction – growing problem in children with endocardial pacing  
*Bieganowska K., Miszczak-Knecht M., Kaszuba A., Brzezinska-Paszke M., Rękawek J., Birbach M., Lipiński W., Daszkowska-York J., Kutarski A.*
- P-27 Effects of Umbilical Venous Catheters on Arrhythmia and Heart Rate Variability in Premature Newborns  
*Babaoglu K., Seringeç M., Altun G., Uzun O., Oncel S., Arisoy A.E.*
- P-28 An insight into the autonomic mechanisms underlining the reflex syncope in children and adolescents  
*Laranjo S., Trigo C., Tavares C., Oliveira M., Rocha I., Pinto F.F.*
- P-29 Heart Rate Variability Alterations in Children with Euthyroid Hashimoto Thyroiditis  
*Kilic A., Gulgun M., Tascilar M.E., Yokusoglu M.*
- P-30 CRYOABLATION FOR PARAHISSIAN ACCESSORY PATHWAYS  
*Ertuğrul İ., Karagöz T., Yıldırım İ., Özer S.*
- P-31 Acute Effectiveness of RF Ablation for Idiopathic Ventricular Arrhythmias in Children  
*Miszczak-Knecht M., Bieganowska K., Szumowski Ł., Brzezinska-Paszke M., Pręgoska K., Posadowska M., Turska-Kmieć A.*
- P-32 Long-term single centre study on epicardial pacing leads in children and patients with congenital heart disease  
*Fink B., Schneider W., Ziemer G., Gass M., Hofbeck M., Kerst G.*
- P-33 Postoperative junctional ectopic tachycardia in paediatric patients  
*Gebauer R.A., Weidenbach M., Kostelka M., Paech C.*
- P-34 Catecholaminergic Polymorphic Ventricular Tachycardia and Left Ventricular Noncompaction Cardiomyopathy: a case report and review of the literature.  
*Tavera M.C., Bloise R., Napolitano C., Monteforte N., Stara R., Tola G., Giardina A., Scorcu G.P., Porcu M., Priori S., Tumbarello R.*

#### Basic science

- P-35 Possible Involvement of the Natural Immune Systems in the Pathogenesis of Kawasaki Disease  
*Nakamura A., Hamaoka A., Fujii M., Yahata T., Suzuki C., Yoshioka A., Niwa N., Ikeda K., Hamaoka K.*
- P-36 Infant with tacrolimus induced hypertrophy after heart transplantation – increased expression of CRTC-1, but not CRTC-2 and -3.  
*Steinmetz M., Quentin T., Poppe A., Paul T., Oetjen E.*
- P-37 Creation of a single-center DNA-bank of congenital heart disease with focus on cardiac phenotype  
*Bonnet D., Laux D., Bajolle F., Lyonnet S.*
- P-38 Predicted upper limits for left ventricular internal diameter at end diastole in children and adolescent athletes  
*Bartkeviciene A., Baksiene D., Ziliukas G., Razbadauskas A.*
- P-39 Experimental Study on Etiological Participation of Oxidative Stress in Vasculitis by Kawasaki Disease  
*Suzuki C., Yahata T., Hamaoka A., Fujii M., Nakamura A., Miura N., Ikeda K., Hamaoka K.*

- P-40 Simulator training improves beginner's skills in performing echocardiography in congenital heart disease  
*Weidenbach M., Wagner R., Wild F., Berlage T., Razek V.*
- P-41 Developmental abnormalities of the fourth primordial pharyngeal arch  
*Sandrio S., Eichhorn J.G., Gorenflo M., Karck M., Loukanov T.*
- P-42 Exome Sequencing in Syndromic Patients with Congenital Heart Disease performing Trio Analysis  
*Louw J.J., Jia Y., Corveleyn A., Gewillig M., Devriendt K.*
- P-43 A family with Myotonic Dystrophy (DM1) associated with Sudden Death, Long QT and a Brugada-like ECG pattern in different affected relatives.  
*Ashcroft K., Brown E., Willcoxson F., Slack J., Cowan C., Thomson J.*
- P-44 Serotonin receptor-related coronary vasomotor function in young miniaturized pigs is additively impaired by streptozotocin-induced diabetes and Chlamydia infection but protected by simvastatin  
*Liuba P., Odermarsky M., Pesonen E., Kornerup-Hansen A.*
- P-45 Zebra fish heart slices: A new model to investigate contractile properties of the heart  
*Adelmann R., Hausteim M., Hescheler J., Brockmeier K., Khalil M.*
- P-46 Effects of Hypothermia on RBM3 and CIRP Cold-Shock Proteins Expression in Murine Organotypic Hippocampal Slice Cultures  
*Tong G., Endersfelder S., Rosenthal L.-M., Buehrer C., Berger F., Schmitt K.R.L.*
- P-47 Hypothermia reduces inflammation in a co-culture model of neuronal and microglial cells  
*Mochner J., Wollersheim S., Tong G., Kraus A., Berger F., Schmitt K.R.L.*

#### End-stage heart and lung disease

- P-48 "Idiopathic" cardiomyopathy in children is highly associated with infectious genome presence in the myocardium  
*Apostolopoulou S.C., Kantzis M., Tsoutsinos A., Kiaffas M., Laskari C.V., Rammos S.*
- P-49 Pulmonary CT number demonstrates congestive lung in patients with simple total anomalous pulmonary venous connection  
*Hamamichi Y., Ishii Y., Ishii R., Terashima Y., Narita J., Kawazu Y., Inamura N., Kayatani F., Kawata H., Kishimoto H.*
- P-50 Heart Transplantation in Adult patients with Congenital Heart Disease  
*Di Filippo S., Ninet J., Ducreux C., Henaine R., Veyrier M., Sassolas F., Metton O., Bozio A., Boissonnat P., Sebbag R., Roussoulières A., Di Filippo S.*
- P-51 Ventricular assist device as a bridge to heart transplantation in children with an end-stage heart failure-own experience.  
*Chodor B., Przybylski R., Pacholewicz J., Pawlak S., Sliwka A., Lapa P., Grzybowski A., Wierzyk A., Bialkowski J.*
- P-52 Extensive myocardial infarction (MI) in a 11year old girl – case report  
*Hutter D., Pfammatter J.-P., Pavlovic M., Kadner A., Schönhoff F., Martinelli M., Mohaci P., Bösch C., Wagner B., Stambach D.*
- P-53 The relationship between intima media thickness of pulmonary artery and biochemical parameters in children with Eisenmenger syndrome  
*Narin N., Yilmaz E., Baykan A., Sezer S.S., Pamukcu O., Onan S.H., Baykan Z., Uzum K.*

#### Fetal cardiology

- P-55 Prenatal diagnosis of isolated total anomalous pulmonary venous connection: a series of fourteen cases  
*Bonnet D., Laux D., Fermont L., Le Bidois J., Stirnemann J., Bajolle F., Boudjemline Y.,*
- P-56 Risk factors associated with in utero demise in fetuses with congenital heart disease: A case/control study  
*MacColl C.E., Manlhiot C., McCrindle B.W., Page C., Miner S.E.S., Jaeggi E., Nield L.E.*
- P-57 Fetal ventricular aneurysms and diverticula: Nine new cases and a review of the current literature  
*Jones C.B., Simpson J.M., Miller O.I., Sharland G.K.*
- P-58 Various coexisting forms of fetal arrhythmias associated with fetal atrial septal aneurysm  
*Yozgat Y., Kilic A., Kurtulmus S., Oner T., Demirpence S., Doksoz O., Mese T., Tavli V.*
- P-59 Role of decreasing maternal ingestion of polyphenol-rich foods on fetal ductus arteriosus dynamics in normal pregnancies: an open clinical trial.  
*Zielinsky P., Piccoli A., Vian I., Nicoloso L.H., Zilio A., Oliveira A., Pizzato P., Bender L., Barbisan C., Busato S., Lopes M., Naujorks A., Frajndlich R.*
- P-60 10 Year Review of Outcome of Fetal Arrhythmias in Wales  
*Babaoglu K., Uzun O., Ayhan Y.I., Massias S., Sinha A., Conner C., Beattie B.*

- P-61 Features and outcomes of cases with agenesis/dysplasia of the pulmonary valve diagnosed in fetal life  
*Fesslova V., Boschetto C., Brankovic J., Piazza L., Butera G., Arcidiacono C., Giamberti A., Pomé G., Carminati M., Frigiola A.*
- P-62 Intracardiac Tumors in Neonates: Report of 2 Cases of Myxomas.  
*Hubrechts J., Moniotte S., Carbonez K., Barrea C.*
- P-63 Prenatal diagnosis and management of fetal arrhythmias  
*Fratta F., Di Salvo G., Morelli C., Ricci C., Di Pietto L., D'Alto M., Romeo E., Paolillo C., Sorrentino R., Grasso A., Pignatiello M., Iacono C., Esposito R., Russo M.G.*
- P-64 Congenital Heart Malformations in the fetus with intracardiac echogenic focus in low vs high risk pregnancies .  
*Asleh N., Nseir T., Haj N., Azayzeh H.*
- P-65 A questionnaire study of Ro/ SSA autoantibody mediated congenital heart block indicate need for increased information, support and highly specialized medical care  
*Tingström J., Hjelmstedt A., Welin Henriksson E., The Swedish Congenital Heart Block Study Group, Sonesson S.-E., Wahren-Herlenius M.*
- P-66 Ro52 autoantibody-positive women's experience of being pregnant and giving birth to a child with congenital heart block  
*Tingström J., Sonesson S.-E., Welin Henriksson E., Wahren-Herlenius M.*
- P-67 Assessment of diastolic function after cardioversion of the fetal supraventricular tachycardia using pulsed Doppler and myocardial tissue Doppler.  
*Hamela-Olkowska A., Dangel J.H.*
- P-68 Potential Added Value of Bidimensional Myocardial Strain in Prenatal Diagnosis of Aortic Coarctation  
*Fratta F., Di Salvo G., Ricci C., Grasso A., Pignatiello M., Paolillo C., Sorrentino R., Russo M.G.*
- P-69 Foetal Dysfunction of the Arterial Duct: Clinical Spectrum and Outcome  
*Eyskens B., De Catte L., Heying R., Cools B., Brown S., Louw J.J., Gewillig M.*
- P-70 Assessment of Diastolic Ventricular Function in Fetuses of Gestational Diabetic Mothers Using Tissue Doppler  
*Pac F.A., Balli S., Ece İ.*
- P-71 Impact of prenatal diagnosis of congenital heart disease on neonatal outcome in a regional case controlled study (Canton of Vaud, Switzerland)  
*Meijboom E., Rossier M.C., Tornay-Alvarez A., Mivelaz Y., Sekarski N., Addor M.C., Vial Y.*
- P-72 Heart failure evaluation using the Cardiovascular Profile Score in fetal right heart defects  
*Neves A.L., Mathias L., Leshko J., Linask K.K., Henriques-Coelho T., Areias J.C., Huhta J.C.*
- P-73 Abnormal cerebral and umbilical doppler flow values in the fetuses with hypoplastic left heart syndrome  
*Radzimska-Chrusciel B., Respondek-Liberska M., Rudziński A.*
- P-74 Aneurysm Of Left Atrial Appendix Diagnosed In The Intrauterine Period  
*Besikci R., Altunyuva U.S., Gunay E., Cicek S., Tosun O., Akalin F.*
- P-75 Prenatal Diagnosis of Total Anomalous Pulmonary Vein Connection: Our Institutional Experience.  
*Rodríguez A., Álvarez T., Florez S., Centeno-Jimenez, M., Medrano-Lopez, C., Villanueva N., Maroto-Alvaro, E.*
- P-76 New national program in prenatal aortic valvuloplasty – preliminary experience  
*Dangel J.H., Debska M., Kolesnik A, Wloch A., Chojnicki M., Dryzek P., Tulzer G, Arzt W.*
- General paediatric cardiology**
- P-77 The experience of being diagnosed with hypertrophic cardiomyopathy through family screening in childhood and adolescence  
*Bratt E.-L., Sparud-Lundin C., Östman-Smith I., Axelsson Å.B.*
- P-78 Normalization of Haemostatic Alterations in Overweight Children with weight loss due to lifestyle intervention  
*Fritsch P., Köstenberger M., Fritsch M., Heinzl B., Nagel B., Rehak T., Mangge H., Gamillscheg A., Muntean W., Reinehr T.*
- P-79 Left ventricular in obese and overweight asymptomatic adolescents may be affected by higher arterial blood pressure, as compared with lean adolescents  
*Kepuska A., Batalli A., Zejnullahu M., Azemi M., Shala M., Bajraktari G.*
- P-80 Tricuspid annular peak systolic velocity (TAPSV) in children and young adults with pulmonary artery hypertension secondary to congenital heart diseases and tetralogy of Fallot: comparison with MRI data  
*Koestenberger M., Nagel B., Fritsch P., Ravekes W., Avian A., Heinzl B., Sorantin E., Cvirm G., Gamillscheg A.*

- P-81 Interleukin-21 Receptor Gene Polymorphisms in Kawasaki disease  
*Lee H.Y.*
- P-82 Chronic hypoxemia leads to reduced serum IGF-I levels in cyanotic congenital heart disease  
*Hashemizadeh H.*
- P-83 Mildly functional decline of left ventricle is detected by systolic time intervals in pediatric patients with chronic peritoneal dialysis  
*Hamamichi Y., Kawazu Y., Inamura N., Kayatani F., Satomura K.*
- P-84 Mild extension of left ventricle engages with elevation of brain natriuretic peptide in patients with atrial septal defect  
*Hamamichi Y., Ishii Y., Ishii R., Terashima Y., Narita J., Kawazu Y., Inamura N., Kayatani F.*
- P-85 Usability of QTc Dispersion for the Prediction of Orthostatic Intolerance Syndromes  
*Karatas Z., Alp H., Sap F., Altin H., Baysal T., Karaarslan S.*
- P-86 Pulmonary arterial hypertension in congenital heart anomalies with left-right shunt  
*Begić Z., Dinarević S., Halimić M., Kadić A.*
- P-87 Left ventricular function, natriuretic peptide type B and troponin T levels at onset of diabetes type I in children (a pilot study)  
*Holmgren D., Forsander G.*
- P-88 The Evaluation of the Frequency and Echocardiographic Features of Cardiovascular Anomalies Among the Families of the Patients with Bicuspid Aortic Valve or Other Left-sided Cardiovascular Anomalies  
*Demir F., Karadeniz C., Atalay S., Tekin M., Tutar E.*
- P-89 Nowadays, Children With Congenital Heart Disease are not Limited in Their Submaximal Exercise Performance  
*Müller J., Böhm B., Oberhoffer R., Hess J., Hager A.*
- P-90 Pulmonary hypertension in scimitar syndrome : a series of 90 consecutive patients from a single centre  
*Bonnet D., Chemin A., Delacourt C., Boudjemline Y., Ou P., Lévy M.*
- P-91 Respiratory outcome in children with scimitar syndrome  
*Bonnet D., Chemin A., Levy M., Lebourgeois M., Boudjemline Y., Delacourt C.*
- P-92 Are there any associations between the cardiac septal defects and ROCK2 gene polymorphisms at the childhood? : A case-control study  
*Baspinar O., Aksoy M., Uygun H., Demiryurek S., Oztuzcu S., Cengiz B., Irdem A., Col-Araz N., Kilinc M., Coskun M.Y.*
- P-93 Could be useful to measurement short-term analysis of heart rate variability to access autonomic function in obese children and its relationship with metabolic syndrome?  
*Baspinar O., Altuncu M.E., Keskin M., Kilinc M.*
- P-94 Determinant of increased type B natriuretic peptide (BNP) in acute phase of Kawasaki disease  
*Suda K., Kishimoto S., Kudo Y., Nishino H., Takahashi T., Okamura H., Teramachi Y., Yoshimoto H., Iemura M., Matsuishi T*
- P-95 Ebstein' s anomaly: fetal presentation and neonatal outcome  
*Bordese R., Corleto A., Tibaldi M., Riggi C., Agnoletti G.*
- P-96 Smart nature. Aortico-left ventricular (Ao-LV) tunnel bypassing congenital critical aortic stenosis  
*Weidenbach M., Cho M., Daehnert I., Kostelka M.*
- P-97 Evaluation of the incidence and echocardiographic findings of congenital heart diseases in children with Down Syndrome in the Middle Anatolia of Turkey  
*Altin H., Karataş Z., Alp H., Şap F., Baysal T., Karaarslan S., Yıldırım M.S.*
- P-98 Dilatation of aortic root, arachnodactyly, and arthrogyrosis in a newborn as early manifestation of a Marfan syndrome with a new splice acceptor mutation  
*Langenbach J., Chen C., Pillekamp F., Mayer K., Schmidt K.G., Donner B.C.*
- P-99 Right ventricular distress influences the elevation of brain natriuretic peptide in symptomatic infants with ventricular septal defects  
*Hamamichi Y., Ishii Y., Ishii R., Terashima Y., Narita J., Kawazu Y., Inamura N., Kayatani F., Kawata H., Kishimoto H.*
- P-100 P-wave dispersion in children with rheumatic heart disease  
*Şap F., Baysal T., Karataş Z., Altin H., Alp H., Karaarslan S.*
- P-101 Paediatric myocarditis: new aspect from a case series  
*Mogyorósy G., Berkes A., Felszeghy E., Kovács T.*
- P-102 Assessment of left ventricular functions with Tissue Doppler, Strain and Strain Rate Echocardiography in children with Juvenile Idiopathic Arthritis: An Observational Study  
*Örűn U.A., Yılmaz O., Ceylan Ö., Örűn U.A., Özgür S., Karademir S., Doğan V., Keskin M., Erdoğan Ö.*

- P-103 Physical Activity Mediates Blood Pressure in Overweight Adolescents Without Abdominal Adiposity  
*McCordle B.W., Tyrrell P., Manlihot C., Gibson D., Chahal N., Stearne K., Makerewich O., Fisher A., Dobbin S.W.*
- P-104 Hypoxic perinatal cardiomyopathy-diagnosis and evolution  
*Dimitriu L., Dimitriu A.G.*
- P-105 Cardiovascular Abnormalities in Williams Syndrome; 20 Years' Experience in Istanbul  
*Dindar A., Ergul Y., Nisli K., Kayserili H., Karaman B., Basaran S., Koca B., Aydogan U., Omeroglu R.E.*
- P-106 Cardiac involvement in infant of diabetic mother:diagnosis and follow up of evolution  
*Dimitriu L., Dimitriu A.G.*
- P-107 Cardiac biomarkers for early diagnosis of anthracycline induced cardiotoxicity in children with malignant diseases  
*Dimitriu L., Mandric C., Miron I., Dimitriu A.G.*
- P-108 The 12-Lead Surface ECG in Patients with Congenital Defects of the Atrioventricular Canal: Insights into the Adaptation of the AV Conduction to the Variation of the Patients' Heart Rate  
*Cassater D., Prioli M.A., Tomasi L., Cristofaletti A., Rossetti L., Luciani G.B., Vassanelli C.*
- P-109 Clinicopathological investigation on dilated cardiomyopathy in infants and children: The role of endomyocardial biopsy and biochemical markers.  
*Yonesaka S., Takahashi T., Otani K., Jun S., Konno Y., Sato T., Kitagawa Y., Eto S., Sato A., Ichinose K., Kinjo M.*
- P-110 Rhythm and Conduction Abnormalities in Children with Acute Rheumatic Fever: Are They Specific to the Disease?  
*Ceviz N., Olgun H., Celik V.*
- P-111 Clinical course and the impact of interstage monitoring after Norwood I and Hybrid procedure  
*Knirsch W., Bertholdt S., Stoffel G., Dave H., Prêtre R., Kretschmar O.*
- P-112 Clinical Characteristics of Patients with Acute Rheumatic Fever (ARF) and Rheumatic Heart Disease, Evaluation of the Long-Term Follow-Up Results  
*Semizel E., Bostan O.M., Oztürk R., Uysal F., Cil E.*
- P-113 Echocardiographic Diagnosis of Acute Rheumatic Silent Carditis in Children and Comparison of the Features of Patients with Clinical and Silent Carditis  
*Atalay S., Pekpak E., Karadeniz C., Demir F., Tutar E.*
- P-114 Truncal valve dysplasia is related to abnormalities of the coronary arteries: a pathological study  
*Liguori G.R., Jatene M.B., Aiello V.D.*
- P-115 Myocardial performance during and after therapeutic hypothermia for perinatal asphyxia in term neonates  
*Nestaas E., Skranes J., Støylen A., Fugelseth D.*
- P-116 Correlation between calcification and oxidative stress in chronic Kawasaki disease  
*Yahata T., Suzuki C., Hamaoka A., Fujii M., Ikeda K., Hamaoka K.*
- P-117 The first treatment experience of a patient with functional single ventricle and homeostasis pathology  
*Janulevich O., Kovalev I., Ershova N., Podoksenov A., Pavlichev G., Nikolishin A., Krivoshechekov E., Minaycheva L.*
- P-118 Close and remote results of endovascular treatment of aorta coarctation in children.  
*Plotnikova I., Chernenkaya A., Varvarenko V., Martsenkevich G., Filippov G.*
- P-119 Tissue Doppler Imaging in very preterm infants. The alteration of myocardial performance during the first 24 hours of life.  
*Lee A., Nestaas E., Liestøl K., Brunvand L., Fugelseth D.*
- P-120 Genetic approach to immunopathogenesis of acute rheumatic fever  
*Parlar A., Dogrusoz B.*
- P-121 Chest pain – the most common cardiac causes in pediatric age group  
*Dorner S., Gverieri M.*
- P-122 The Evaluation of P Wave Dispersion, QT Dispersion, QTc and QTc Dispersion On Early Diagnosis Of Autonomic Dysfunction in Children and Adolescents with Type-1 Diabetes Mellitus  
*Bostan O.M., Ozboyaci E., Semizel E., Uysal F., Cil E.*
- P-123 Myocardial Tissue Doppler Echocardiographic evaluation of preterm infants with bronchopulmonary dysplasia at 2 to 4 year of age  
*Levent E., Koroglu O.A., Yalaz M., Kültürsay N., Ozyurek A.R.*
- P-124 Progression of ascending aorta dimensions in pediatric patients with bicuspid aortic valve  
*Trippel A., Ammann R.A., Bruhin S., Pfammatter J.-P., Pavlovic M.*



- P-125 Pulmonary Artery Sling: A Rare Cause Of Recurrent Aspiration Pneumonia  
*Baykan A., Ozyurt A., Serhatlioğlu F., Mavili E., Argun M., Uzum K., Narin N.*
- P-126 Comparison between tilt table and active orthostatic testing for syncope simulation and hemodynamic pattern investigation in children  
*Kinciniene O., Lukoseviciute R.*
- P-127 Electrocardiographic changes in children with pectus excavatum  
*Jurko A., Jurko A.Jr., Molnar M., Rush K., Durdik P.*
- P-128 Procedural safety, hemodynamic and histological findings of myocardial biopsy in children  
*Quandt D., Niesse O., Schmitz A., Kandolf R., Kretschmar O., Knirsch W.*
- P-129 Recurrent syncope in the child – don't forget the coronary arteries. Atresia of the left coronary artery in a 9 years-old boy.  
*Foglia C., Knirsch W., Balmer C., Dave H., Pretre R., Valsangiacomo Büchel E.R.*
- P-130 Significance of Tenascin-C in Diagnosis of Chronic Rheumatic Heart Disease  
*Karatas Z., Baysal T., Sap F., Altin H., Cicekler H.*
- P-131 A New Biochemical Marker in Diagnosis of Acute Rheumatic Fever: Ischemia Modified Albumin  
*Karatas Z., Baysal T., Sap F., Alp H., Mehmetoglu I.*
- P-132 Evaluation of Serum Ischemia Modified Albumin Levels in Children with Acute Rheumatic Fever Before and After Therapy  
*Toker A., Karatas Z., Altin H., Karaarslan S., Cicekler H.*
- P-133 Anatomopathological analysis of the valvar dysplasia and aortic arch abnormalities in common arterial trunk  
*Liguori G.R., Jatene M.B., Aiello V.D.*
- P-134 P wave duration and dispersion in children with uncomplicated FMF  
*Arslan D., Oran B., Peru H., Yazililas F., Cimen D., Vatansev H., Cimen Ö.*
- P-135 Congenital heart disease in an infant with pseudohypoaldosteronism type 2 (Gordon syndrome)  
*Doneray H., Olgun H., Ceviz N.*
- P-136 Growth-differentiation factor-15 and Tissue Doppler imaging in Detection of Asymptomatic Late-Onset Anthracycline Cardiomyopathy in Childhood Cancer Survivors  
*Arslan D., Cihan T., Köse D., Vatansev H., Çimen D., Köksal Y., Oran B., Akyürek F.*
- P-137 Reduced left ventricular end-diastolic volume in children with hypertrophic cardiomyopathy can be reproducibly measured with 3-D echocardiography and correlates with abnormal physiology  
*Allahyari P., Östman-Smith I.*
- P-138 The Use of Artesunate in a child with acute myocarditis caused by HHV 6 virus  
*Hakacova N., Higgins T.,*
- P-139 Evaluation of the cardiovascular changes in the children with bicuspid aortic valves  
*Hanedan Onan S., Baykan A., Sezer S.S., Narin F., Mavili E., Baykan Z., Uzum K., Narin N.*
- P-140 The importance of intraoperative transesophageal echocardiography in the evaluation of congenital heart diseases: 2 years experience of our center  
*Guzeltas A., Odemis E., Tanidir C., Bilici M., Haydin S., Ereğ E., Bakir I.*
- P-141 Clinical profile of hypertrophic cardiomyopathy in children – own experience  
*Ziolkowska L., Kawalec W., Boruc A., Turska-Kmieć A., Bieganowska K., Daszkowska-York J.*
- P-142 Risk stratification and prevention of sudden cardiac death in children with hypertrophic cardiomyopathy.  
*Ziolkowska L., Kawalec W., Turska-Kmieć A., Brzezinska-Paszke M., Boruc A., Raszek M.*
- P-143 Outcome of Congenital Heart Defects Associated with 22q11.2 Deletion  
*Uzun O., Tucker D., Babaoglu K., Massias S., Kumar D., Wilson D.G.*
- P-144 Pulmonary hypertension in preterm infants admitted to a neonatal intensive care unit  
*Schmidt P., Ali Z., Dodd J., Jeppesen D.L.*
- P-145 Usefulness of telemedicated echocardiograms for neonates admitted to NICU  
*Miura M., Saganuma H., Nagata S., Ohtsuki M., Kishiro M., Shimizu T.*
- P-146 Prognostic role and diagnostic accuracy of Urinary Neutrophil Gelatinase-Associated Lipocalin in the Early Diagnosis of Acute Renal Damage After Pediatric Cardiac Surgery.  
*Cantinotti M., Storti S., Arcieri L., Lorenzoni V., Assanta N., Chicci D., Parri M.S., Cau S, Moschetti R, Murzi B, Spadoni I.*
- P-147 Extra-cardiac malformations, chromosomal abnormalities and clinical syndromes in neonates with congenital heart disease  
*Panagiotopoulou O., Karatza A., Mantagou L., Tzifas S., Sinopidis X., Dimitriou G., Mantagos S.*
- P-148 Results of total correction of complete atrio-ventricular canal (CAVC) depending on coexistence of Down syndrome in children  
*Kuzma J., Werynski P., Rudzinski A.*

- P-149 Outcome Of Critical Chd: Comparison Between Prenatal And Post-Natal Diagnosis In 548 Neonates  
*Fratia F., Carrozza M., Pignatiello M., Grasso A., Paolillo C., Sorrentino R., Morelli C., Ricci C., Iacono C., Palladino M.T., Di Salvo G., Caianiello G., Russo M.G.*
- P-150 Patent Ductus Arteriosus and Pulmonary Hypertension in a Child with 49,XXXXY Syndrome  
*Argun M., Akin M.A., Kurtoglu S., Sarici D., Ozyurt A., Pamukcu O., Baykan A.*
- P-151 Central Blood Pressure and Augmentation Index in the Pediatric Age-Group  
*Elmenhorst J., Müller J., Böhm B., Barta C., Oberhoffer R.*
- P-152 First results of “Catch the (pulse) wave”-Is pulse wave velocity in children feasible to measure with an oscillometric device?  
*Elmenhorst J., Engelhardt A., Müller J., Böhm B., Barta C., Hulpke-Wette M., Oberhoffer R.*
- P-153 The prevalence of persistent Left Superior Vena Cava in patients with and without congenital heart disease  
*Abdullah G.S., El Segaiir M., Galal M.O.*
- P-154 The Role of N-Terminal Pro-Brain Natriuretic Peptide in the Diagnosis and Management of Congestive Heart Failure due to Dilated Cardiomyopathy in Children  
*Narin N., Baykan A., Saygin B., Ozyurt A., Sezer S.S., Zararsiz G., Uzum K.*
- P-155 The Role of the Leptin-to-Adiponectin Ratio in Cardiovascular Prevention in Childhood. First results from the “Get Fit – Stay Healthy” Project  
*Böhm B., Braun S.L., Müller J., Elmenhorst J., Barta C., Starringer-Kirchmair G., Oberhoffer R.*
- P-156 Cardiac rhabdomyomas associated with tuberous sclerosis complex in childhood in 11 cases  
*Kocabaş A., Ekici F., Çetin İ.İ., An M.E., Demir H.A., Değerliyurt A., Güven A.*
- P-157 What's the outcome of carditis in Children with Sydenham's Chorea  
*Ekici F., Çetin İ.İ., Çevik B.S., Kocabaş A., Şenkon O.G., Alpan N., Değerliyurt A., Güven A., Ateş C., Çakar N.*
- P-158 Controversies in Prophylaxis and Treatment of Post Surgical Pericardial Syndromes: a Critical Review with a Special Attention to the Paediatric Age.  
*Cantinotti M., Lorenzoni V, Crocetti M, Murzi B, Spadoni I.*
- P-159 Risk factors for cardiovascular disease in school age children and teenagers  
*Doros G., Popoiu A., Gafencu M., Jurca-Simina I.E., Leahu L., But A.*
- P-160 Neurodevelopmental outcome at 2 years corrected age following highly conservative treatment of the patent ductus arteriosus in extremely low gestational age neonates (ELGANs).  
*Psiouri L., Orme J., Menon G., Kissack C., Johnston E., Piyasena C., Stenson B.*
- P-161 Treatment strategies for Pulmonary Sequestration in Childhood: resection, embolization, observation?  
*Louw J.J., Brown S.C., De Laat M., Proesmans M., De Boeck C., Van Raemdonck D., Heying R., Cools B., Eyskens B., Gewillig M*
- P-162 Combination of Bosentan and Sildenafil therapy in patients with congenital heart defects (CHD): A case series  
*Rehak T., Nagel B., Fritsch P., Heinzl B., Köstenberger M., Gamillscheg A.*
- P-163 Clinical experience with recombinant tissue plasminogen activator in the management of thrombosis in children  
*Olgun H., Buyukavci M., Ceviz N., Yildirim Z.K., Sahin I.O.*
- P-164 Careers and employment in children with congenital heart disease  
*Antoniadis S., Zerva M., Antoniadou A.V., Koutis Ch., Baroutis G., Makrogika E., Dionyssopoulou E.*
- P-165 SYNCOPE IN CHILDREN AND ADOLESCENTS: A FOUR-YEAR EXPERIENCE AT THE DEPARTMENT OF PAEDIATRICS IN PARMA-ITALY  
*Bo I., Carano N., Tchana B., Giacometti A., Agnetti A.*
- P-166 Incidence of congenital coronary artery anomalies in young patients with a structurally normal heart.  
*Moench K.A.H., Schneider, H.E.E., Krause U.J., Kriebel T., Paul T.*
- P-167 The Role of N-Terminal Pro-Brain Natriuretic Peptide Levels to Predict Clinically Significant Ductus Arteriosus in Preterm Infants  
*Hallioğlu O., Gurer G., Citirik D., Tamer L., Celik Y.*
- P-168 Clinical characteristics of pulmonary arterial hypertension associated with congenital heart disease: baseline results from the Turkish Congenital Heart Disease-associated Pulmonary Arterial Hypertension (THALES) Registry  
*Sagin Saylam G., Kucukoglu S., Alehan D., Kula S., Kaymaz C., Akcevin A., Cicek S., Kaya MG., Karademir S., Varan B., Narin N., Baysal K., Tokgozoglu L., Celiker A.*
- P-169 Left Atrial and Pulmonary Capillary Wedge Pressure Relationship is Valuable for Patients with Pulmonary Hypertension  
*Kula S., Alehan D., Kaymaz C., Kucukoglu S., Saylam G.S., Akcevin A., Çeliker A., Tokgozoglu L., Çiçek S.*

- P-170 Matrix Metalloproteinase-8 Activity is Increased in Type 1 Diabetes Children with High-Risk Diabetes HLA and Systemic Inflammation  
*Liuba P., Odermarsky M., Pussinen P., Sorsa T., Maxedius A.*
- P-171 Males with 45,X/46,XY have similar cardiovascular problems as females with Turner syndrome  
*De Groot K., De Schepper J., Devos D., Vandekerckhove K., Panzer J., De Wilde H., Sluysmans T., Gewillig M., De Wolf D.*
- P-172 Physical activity in children following cardiovascular interventions  
*Dangel K., Sienkiewicz-Dianzenza E., Dangel J.H.*
- P-173 Echocardiographic evaluation of left ventricular function in normotensive obese children: A comparative analysis according to body mass index  
*Kibar A.E., Pac F.A., Ece I., Balli S.*
- P-174 Thrombotic profile in Fontan patients assessed by whole-blood assays and endothelial biomarkers  
*Idorn L., Jensen A.S., Juul K., Reimers J.I., Ostrowski S.R., Johansson P.J., Søndergaard L.*
- P-175 The Frequency of Aspirin Hepatotoxicity in Children with Acute Rheumatic Fever  
*Olgun H., Ceviz N., Karacan M., Yolcu C., Sahin I.O.*
- P-176 Cardiovascular complications of obesity at children in North-Eastern Region of Romania  
*Luca A.C., Subotnicu M., Iordache C.*
- P-177 Cardiovascular outcome in children born very preterm after intrauterine growth restriction with severely abnormal umbilical artery blood flow  
*Liuba P., Morsing E., Fellman V., Brodzki J., Marsal K.*
- P-178 Anticoagulation therapy for preventing thromboembolism in children after extracardiac conduit Fontan procedure: does it make a difference?  
*Szepesváry E., Tordas D., Bodor G., Ablonczy L., Szatmári A.*
- P-179 Stiffness of the abdominal aorta in children with  $\beta$  thalassemia major and thalassemia trait related with ferritin levels  
*Gürses D., Işık-Balci Y.*
- P-180 The risk factors of recurrency of vasovagal syncope in children and adolescents and the value of head-up tilt table test  
*Yilmaz S.T., Babaoglu K., Binnetoglu K., Altun G.*
- P-181 Factors affecting the short term prognosis of patients with Acute Rheumatic Carditis  
*Oner T., Mese T., Tavli V., Doksoz O., Demirpence S., Ozdemir R., Yozgat Y.*
- P-182 Assessment of cardiac function in children with Friedreich's Ataxia: A single centre experience  
*Gali V., Ip D., Chikermane A.*
- P-183 Acquired von Willebrand disease due to severe pulmonary valve stenosis: A relevant cause of bleeding in children with Noonan syndrome ?  
*Wiegand G., Hofbeck M., Zenker M., Budde U., Rauch R.*
- P-184 How to describe complex congenital heart defects? A hierarchical approach for diagnosis, using the Anatomic and Clinical Classification of Congenital Heart Defects.  
*Houyel L., Khoshnood B., Anderson R.H., Lelong N., Thieulin A.C., Goffinet F., Bonnet D. [EPICARD Study group]*
- P-185 A new anatomic approach to the ventricular septal defect in interruption of the aortic arch.  
*Mostefa Kara M., Houyel L.*
- P-186 Conotruncal (outflow tract) defects: is the ventricular septal defect always the same?  
*Mostefa Kara M., Houyel L.*
- P-187 Efficacy and safety of home INR testing during Warfarin treatment for children and adults with congenital heart disease  
*Ananth Narayan S., Reinhardt Z., Durairaj S., Cox J., Bolger A.P.*
- P-188 Chest pain in children and adolescents : a frequent complaint  
*Boulos Ksontini T., Di Bernardo S., Mivelaz Y., Sekarski N.*
- P-189 Aminoterminal pro B-type natriuretic peptide concentrations in newborns: congenital heart disease or respiratory failure due to neonatal lung disease?  
*Lechner E., Wagner O., Weissensteiner M., Schreier-Lechner E., Furthner D., Prandstetter C., Wiesinger-Eidenberger G.*
- P-190 Dear Surgeon, Have I got it right? Does it matter at all?  
*Saravanan D., Kollipara R., Reinhardt Z., Kapoor S., Lotto A., Bu'Lock F., Shebani S.O.*
- P-191 Prevalence of hypertension in children after early repair of coarctation of the aorta  
*Malafaya Baptista M., Costa P., Moura C., Mota C., Sousa A.R., Areias J.C.*

#### **GUCH and outcomes**

- P-192 Continued Surgical Review: a Multidisciplinary Clinical Model for Quality Control and Mentoring  
*Viola N., Pousios D., Lipnevicius A., Haw M.P., Kaarne M., Salmon A.P., Catchpole K.*

- P-193 Mild hepatic disorder occurs early after Fontan procedure and worsens at time progresses  
*Hamamichi Y., Ishii Y., Ishii R., Terashima Y., Narita J., Kawazu Y., Inamura N., Kayatani F., Kawata H., Kishimoto H.*
- P-194 Neuropsychiatric development and health in children with and without congenital heart block born to mothers with Ro/SSA autoantibodies – a retrospective follow-up  
*Skog A., Tingström J., Salomonsson S., Swedish CHB Study Group, Sonesson S.-E., Wahren-Herlenius M.*
- P-195 B-type natriuretic peptide according to magnetic resonance imaging findings in surgically repaired tetralogy of Fallot  
*Koch A., Gundlach U., Glöckler M., Breuer C., Toka O., Dittrich S.*
- P-196 Central Hemodynamics in Pediatric Patients after Successful Aortic Arch Repair  
*Murakami T., Horibata Y., Morimoto Y., Tateno S., Kawasoe Y., Takeda A., Yamazawa H., Niwa K.,*
- P-197 Sense of Coherence, Rather Than Exercise Capacity, is the Stronger Mediator to Obtain Health Related Quality of Life in Adults with Congenital Heart Disease  
*Müller J., Hess J., Hager A.*
- P-198 Long-term Survival, Exercise Performance and Quality of Life in patients after Fontan Surgery – Results From a Single Centre  
*Müller J., Weber R., Pringsheim M., Hörer J., Hess J., Hager A.*
- P-199 Partial anomalous pulmonary venous connection to superior vena cava surgery in Adults: Our experience  
*Polo L., Rey J., González A., Bret M., Cerro M.J., Sanchez-Recalde A, Pérez N., de Vicente J., Oliver J., Villagrà F.*
- P-200 Percutaneous versus surgical closure of atrial septal defect; still a battle?  
*Kourkovelis P., Kapetanopoulos D., Kantzis M., Kiaffas M., Apostolopoulou S.C., Rammos S.*
- P-201 Vitamin D kinetics and parathyroid function in patients with congenital heart disease.  
*Izumi G., Inai K., Shimada E., Shimizu M., Ishii T., Toyohara K., Sugiyama H., Shinohara T., Nakanishi T.*
- P-202 Microvolt T-wave alternans in adults with the chosen forms of congenital heart diseases.  
*Cieplucha A., Trojnarowska O., Plaskota K., Bartczak A., Kramer L., Grajek S.*
- P-203 Microvolt t-wave alternans in adult patients with repaired tetralogy of Fallot.  
*Bartczak A., Trojnarowska O., Plaskota K., Cieplucha A., Kramer L., Grajek S.*
- P-204 Late complications after Senning or Mustard type of repair in transposition of the great arteries  
*Ladányi A., Bálint O.H., Köhalmi D., Szatmári A., Temesvári A.*
- P-205 Late complications after tetralogy of Fallot repair  
*Ladányi A., Bálint O.H., Fischer D., Köhalmi D., Szatmári A., Temesvári A.*
- P-206 24 year-old pregnant woman with ventricular septal defect and pulmonary hypertension  
*Rehak T., Nagel B., Heinzl B., Fritsch P., Köstenberger M., Gamillscheg A.*
- P-207 Long-term outcome of pulmonary atresia with ventricular septal defect  
*Yli-Peltola A., Happonen J.M., Mattila I., Pitkänen O.M.*
- P-208 Preliminary neuropsychological assessment of adolescents after congenital heart defect repair.  
*Stolarska U., Werynski P., Rudzinski A., Kacinski M.*
- P-209 Increased Transition to Adult Care After Interrupted Aortic Arch Repair in a Multi-institutional Cohort  
*Jegatheeswaran A., Walters H.L., Blackstone E.H., Caldarone C.A., DeCampi W.M., Duncan K., Jacobs M.L., Kirshbom P.M., Lambert L., Mussatto K., Ricci M., Tweddell J.S., Williams W.G., Brown J.W., Jacobs J.P., Pizarro C., St.Louis J., Tchervenkov C.I., Yeh T., McCrindle B.W.*
- P-210 Factors associated with self-reported functional health status in a multi-institutional cohort of young adults with Interrupted Aortic Arch  
*Jegatheeswaran A., Kirshbom P.M., Blackstone E.H., DeCampi W.M., Jacobs M.L., Mussatto K., Tchervenkov C.I., Walters H.L., Brown J.W., Duncan K., Lambert L., Pizarro C., Ricci M., St.Louis J., Yeh T., Jacobs J.P., Tweddell J.S., Williams W.G., Caldarone C.A., McCrindle B.W.*
- P-211 Could subclavian flap repair be superior to end-to-end anastomosis for coarctation of the aorta?  
*Reinhardt Z., Durairaj S., Kollipara R., Taliotis D., Shebani S.O., Peek G.J., Reek C., Bolger A.P.*
- P-212 Long term follow-up of repaired tetralogy of Fallot: impact of shunt palliation.  
*Festa P., Trocchio G., Alt-Ali L., Stagnaro N., Siciliano V., Passino C., Marasini M.*
- P-213 Management of pulmonary hypertension in Down syndrome  
*Tulloh R., Whitton L., McKenzie L., Pieles G., Visser W., Gin-Sing W., Howard L.*
- Imaging/functional assessment**
- P-214 Reduced aortic elasticity and ventricular dysfunction late after pediatric meningococcal septic shock: a precursor of atherosclerosis?  
*Grotenhuis H.B., Knoester H., Westenberg J.J.M., Kroft L.J.M., de Roos A.*

- P-215 Cardiopulmonary Exercise Test Responses in Children with Obstructive Sleep Apnea Syndrome  
*Damianidou L., Eboriadou M., Giannopoulos A., Kirbasilis F., Kontouli K., Tsanakas I., Athanasiadou F.*
- P-216 Obstructive Sleep Apnea Syndrome and Cardiovascular System in Children  
*Damianidou L., Eboriadou M., Giannopoulos A., Tzimou I., Tsanakas I., Athanasiadou F.*
- P-217 Pulmonary functions before and after cardiac surgery in infancy  
*Agha H., Heinady F., Falaky M., Sobeih A.*
- P-218 Tissue Doppler, strain and strain rate echocardiography in healthy newborns and infants  
*Elkiran O., Karakurt C., Kocak G., Karadag A.*
- P-219 Decreased systolic function measured by Speckle tracking echocardiography in children with ESRD  
*Schoenmaker N.J., Groothoff J.W., van der Lee J.H., Blom N.A., Kuipers I.M.*
- P-220 Assessment of right ventricular function with tissue Doppler imaging in children with asthma  
*Ozdemir O., Ceylan Y., Razi C.H., Ceylan O., Andiran N.*
- P-221 Pharmacological Assessment of Anti-Platelet Drugs by Whole-Blood Aggregation and Serum Thromboxane B2 in Kawasaki Disease Patients  
*Suzuki C., Yahata T., Hamaoka A., Fujii M., Yoshioka A., Nakamura A., Niwa Y., Ikeda K., Hamaoka K.*
- P-222 Can Simple Echocardiographic Measures Reduce the Number of Cardiac Magnetic Resonance Imaging Studies to Diagnose Right Ventricular Enlargement in Congenital Heart Disease?  
*Alghamdi M.H., Grosse-Wortmann L., Ahmad N., Mertens L., Friedberg M.K.*
- P-223 Strain and Strain Rate Echocardiography Findings in Children With Congenital Left Ventricular Outflow Tract Obstruction  
*Dogan V., Öcal B., Örün U.A., Özgür S., Yılmaz O., Keskin M., Ceylan Ö., Karademir S.*
- P-224 Dynamic Changes in the Vaso-Vasorum as an Inducing Factor for Vasculitis in Kawasaki Disease  
*Hamaoka A., Fujii M., Suzuki C., Yahata T., Yoshioka A., Niwa Y., Nakamura A., Ikeda K., Hamaoka K.*
- P-225 Assessing of vascular Rings, slings and their potentially life-threatening complications using MRI, CT, and Tracheobronchoscopy from newborns to seniors  
*Eichhorn J.G., Springer W., Schenk J.P., Sebening C., Gorenflo M., Loukanov T.*
- P-226 Cardiac Magnetic Resonance in Children with Acute Myocarditis  
*Bonnet D., Raimondi F., Boudjemline Y., Bajolle F., Iserin F., Ou P.*
- P-227 A Stress Echocardiography study of Exercise Capacity and Cardiac Function following Arterial Switch Operation for simple Transposition of the Great Arteries  
*De Souza A.M., Potts J.E., Gill R, Hollinger A.J., Williams L.D., Sandor G.G.S.*
- P-228 Evaluation of Ventricular Function in HIV-infected pediatric and adolescent patients: the use Speckle Tracking.  
*Alvarez Fuente M., Sainz Costa T., Medrano-López C., Navarro M.L., Ramos J.T., Gonzalez-Tomé M.I., de Jose M.I., Mellado M.J., Muñoz M.A., Maroto-Alvaro, E.*
- P-229 Surgical simulation of congenital heart disease by using flexible biomodels made by stereolithography and vacuum casting  
*Shiraishi I., Kurosaki K., Kanzaki S., Takeda M., Ichikawa H.*
- P-230 Evaluation of optimal voltage for reduce radiation exposure of area detector computed tomography in children after Kawasaki disease  
*Kamiyama H., Sumitomo N., Karasawa K., Watanabe H., Abe Y, Nakamura T., Fukuhara J., Ichikawa R, Matsumura M., Abe O., Ayusawa M., Okada T., Mugishima H.*
- P-231 Extendable Multimodal Cardiac Analysis Framework  
*Hüllebrand M., Hennemuth A., Messroghli D., Berger F., Kuehne T.*
- P-232 Cardiac functions, intima-media thickness and epicardial adipose tissue in obese children with nonalcoholic fatty liver disease: Echocardiographic and tissue Doppler imaging study  
*Alp H., Karaarslan S., Eklioğlu Selver B., Atabek M.E., Altın H., Karataş Z, Baysal T.*
- P-233 Obstructive left heart disease in neonates with a “borderline” left ventricle: diagnostic challenges for choosing the best outcome  
*Tuo G., Khambadkone S., Tann O., Kostolny M., Derrick G., Tsang V., Sullivan I., Marek J.*
- P-234 Certain ECHO and advanced ECG indexes are associated with family history for major adverse events in children and adolescents with HCM, and can be distinguished from athlete’s heart  
*Fernlund E., Schlegel T.T., Platonov P., Carlsson J., Liuba P.*
- P-235 Effects of Remote Preconditioning on Skeletal Muscle Metabolism During Exercise, a Pilot Study  
*Jean-St-Michel E., Manlhiot C., McCrindle B.W., Redington A., Wells G.*

- P-236 An analysis of left ventricular strain in premature infants and full-term infants during the early postnatal period using Velocity Vector Imaging -An investigation into the development of cardiac function in newborns-  
*Tanaka N., Ohtsuki M., Furukawa T., Ebihara S., Toduka M., Kantake M., Obinata K., Takahashi K., Kishiro M., Shimizu T.*
- P-237 Impact of aortic elastance on right ventricular function in Hypoplastic Left Heart Syndrome after Fontan palliation.  
*Schlangen J., Fischer G., Petko C., Voges I., Hansen J.H., Steendijk P., Kramer H.-H., Uebing A.*
- P-238 Patients after Arterial Switch Operation Have Impaired Global and Regional Systolic Right Ventricular Function: A Speckle Tracking Echocardiography Study  
*Marinov R., Hristova K., Georgiev S., Velkovski I., Kaneva A., Pavlova M., Mitev P., Lazarov S., Tzonzarova M., Katova T., Pulosoff V.*
- P-239 Atria volume ratio as a simple echocardiographic parameter that might be useful in corrected Tetralogy of Fallot evaluating the timing for re-intervention in this population.  
*Cristofaletti A., Prioli M.A., Cassater D., Rossetti L., Franceschini F., Rebonato M., Pechlivanidis K., Lucchese G., Luciani G.B.*
- P-240 Norwood I type procedure for Hypoplastic Left Heart Syndrome at time of Fontan completion: does it make any difference?  
*Marrone C., Federici D., Marcora S., Ciuffreda M., Preda L., Di Dedda G., Galletti L., Borghi A.*
- P-241 Accuracy of gadolinium-enhancement 3-dimensional magnetic resonance angiography to detect venovenous collaterals in patients with total cavopulmonary connection (TCPC).  
*Marini D., Roberto E., Bordese R., Corleto A., Riggi C., Gabbarini F., Defillippi C., Agnoletti G.*
- P-242 Echocardiographic assessment of diastolic dysfunction in children with congenital heart disease – correlations with invasive data  
*Dragulescu A., Mroczek D., Chaturvedi, R., Benson L., Redington A., Friedberg M.K., Jaeggi E., Mertens L.*
- P-243 Evaluation of Cardiovascular Changes in Children with Aortic Coarctation Treated with Endovascular Stents  
*Narin N., Sezer S.S., Baykan A., Pamukcu O., Ozyurt A., Argun M., Uzum K.*
- P-244 Cardiac MRI stress testing in children with myocardial ischaemia.  
*Bucciarelli-Ducci C., Pennell D.J., Seale A., Wage R., Kilner P., Franklin R., Slavik Z., Daubney P.E.F.*
- P-245 The role of preoperative catheterization in TCPC candidates  
*Dolk M., Johansson J., Johansson S., Liuba P., Hanséus K.*
- P-246 Reproducibility of a steady-state submaximal CMR-guided exercise test  
*Steinlechner E., Calavrezos L., Hager A., Mueller J., Schuster T., Martinoff St., Hess J., Stern H., Fratz S.*
- P-247 Cardiac functional assessment in mucopolysaccharidosis  
*Granja S., Costa P., Martins E., Leão-Teles E., Baptista M.J.*
- P-248 Diagnosis and quantification of patent foramen ovale shunt: the role of transcranial Doppler sonography  
*Laranjo S., Paramés F., Mateus T., Ferreira-Martins J.D., Pinto F.F.*
- P-249 Long-term outcome of small residual shunts in pts with multiperforated interatrial aneurysms following device implantation.  
*Laskari C.V., Kiaffas M., Apostolopoulou S.C., Rammos S.*
- P-250 Right ventricular volume in Tetralogy of Fallot: a 2D echocardiographic method validation in comparison with cardiac magnetic resonance.  
*Rodriguez-Lopez A., García-Cuenillas L., Medrano-Lopez, C., Granja S., Marín C., Maroto E., Álvarez T., Ballesteros F., Camino M., Centeno-Jimenez, M., Zunzunegui J.L., Panadero E.*
- P-251 Stents in Aortic Coarctation: Beyond Gradients and Pressures  
*Cordeiro S., Santos M., Francisco A., Maymone Martins F., Anjos R.*
- P-252 Assessment of Ventricular Septal Defects by Live Three-dimensional Echocardiography  
*Karadas U., Kir M., Karadas N., Yilmaz N., Sagin Saylam G.*
- P-253 Right ventricle systolic and diastolic function in juvenile-onset systemic lupus erythematosus patients  
*Moura C., Costa P, Rodrigues M., Sampaio L., Brito I., Areias J.C.*
- Interventional cardiology**
- P-254 Critical Neonatal Aortic Valve Stenosis, Immediate and Intermediate Outcome of Percutaneous Balloon Valvuloplasty  
*Hyder S.N., Kazmi U., Khan A., Kazmi T., Usaid A.Q., Sheikh A.M., Sadiq M.*

- P-255 Influence of balloon size on aortic regurgitation in neonates undergoing Balloon Aortic Valvuloplasty-a retrospective study over an 11-year period  
*Krasemann T., Herman R., Hamidi L.*
- P-256 Balloon Atrial Septostomy performed 'out-of-hours': Effects on the outcome  
*Krasemann T., Vimalasvaran S., Ayis S.*
- P-257 Interventional closure of muscular VSDs at a young age  
*Zartner P., Savidou D., Toussaint-Goetz N., Wiebe W., Schneider M.*
- P-258 Coronary Interventions in infants with congenital heart diseases  
*Schneider M., Wiebe W., Toussaint-Goetz N., Zartner P.*
- P-259 Has biventricular repair become an option in patients with pulmonary atresia, intact ventricular septum and coronary to right ventricular fistulae?  
*Schneider M., Hraska V., Zartner P.*
- P-260 Immediate and Intermediate Results of Patent Ductus Arteriosus Transcatheter Closure in Kurdistan (Multicenter experience)  
*Salih A., Al-Rabaty A.*
- P-261 Paediatric Ventricular Assist Devices: A Successful Nurse Training Programme and a Review of the Literature  
*Anand A., Abbas J., Sinnadurai S., Araujom S., Buchholz H.*
- P-262 Transcatheter closure a huge left atrial aneurysm with the right pulmonary artery to left atrium connection using with Amplatzer Ventricular Septal Occluder  
*Baspinar O., Irdem A., Toprak Y.*
- P-263 An immediate imperfect result of balloon dilatation for aortic coarctation in infants and young children engenders an adequate late result.  
*Corleto A., Agnoletti G., Bordese R., Marini D., Gabbarini F., Parrinello G.*
- P-264 Closure of the patent ductus arteriosus with the new Duct Occluder II additional sizes device  
*Marini D., Agnoletti G., Corleto A., Bordese R., Gabbarini F.*
- P-265 Experience with percutaneous perforation of the pulmonary valve in neonates with pulmonary atresia and intact interventricular septum  
*Bakloul M., Sassolas F., Ducreux C., Veyrier M., Henaine R., Metton O., Ninet J., Di Filippo S.*
- P-266 GORE® SEPTAL OCCLUDER: early clinical results.  
*Butera G., Danna P., Musto C., Sacra C., Violini R., Viecca M., Farahani K.V., Chessa M., Piazza L., Carminati M.*
- P-267 Stent implantation in patients with native and recurrent coarctation of the aorta. Is application of bare metal better than covered stents?  
*Bialkowski J., Szkutnik M., Fiszer R.*
- P-268 For small babies a new Amplatzer Duct Occluder II Additional size: Initial experience of our clinics  
*Baspinar O., Irdem A., Kilinc M.*
- P-269 Non-routine using of the Amplatzer Occluders and the Amplatzer Plugs in children  
*Baspinar O., Irdem A., Kilinc M.*
- P-270 Transcatheter closure of ruptured sinus of Valsalva aneurysm with nitinol mesh occluders.  
*Szkutnik M., Fiszer R., Bialkowski J.*
- P-271 Short- and Mid-term Results of Balloon Angioplasty for Coarctation of the Aorta in Neonates  
*Örün U.A., Ceylan Ö., Bilici M., Öcal B., Karademir S., Şenocak F., Zenciroğlu A., Özgür S.*
- P-272 Transcatheter Closure of Atrial Septal Defect by Amplatzer Occluder Devices [ASO] In Benghazi Cardiac Center  
*Rahouma S., Khazmi A., Fitouri R.*
- P-273 Percutaneous dilation of inferior caval vein and closure of left superior caval vein in the patient after Fontan operation  
*Kusa J., Szydłowski L., Skierska A., Nowakowska E.*
- P-274 Cerebral Microemboli Detection during Transcatheter ASD Closure  
*Wallace S., Dohlen G., Holmström H., Lund C., Russell D.*
- P-275 Effect of unfractionated heparin during pediatric cardiac catheterization  
*Pihkala J., Chen D., Långström S., Petäjä J., Heikinheimo M.*
- P-276 Creation of Fontan Fenestration and Atrial Septal Defect with NRG RF Powered Transseptal Needle  
*Akin A., Karagöz T., Ertuğrul İ., Özkutlu S., Alehan D., Özer S.*
- P-277 Initial results of PDA stenting in newborn with duct dependent pulmonary circulation  
*Odemis E., Guzeltaş A., Ozyılmaz İ., Bilici M., Bakir İ.*
- P-278 Percutaneous Extraction of Cardiac Leads With Evolution Mechanical Dilator Sheath in Young Patients  
*Aykan H.H., Karagöz T., Akin A., Ertuğrul İ., Özer S.*

- P-279 Percutaneous closure of patent ductus arteriosus under 6 Kg: Is it Safe?  
*Santoro G., Gaio G., Palladino M.T., Iacono C., Sorrentino R., Pignatiello M., Russo M.G.*
- P-280 Arterial duct redilatation/restenting: a single center experience  
*Santoro G., Gaio G., Palladino M.T., Sorrentino R., Pignatiello M., Caianiello G., Russo M.G.*
- P-281 Percutaneous Pulmonary Valve Implantation: Initial Results of Turkish Experience  
*Odemis E., Guzeltas A., Bilici M., Bakir I.*
- P-282 Early and Mid-Term Outcomes of Transcatheter Management in Pulmonary Atresia with Intact Ventricular Septum  
*Odemis E., Guzeltas A., Ozyilmaz I., Bilici M., Tanidir C., Bakir I.*
- P-283 Six years results of endovascular stenting of coarctation of the aorta in children – single center experience  
*Brzezińska-Rajszyś G., Zubrzycka M., Rewers B., Książyk J., Turska-Kmieć A., Kościeszka A., Kąsy A.*
- P-284 Immediate and short-term outcome of the Gore Septal Occluder® (GSO) in patent foramen ovale and atrial septal defect closure – Early clinical experience  
*Loh PH., Cholteesupachai J., Jensen T., Franzen O., Søndergaard L.*
- P-285 Percutaneous device closure of large patent ductus arteriosus in the very young  
*Premsekar R., Saileela R.*
- P-286 Sternotomy As a Safe Alternative ‘Access’ for Transluminal Interventions In Low Birth Weight infants  
*Cools B., Boshoff D., Heying R., Rega F., Eyskens B., Meyns B., Gewillig M.*
- P-287 Aorta-Right Atrial Tunnel Closure with Transcatheter Technique: A Case of 3 Years Old Child  
*Baykan A., Narin N., Ozyurt A., Sezer S.S., Argun M., Uzum K.*
- P-288 Interventional VSD closure using the Amplatzer Duct Occluder II™ in a small infant with concomitant Aortic Coarctation  
*Gitter R., Prandstetter C., Mair R., Tulzer G.,*
- P-289 Transcatheter atrial septal defects closure without balloon sizing.  
*Vignati G., Annoni G., Cataldo S., Mauri L., Corato A.*
- P-290 Palliative pulmonary balloon valvuloplasty for symptomatic infants with tetralogy of Fallot and unfavourable for total surgical correction  
*Demir H., Celebi A., Saritas T., Erdem A., Yucel I.K., Demir F., Dedeoglu R.*
- P-291 Percutaneous treatment of complex aortic coarctation and aortic arch hypoplasias with Cheatham Platinum stents  
*Celebi A., Erdem A., Saritas T., Dedeoğlu R., Yucel I.K., Demir H., Demir F.*
- P-292 Stenting of the Right Ventricular Outflow Tract in Patients with Tetralogy of Fallot  
*Emmel M., Sreeram N., Bennink G., Khalil M., Adelmann R., Udink ten Cate F., Brockmeier K.*
- P-293 3-Dimensional rotational angiography to assess the pulmonary circulation in patients with single ventricle after Bidirectional Glenn operation  
*Goreczny S., Dryzek P., Moszura T., Mazurek-Kula A., Moll J.J., Sysa A., Moll J.A.*
- P-294 Doppler and Radionuclide Pulmonary Blood Flow Patterns After Transcatheter Closure of Patent Ductus Arteriosus  
*Ece İ., Pac F.A., Ballı S., Keçeci D.*
- P-295 Percutaneous revalvulation of the RVOT in Belgium  
*Cools B., Boshoff D., Budts W., Sluysmans T., Dessy H., Dewolf D., Heying R., Kefer J., Milani S., Gewillig M.*
- P-296 A new method for percutaneous treatment of coronary artery fistulae in young children  
*Petit J., Baruteau A.E., Riou J.Y., Brenot P.*
- P-297 Balloon dilation of pulmonary vein stenosis using PAXLITAXEL eluting balloons: midterm result in an infant  
*Koch A., Glöckler M., Breuer C., Toka O., Dittrich S.*
- P-298 Interventional closure of perimembranous ventricular septal defects: Experience using the Amplatzer Duct Occluder II.  
*Heying R., Cools B., Boshoff D., Eyskens B., Louw J.J., Gewillig M.*
- P-299 Awareness about transcatheter removal of intravascular foreign bodies among pediatric health care providers  
*Jadoon S., AlMasham Y., El Segaier M., Galal M.O.*
- P-300 Transcatheter retrieval of cardiovascular foreign bodies-A 15-year single centre experience.  
*Kudumula V., Noonan P., Bhole V., Stickley J., de Giovanni J.V., Dhillon R., Miller P., Mehta C., Stumper O.*
- P-301 Transcatheter Management of Failed Melody Valves After Successful Placement  
*Coe J.Y., Taylor D.*
- P-302 Stenting of Systemic to Pulmonary Artery Gore-Tex Shunts  
*Noonan P., Ramchandani B., Dhillon R., Mehta C., de Giovanni J.V., Stumper O.*



- P-303 Significant aortic obstruction with the Amplatzer Duct Occluder II  
*Saliba Z., Chehab Gh., Helou D., El-Rassi I., AbdelMassih T.*
- P-304 Eliminating Stent Slippage Using a Combined Sheath-Balloon Catheter  
*Coe J.Y., Taylor D.*
- P-305 Implantation of the new Nit-Occlud PDA-R device in children below 10 kilograms  
*Moysich A., Laser K.T., Sandica E., Kececioglu D., Haas N.A.*
- P-306 Treatment of extremely tortuous and hypoplastic aortic arches by implantation of JOTEC™ E-XL Aortic Stents  
*Moysich A., Laser K.T., Kececioglu D., Sandica E., Haas N.A.*
- P-307 Percutaneous pulmonary valve implantation in small children: a single center experience  
*Ballesteros F., Zunzunegui J.L., Gil N., Alvarez T., Rodriguez Ogando A., Camino M., Maroto-Alvaro, E.*
- P-308 Interventional therapy of stenotic pulmonary arteries in adult patients with mechanical pulmonary valve prosthesis  
*Haas N.A., Habbash S., Moysich A., Laser K.T., Sandica E., Kececioglu D.*
- P-309 Deliberate dilatation of the meshwork of CP-Stents-creation of adequate flow to overstented vessels  
*Haas N.A., Moysich A., Molatta S, Laser K.T., Kececioglu D*
- P-310 Stenting of the right ventricular outflow tract below the pulmonary valve as a palliative measure in symptomatic neonates with TOF  
*Haas N.A., Moysich A., Laser K.T., Blanz U.,Kececioglu D.,Sandica E.*
- P-311 How many stents are enough to stabilize the RVOT before percutaneous pulmonary valve implantation  
*Haas N.A., Moysich A., Görg R., Laser K.T., Kececioglu D.*
- P-312 Transcatheter closure of patent Ductus Arteriosus in children weighing 8 Kg or less: a single center experience  
*Ballesteros F., Nuñez M.T., Zunzunegui J.L., Panadero E., Rodriguez R., Medrano-Lopez, C., Centeno-Jimenez, M.*
- P-314 Seven Years Libyan Experience in Structure Heart Disease Interventions  
*Khazmi A., Rahouma S., AL Fitouri R., Halabi A., Tawfig M., Wilson N., de Giovanni J.V., Hijazi Z.*
- P-315 Endovascular stent implantation for coarctation/recoarctation of the aorta  
*Környei L., Ablonczy L., Konta L., Szatmari A.*
- P-316 Single centre experience of Balloon Angioplasty of Branch Pulmonary Artery Stenosis after Arterial Switch Operation  
*Saifullah T., Reinhardt Z., Taliotis D.*
- P-317 Transcatheter Closure of Multiple Ventricular Septal Defects  
*Assaidi A., Kammache I., Paoli F., Fraisse A.*
- P-318 The only venous access of transcatheter duct closure in children below 10 kilos.  
*Kusa J., Ras M., Czesniewicz P., Nahirny R.*
- P-319 Blalock-Taussig shunt angioplasty.  
*Borges Santos M., Teixeira A., Nogueira G., Menezes I., Matos Silva M., Carvalho N., Sousa P.J., Maymone Martins F.,Anjos R.*

#### **Surgery and Intensive care**

- P-320 Perioperative assessment of patients with repaired tetralogy of Fallot undergoing pulmonary valve replacement  
*Selly J.B., Iriart X., Mauriat P., Roubertie F., Thambo J.B*
- P-321 Infants with coarctation of the Aorta±Hypoplastic aortic Arch: Median or lateral approach?  
*Polo L., Deiros L., Labrandero C., González A., Rey J., Bret M., Cerro M.J., Sanabria P., Borches D., Villagrà F.*
- P-323 Pulmonary artery branches stenosis in patients with congenital heart disease: the result of combined surgical and interventional approaches  
*Vida V.L., Zucchetta F., Lo Rito M., Padalino M.A., Cerutti A., Reffo E., Maschietto M., Biffanti R., Stellin G., Milanese O.*
- P-324 Long-term outcome after repair of complete atrio-ventricular septal defect : A 30-year experience in a single institution  
*Carbonez K., Martin M., Moniotte S., Sluysmans T., Barrea C., Rubay J., Poncelet A.*
- P-325 An Expanded use of injectable pulmonic valve for Primary Repair  
*Ozkan S., Salihoglu E.,Ozcobanoglu S., Celiker A.*
- P-326 Outcome and related parameters associated at maintenance of CI > 3 l/m<sup>2</sup> following surgery for congenital heart disease  
*Gil-Anton J., López-Bayón J., López-Fernández Y., Pérez E., Redondo S, Morteruel E.*

- P-327 Closure of Patent Ductus Arteriosus in the first year of life; does closure rate vary with clinician or patient factors?  
*Bu'Lock F., Peek G.J., Currie A*
- P-328 Frequency of Complications and Outcomes Following Fontan Operation  
*Uzun O., Ryan-Fisher C., Wilson D.G., Babaoglu K., Ayhan Y.I, Caputo M., Parry A.*
- P-329 Renal near infrared spectroscopy as realtime indicator for developing acute kidney injury in infants undergoing cardiac surgery with cardiopulmonary bypass  
*Ruf B., Bonelli V., Balling G., Hórer J., Reiter K., Hess J.*
- P-330 Long-term effects of residual right ventricular (RV) outflow tract obstruction on RV dimension and function in patients after repair of tetralogy of Fallot  
*Latus H., Gummel K., Bauer J., Jux C., Valeske K., Akintuerk H., Schranz D., Apitz C.*
- P-331 ECMO as a Bridge to Recovery in Patients with Intractable Arrhythmias  
*Bauch A., Duke A., Faulkner G., Hickey M., Harvey C., Peek G.J.*
- P-332 Total cavopulmonary connection in patients with the Down syndrome  
*Furukawa T., Park I., Yoshikawa T., Takahashi Y.*
- P-333 Inhaled Nitric Oxide after Superior Cavopulmonary Anastomosis – Effects on Cavopulmonary Pressure and Oxygen Saturation  
*Georgiev S., Pechilkov D., Latcheva A., Pulosoff V.*
- P-334 Late arterial switch for transposition of the great arteries  
*Meijboom E., Sekarski N., Hurni M., von Segesser L., Di Bernardo S.*
- P-335 Inferior mini-sternotomy provides excellent cosmetic outcomes in children with congenital heart disease.  
*Cárdenas-Reyes I.J., Garcia-Hernandez I., Portela F., Rueda F., Marcos-Alonso S., Bautista-Hernandez V.*
- P-336 Paediatric cardio-pulmonary assist via central ECMO with an integrated left ventricular vent  
*Sandrio S., Gorenflo M., Karck M., Loukanov T.*
- P-337 Biventricular correction for complex congenital heart defects associated with aortic arch anomalies after initial Norwood-type operation. Case series report.  
*Michalak K.W., Moll J.A., Moszura T., Moll M., Dryżek P., Moll J.J.*
- P-338 Unusual case of a traumatic VSD and ventricular aneurysm in a child secondary to a blunt chest trauma.  
*Woerner C., Seed M., Hickey E., Benson L.*
- P-339 Custom made external aortic root support, an alternative for aortic root replacement in patients with Marfan  
*Rega F., Gewillig M., Budts W., Troost E., Dymarkowski S., Pepper J., Treasure T., Meyns B.*
- P-340 Correlation between echocardiographic estimation of the left atrial pressure and its invasive measurement in paediatric patients following cardiac surgery  
*Figueras M., Albert D.C., Gran F., Sanchez de Toledo J., Buse L., Paris N., Sabaté A.*

#### **Interventional cardiology**

- P-341 Expanding treatment options for the patent arterial duct (PDA)-Amplatzer Ductal Occluder-II Additional Sizes (ADO-II AS) Early clinical experience  
*Yao N.-A., Ramchandani B., Mehta C., Bhole V., Dhillon R., Stumper O., de Giovanni J.V.*