

## CONCORDANT PRIMARY ATROPHY OF THE CEREBELLAR GRANULES IN MONOZYGOTIC TWINS

by

*George A. Jervis, M. D.*<sup>1</sup>

In the heterogeneous group of primary cerebellar atrophies, a characteristic type has been recently singled out which shows distinct clinical and pathological features. The clinical picture is characterized by mental deficiency and cerebellar signs. Mental defect is apparently congenital or develops within the first year of life and is usually marked in degree. Mental deterioration is absent. Cerebellar signs, although always present, are often inconspicuous and usually stationary. The pathological picture is characterized by cortical atrophy of the cerebellum; histologically, there is extensive degeneration of the granular layer with relative preservation of the Purkinje layer; the Purkinje cells show, however, distorted shape and bizarre alterations of both axons and dendrites. Other structures such as dentate nuclei, red nuclei and pontine formations, as well as spinal pathways, are intact. The terms "primary degeneration of the granular layer" (1) or "cerebellar atrophy of the granular type" (2), appropriately sum up the essential pathological lesions. The disease is apparently familial in character and the occurrence of three cases in one family was previously reported (3). However, only very few instances of the disease can be found in the literature and no cases in twins have been described.

It is the purpose of this presentation to put on record the case of monozygotic twins both affected with primary degeneration of the granular layer of the cerebellum, and to comment briefly on some aspects of the disease.

### Case report

Mary and Adeline M. were admitted to the Letchworth Village Hospital on October 10, 1923 at the age of 18 years. The family history was of three generations of Italian ancestry both sides. There was no consanguinity. Paternal grandparents were healthy and intellectually normal. They died at 70 and 73 years respectively. They had one son and two daughters besides the father of the twins, all of whom were reported healthy, but none of whom were personally examined. The father of the twins was 70 years of age at the time of patients' admission; he was healthy and of normal intelligence; he died subsequently of a brain hemorrhage. On the maternal line, the grandmother was physically and mentally normal until the age of 70 years when she developed a psychosis,

---

<sup>1</sup> From the Research Department, Letchworth Village, New York State Department of Mental Hygiene, Thiells, N. Y.

senile in type. The mother of the twins was not examined, having died prior to the admission of the twins to the hospital. She was reported as physically normal until about 50 years of age when she developed a "kidney condition"; she died at 56 years of a cerebral hemorrhage. Mentally, she was considered somewhat dull but was able to attend



Fig. 1 - Twins Mary and Madeline M. at the age of 38 years

efficiently to her work as housewife. The twins had two older sibs, a brother apparently normal physically and mentally who died of an accidental death at age 30, and a sister who was normal and had three normal children.

The twins were born of a spontaneous delivery following a normal gestation. No information was available concerning the placenta. They were very much alike as infants and could not be told apart. Developmental history was strikingly similar. At one year they were obviously defective, failed to respond to normal stimuli and were unable to hold their heads up. Teething began in both at 14 months, they sat up at 4 years and stood up at 5 years but with considerable swinging of the whole body. A few words were spoken by both at the age of 6 years but there was never any sentence formation. It was only at the age of 8 years that they attempted to walk. For several years, they could take only a few steps at a time without falling. Controls of sphincters never developed. They were observed in childhood to have the same mannerisms, a fact which was commented upon by members of the family. They had the same children's diseases at the same time: measles at 3 months and whooping cough at 4 years. In their mental make-up they were quite similar, passive and disinterested with occasional periods of violence and destructiveness.

---

On admission at the age of 18 years, physical examination showed strikingly identical features (fig. 1). Mary's height was 4 feet 8 inches, Adeline's 4 feet 7½ inches; weight 100 and 98 pounds respectively. They had the same torso-leg ratio and the same circumference of the head (21 inches). Color of hair and iris was identical. Hair distribution was of the same type. Configuration of external ear showed no difference between the two members. Fat was abundant with abdominal distribution in both. Hands were short and stubby. Feet were quite short and large with considerable flatness of the arch and eversion of the astragalus. Teeth were in both twins irregular in distribution with considerable decay, more marked in Adeline. Molds of the palate showed identical configuration. Extremities were slightly cyanosed. Cardiovascular system was negative. Blood pressure was slightly lower in Adeline (100/60) than in Mary (110/70). Examination of palmar and plantar prints was compatible with the diagnosis of monozygosity.

Neurological examination showed no significant difference between the two twins. There was in both considerable impairment of equilibratory coordination, the twins would walk clumsily with marked swaying of the body and with feet apart. Gait was made worse by the marked deformity of the feet. Dysmetria was observed in reaching for objects. This defective incoordination was not made worse when patients were blindfolded. Nystagmus was not present and cranial nerves appeared intact. Tests for muscular strength showed no demonstrable motor impairment. Deep reflexes were active but within normal limits. There was no Babinski sign nor other evidence of pyramidal tract lesions. No clinically demonstrable changes in muscular tonicity were present. Gross sensation for heat, cold and pain were probably well preserved; tests for finer sensation could not be performed because of the low mental level.

Psychological examination on admission showed an identical mental age of 3 years (I. Q. 20). Ten years later a different psychological test showed a mental age of 4.3 in Adeline (I. Q. 26) and 4.1 in Mary (I. Q. 25). Blood factors were identical showing the presence of factor A, D, C and MN in both twins, and Wassermann reaction was negative. Spinal fluid examination showed normal values in both twins.

Air encephalogram was performed only in Mary and showed abnormal accumulation of air in the posterior fossa indicating the presence of cerebellar atrophy.

No significant changes in mental status and neurological symptomatology were observed over a period of 20 years. Cerebellar signs persisted but failed to progress. Considerable obesity developed in both twins, the difference in weight being always within 4 kg. One of the twins, Adeline, died at the age of 46 of bronchopneumonia.

The autopsy was performed 20 hours after death. Body was in excellent condition of general nutrition, subcutaneous fat was abundant and no wasting of musculature was observed. Recent consolidation of the lower lobe of the right lung was present. No other significant findings were noted in the thoracic and abdominal organs.

The skull was somewhat smaller than normal and the bones of the calvarium were abnormally thick. Brain was 980 gm. in weight (fig. 2). Convolutional pattern showed no gross deviation from the normal although secondary sulci and convolutions were fewer in number than in the normal brain. Lateral ventricles were moderately enlarged. Cerebellum showed grossly a striking reduction in volume (fig. 2). The atrophy involved

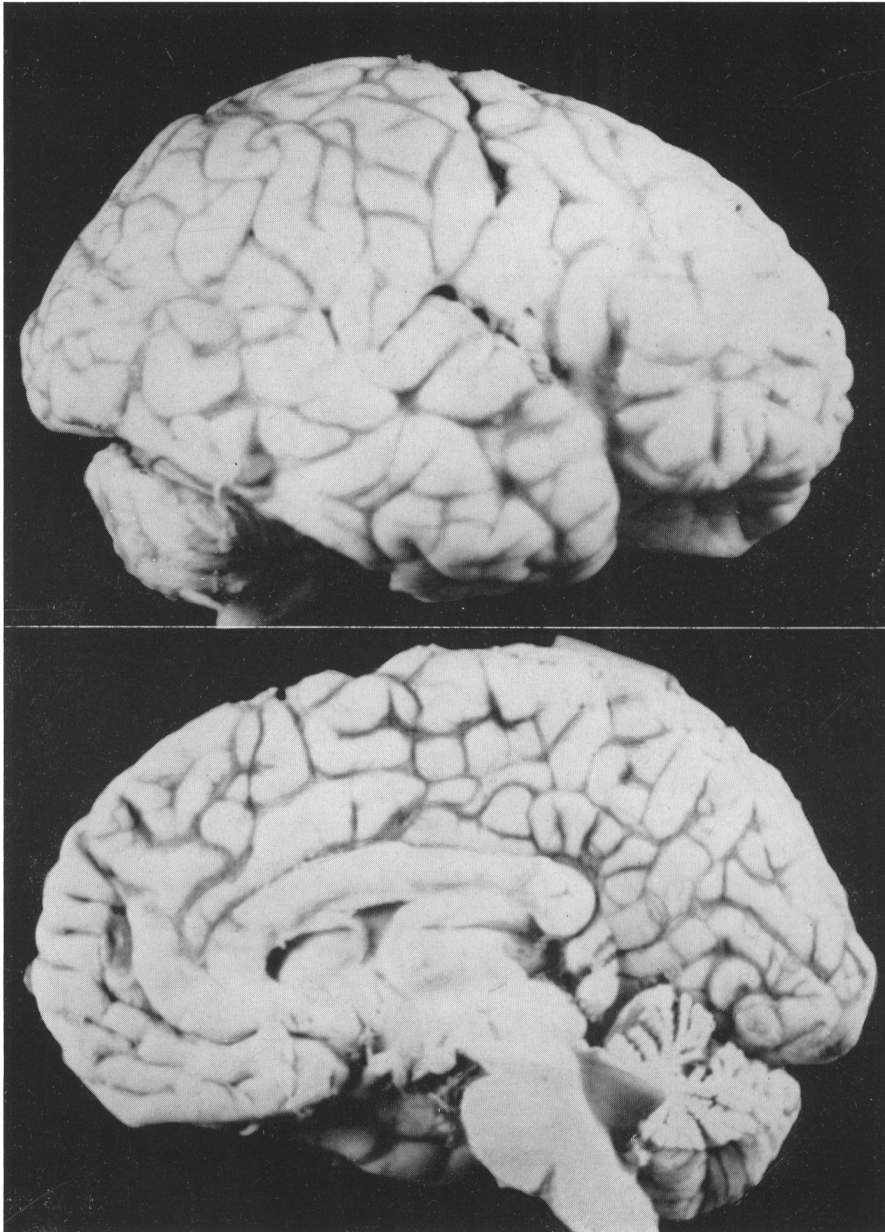


Fig. 2 - External aspect of the brain showing atrophy of the cerebellum

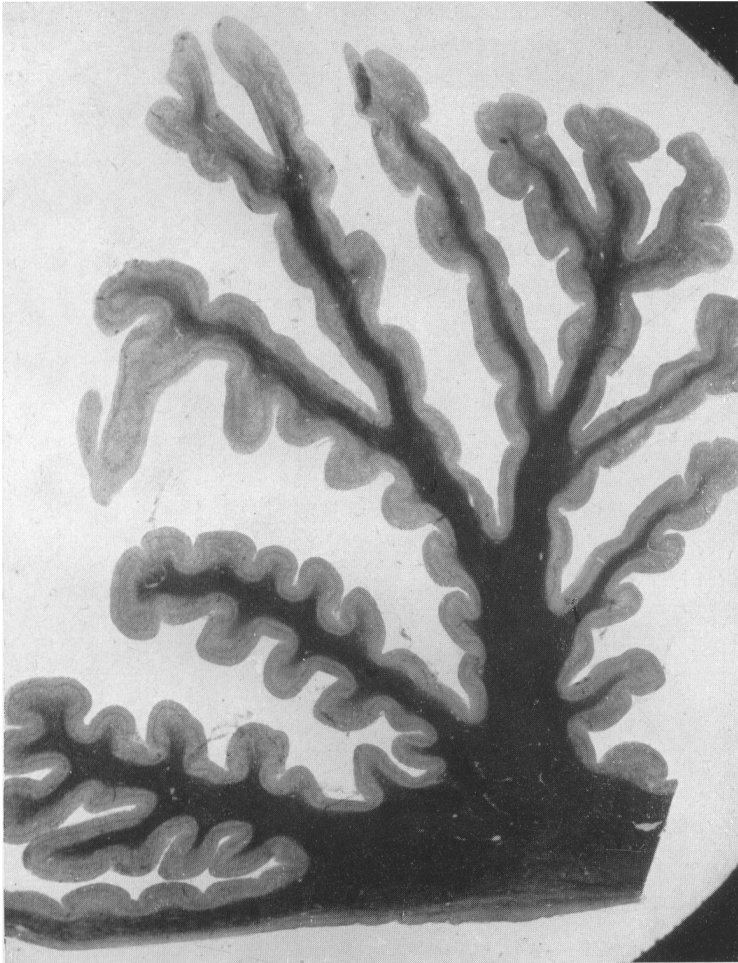


Fig. 3 - Section of cerebellum showing atrophy of lamellae.  
Weigert's stain. Very low power magnification

mostly the cortex of both vermis and hemispheres, the former being somewhat less affected than the latter. The central white matter of the cerebellum was only mildly atrophic. Cerebellar nuclei were grossly normal. Fourth ventricle was dilated. Cerebellar pedunculi appeared fairly well preserved. Pons was grossly normal. Red nucleus was not atrophic. Spinal cord appeared normal in size and gross structure.

On histological examination, cross sections of the cerebellum stained with hematoxylin and eosin or with Weigert's stain (fig. 3) showed conspicuous reduction in size of the cerebellar foliae with fair preservation of the medullary white substance, thus con-

firming the gross diagnosis of cerebellar cortical atrophy. With Nissl's method, at low power (fig. 4), there was a striking reduction in the number of the granules in every section examined, the few remaining pale granules being scattered throughout, among mildly proliferated glia cells. Golgi cells were well preserved and stood out conspicuously

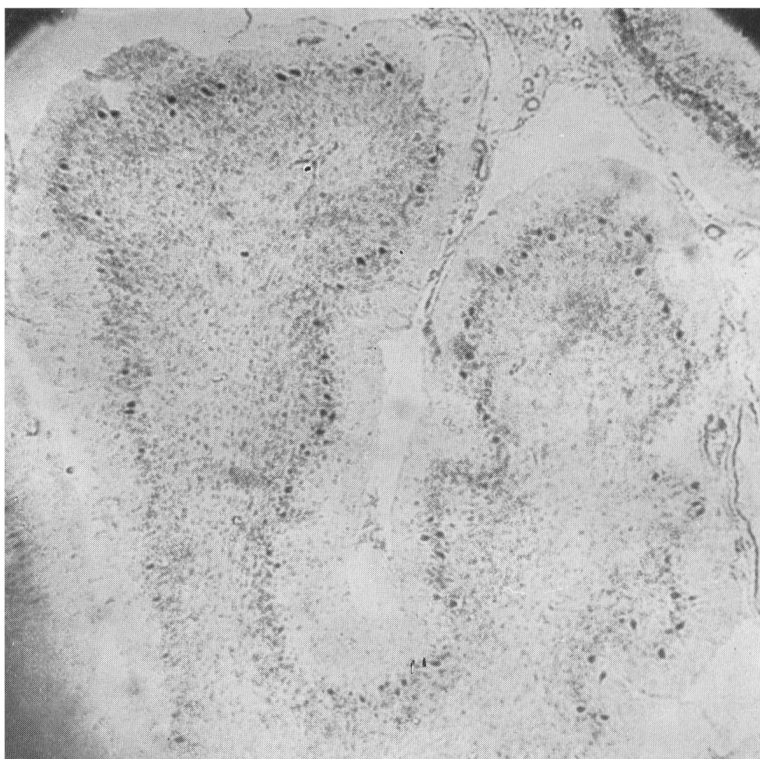


Fig. 4 - Section of cerebellum showing almost complete destruction of the granular layer and relatively well preserved Purkinje cells. Nissl's stain. Low power magnification

within the altered granular layer. The Purkinje cells were not markedly reduced in number but appeared distorted in shape and often misplaced, being at times in the molecular layer, at other times forming clumps of several elements oriented in various directions. Only a few Purkinje cells had a normal appearance, most cells showing degenerative changes such as hyperchromasia of cytoplasm or pycnosis of the nucleus. Bergman's glia appeared mildly proliferated. The molecular layer was reduced in size, the stellate cells had disappeared but many basket cells were present. Additional significant histological details of the lesions were obtained with Bielschowsky's and Bodian's me-

thods. Tangential fibers originating from the basket cells stood out conspicuously in the molecular layer while the radial fibers originating from the granules were absent; pericellular baskets were fairly well preserved. The Purkinje cells exhibited bizarre alteration of shape and size, their dendrites were distorted, truncated and often presented

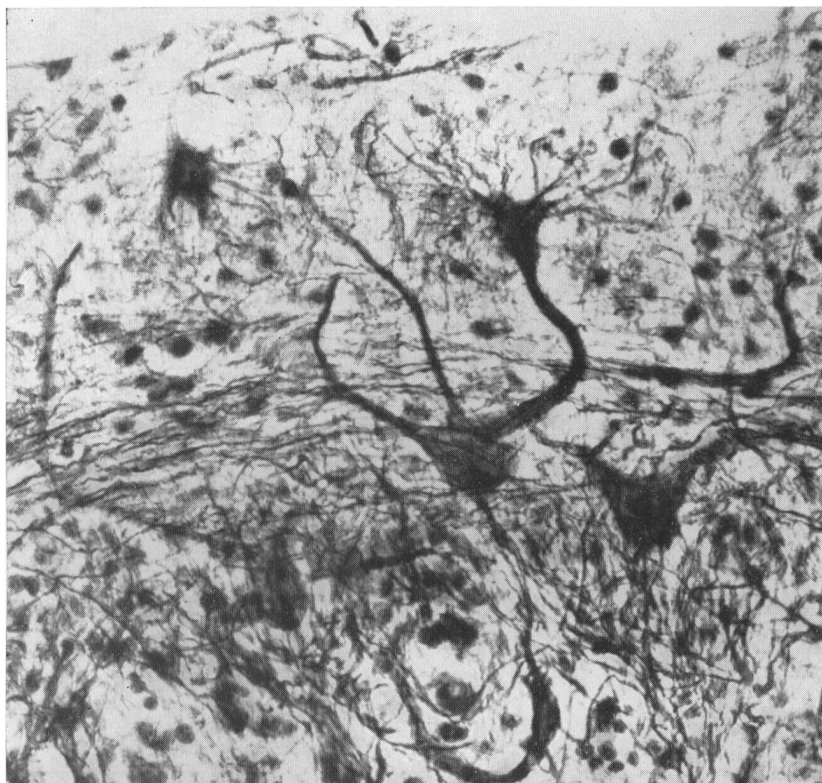


Fig. 5 - Distorted Purkinje cells showing two "cactus-like" formations of the dendrites (upper half), and a circumscribed ovalar swelling of the axon (lower half of the picture). Bielschowsky's silver stain.  
High power magnification

irregular enlargement. Not infrequently the axons showed circumscribed ovalar swellings which were strongly argentophilic (fig. 5). Curious formations were seen frequently in the molecular layer consisting of an argentophilic mass from which a large number of fibers radiated in a cactus-like fashion (fig. 5). Mossy fibers were apparently absent in the granular layer and in the myelin preparation the molecular layer and the subjacent white matter appeared devoid of myelin. Glia stains demonstrated an increase of both cellular and fibrillary glia in the molecular layer and white matter of the lamella. Oligo-

dendroglia and microglia were inactive. Preparations stained with Sudan showed no intra- or extracellular fat.

The medullary white matter of the cerebellum appeared intact in sections stained for myelin. Dentate and tectal nuclei contained a normal number of neurons. The formations connected directly with the cerebellum showed no significant lesions: in the red nucleus there was no atrophy of neurons and no glia proliferation; no decrease in nerve cells was observed in the pontine nuclei and the cervical spinal cord showed no degeneration of the cerebellar or other tracts. Only in the bulbar olives some decrease in the number of neuron cells of the posterior-medial segment was noted. The neurons of the olive contained a large quantity of pigment.

Substantia nigra and mesencephalic nuclei were intact. Thalami and basal ganglia showed no significant lesions. The neuron cells of the putamen contained a large amount of yellowish pigment. In the cerebral cortex there was a diffuse thinning of the neurons which was noticeable in all lobes and in all sections examined. Many cells appeared sclerotic and distorted. There was no significant increase of glia. Myelin appeared normal.

#### Comment

Summing up the significant features of the twins here presented, the clinical syndrome was characterized by non-progressive severe mental deficiency accompanied by manifestations of moderate impairment of the cerebellar function. Pathological examination of one member of the twins showed cerebellar lesions involving the granule cells, their axons (radial fibers), the stellate cells of the molecular layer, the secondary dendrites of the Purkinje cells and, to a much lesser degree, the Purkinje cells themselves. In addition, there was evidence of involvement of the distal portion of the mossy fibers and possibly also of some climbing fibers. Relatively well preserved appeared the basket cells, their axons (tangential fibers), the pericellular baskets, the Golgi cells, the central white matter of the cerebellum, the cerebellar pedunculi and all formations connected with the cerebellum. Since all data indicate that the twins were monozygous in nature and the cerebellar manifestations were identical in both members, there is every reason to believe that the cerebellar lesions of the living member were pathologically similar to those observed at the autopsy of the other twin.

A few cases showing similar clinical and pathological manifestations may be found in the medical literature. As far back as 1912, Vogt and Astwazaturow (4) described the case of an imbecile boy with cerebellar impairment and conspicuous pathological lesions of the granular layer; spino-cerebellar tracts were also involved. In Schob's case (5), although many features were typical of this group, several clinical and pathological findings were unusual. Some of Scherer's cases (6) of cerebellar atrophy may be included in this group although cortical lesions were less selective in distribution. The patient described by Santha (7) showed perhaps more extensive lesions of the Purkinje cells than in other cases of this disease. The patients reported by Norman (1), Jervis (3) and Ule (2) compared closely in all their clinical and pathologic details to the case here described.



In the attempt to understand the nature of the disease, the distribution and the type of the pathological lesions should be stressed. As far as distribution of the lesions is concerned, the granule cells appeared to be the most severely involved element and their destruction may account for the whole pathological picture of the cerebellum. In fact, the lesions of the radial fibers may be easily explained, since these fibers are the axons of the granules; the disappearance of the stellate cells and the partial involvement of the dendrites of the Purkinje cells might be interpreted as the manifestation of antegrade transneuronal degeneration and the lesion of mossy fibers may, likewise, be the result of retrograde transneuronal degeneration following destruction of granules. The hypothesis of a primary lesion of the granular layer already advanced by Norman (1) and Ule (2) seems, therefore, justified.

As far as type of the lesion is concerned, the histological evidence suggests the presence of an early degenerative or atrophic process. No signs of old or recent inflammation were present and no indication of an active, progressive process. Possibly, some attempt at regeneration might be seen in the formation of "cactus-like" and similar morphological peculiarity. The conclusion appears well founded that morphologically the process was one of primary systemic atrophy of the cerebellum, the system involved being the granular layer.

In this respect, the disease may be included in the large group of primary systemic atrophies of the cerebellum, although the lack of progressive character of the granular atrophy would tend to differentiate it from other forms. Four main types of cerebellar atrophies can be distinguished (8) according to the system involved: *a*) the spino-cerebellar type (Friedreich's disease); *b*) the ponto-olivo-cerebellar type (P. Marie's disease); *c*) the dentate-superior cerebellar peduncle type and, finally; *d*) the cortical types, among which the granular atrophy is included.

Evaluation of the etiological factors responsible for primary systemic atrophies of the cerebellum can be attempted only with the utmost caution. It seems well established, however, that genetic mechanisms play a decisive role in the first two types: Friedreich's disease is determined by a single recessive autosomal gene while in P. Marie's disease a single dominant gene is responsible for the condition (9), the two diseases being genetically distinct. It is interesting in this respect to note that at least four pairs of concordant monozygous twins affected with Friedreich's disease have been reported (10). In the majority of the few cases of atrophy of the granular layer thus far reported, genetic factors appear to be significant: in the two families reported by Norman (1), three out of seven and two out of six sibs were affected; in the family reported by Jervis (3) all three sibs suffered from the disease and there were two affected sibs in the family reported by Scherer (6). Unfortunately, in the other cases of the literature (2, 4, 5, 7), no family history is given. The case here reported is the first instance of concordant monozygous twins.

Although much evidence in favor of genetic factors in the determination of cerebellar atrophy of the granular type is available, one cannot disregard the fact that the granular layer of the cerebellum is particularly sensitive to certain toxic factors; tiophene, for instance, has a selective action on the granular layer in the experimental animal (11);

metabolic abnormalities occurring in cancerous cachexia or in hypoglycemic coma (12) often produce lesions of cerebellar granules which, although acute in nature, show some similarity to the cases of cerebellar atrophy of the granular type here described.

It would appear, therefore, that a toxic etiology of the condition cannot be entirely ruled out. Perhaps the two orders of apparently contradictory observations are not mutually exclusive and the two hypotheses, the genetic and the toxic, might be brought into accord. Much evidence has been accumulated which indicates that there exist in several diseases of the central nervous system, certain disturbances of the metabolism which are genetically determined (13). One may conceive then of a still unknown biochemical error, probably recessive in character, producing toxic substances which would cause cerebellar lesions of the type here described. Such a highly speculative hypothesis would explain all the facts already known and would stimulate the search for biochemical alterations in this and similar diseases.

### Summary

The case is described of monozygotic twins similarly affected with a form of cerebellar atrophy characterized by primary lesions of the granular layer. The clinical and pathologic aspects of the disease are briefly discussed and the role of genetic factors in the determination of the condition emphasized.

### References

1. NORMAN, R. M.: Primary Degeneration of the Granular Layer of the Cerebellum. An Unusual Form of Familial Cerebellar Atrophy Occurring in Early Life. *Brain*, 63: 365, 1940.
2. ULE, G.: Kleinhirnatrophie vom Körnertyp. *Deut. Ztsch. f. Nerven.*, 168: 195, 1952.
3. JERVIS, G. A.: Early Familial Cerebellar Degeneration. Report of Three Cases in One Family. *J. Nerv. and Ment. Dis.*, 111: 398, 1950.
4. VOGT, H. and ASTWAZATUROW, M.: Ueber angeborene Kleinhirnerkrankungen mit Beiträgen zur Entwicklungsgeschichte des Kleinhirns. *Arch. f. Psychiat.*, 49: 75, 1912.
5. SCHOB, F.: Weitere Beiträge zur Kenntnis der Friedreichähnlichen Krankheitsbilder. *Ztschr. f. d. ges. Neur. u. Psychiat.*, 73: 188, 1921.
6. SCHERER, H. J.: Beiträge zur pathologischen Anatomie des Kleinhirns. *Ztschr. f. d. ges. Neurol. u. Psychiat.*, 145: 335, 1933.
7. SANTHA, K.: Ueber das Verhalten des Kleinhirns in einem Falle von endogenen-afamiliärer Idiotie. *Ztschr. f. d. ges. Neurol. u. Psychiat.*, 123: 717, 1930.
8. WELTE, E.: Die Atrophie der Systems des Brückenfusse und der untern Oliven. *Arch. f. Psychiat. u. Nerven.*, 109: 649, 1939.
9. SJÖGREN, T.: Klinische und erbbiologische Untersuchungen ueber die Heredoataxien. *Acta Psychiat. et Neur. Suppl.* 27, 1943.
10. GEDDA, L.: *Studio dei Gemelli*. Ed. Orizzonte Medico, Roma, 1951.
11. UPNERS, T.: Experimentelle Untersuchungen ueber die lokale Einwirkung des Thiopens im Zentralnervensystem. *Ztschr. f. d. ges. Neurol. u. Psychiat.*, 166: 623, 1939.
12. LEIGH, A. D. and MEYER, A.: Degeneration of the Granular Layer of the Cerebellum. *J. of Neurol. and Psychiat.*, 12: 287, 1949.
13. JERVIS, G. A.: Mental Deficiency and Aberrant Metabolism in *The Biology of Mental Health and Disease*, p. 422, Hoeber, New York, 1952.