

Traumatic occurrence of chest wall tamponade secondary to subcutaneous emphysema

Michael Perraut, MD;^{*†} Daniel Gilday, MD;^{*†} Gordon Reed, MD^{*}

ABSTRACT

Subcutaneous emphysema is a physical finding that itself is usually perceived as benign yet rarely may, in and of itself, be life-threatening. We present an unusual case of a 67-year-old woman who developed delayed severe subcutaneous emphysema and tension pneumothorax from a rib fracture subsequent to a fall. We review the pathophysiology, manifestations and management options of this disorder. In patients whose clinical condition allows it, chest tube placement prior to intubation should be considered. Furthermore, positive end-expiratory pressure should be minimized. We present a case that illustrates how subcutaneous emphysema itself can be a potential cause of respiratory failure and tamponade physiology. In our case, a patient with traumatic subcutaneous emphysema developed respiratory failure and clinical deterioration after the introduction of positive pressure ventilation. In such rare scenarios, care should be taken to consider the absolute need for positive pressure ventilation without surgical decompression.

Keywords: subcutaneous emphysema, respiratory failure, trauma, tube thoracostomy

RÉSUMÉ

L'emphysème sous-cutané est un signe physique généralement perçu comme étant bénin, mais qui peut, dans de rares cas, menacer le pronostic vital. Nous rapportons un cas peu commun d'une femme de 67 ans chez qui sont apparus tardivement un emphysème sous-cutané grave et un pneumothorax sous tension consécutif à une fracture des côtes résultant d'une chute. Nous avons examiné la pathophysiologie, les manifestations et les options de prise en charge de ce trouble. La pose d'un drain thoracique avant l'intubation doit être envisagée chez les patients dont la condition clinique le permet. De plus, la pression expiratoire positive doit être réduite au minimum. Le cas qui fait l'objet de cet article illustre comment l'emphysème sous-cutané peut en soi causer une insuffisance respiratoire et une tamponnade. Il s'agit d'une patiente présentant un emphysème sous-cutané d'origine traumatique et ayant développé une insuffisance respiratoire et une détérioration clinique après l'introduction de la ventilation en pression positive. Dans de rares cas comme celui-ci, il faut prendre soin d'évaluer l'absolue nécessité d'avoir recours à la ventilation en pression positive sans décompression chirurgicale.

Introduction

Subcutaneous emphysema is a physical sign that is linked to disease processes ranging in severity from asthma exacerbations to tension pneumothoraces. On rare occasions,

severe subcutaneous emphysema can cause mechanical complications leading to obstructive shock. We present an unusual case of a 67-year-old woman who developed delayed severe subcutaneous emphysema and tension pneumothorax from a rib fracture subsequent to a fall. Her

From the Departments of *Emergency Medicine and †Internal Medicine, Christiana Care Health System, Newark, Del. Dr. Gilday is now affiliated with Olympia Emergency Services at Providence St. Peter Hospital, Olympia, Wash.

Submitted June 5, 2007; Revised Oct. 22, 2007; Accepted Nov. 5, 2007

This article has been peer reviewed.

CJEM 2008;10(4):387-91

rapid deterioration required positive pressure ventilation, which worsened her condition and limited chest wall expansion. We discuss the etiologies and management of life-threatening subcutaneous emphysema.

Case report

Paramedics were dispatched to a 67-year-old woman complaining of facial swelling and shortness of breath. When they arrived, she was in mild respiratory distress with significant facial plethora that worsened during transport. Her vital signs were pulse 112 beats/minute, respiratory rate 24 breaths/minute, blood pressure 159/62 mm Hg and O₂ saturation 94% on nonrebreather mask. Her family reported that she had fallen the night before, sustaining what they felt was a mild rib injury. She went to bed after taking ibuprofen for pain relief. They also reported that she had been recently diagnosed with emphysema, prompting empiric administration of nebulized albuterol. She experienced back pain before going to bed after the fall but had no further complaints until the following morning, when her facial swelling and shortness of breath occurred.

Paramedics on the scene suspected that an allergic reaction was taking place, and medical control approved administration of 0.5 mg of 1:1000 subcutaneous epinephrine and 50 mg of diphenhydramine intravenously. As the patient was being transported to the emergency department (ED), she became apneic and required bag mask ventilation by paramedics. In the ED, the patient appeared obtunded with poor inspiratory effort. She was tachycardic at 126 beats/minute, and her blood pressure was 170/83 mm Hg with an O₂ saturation of 85%. Coarse but equal breath sounds were auscultated bilaterally without wheeze. Pulses were palpable in all 4 of her extremities. The patient underwent rapid sequence intubation via direct laryngoscopy. The oropharyngeal mucosa was noted to be edematous. The patient was placed on mechanical ventilation with a tidal volume of 600 mL, respiratory rate of 12 breaths/minute and a positive end-expiratory pressure (PEEP) of 5 cm H₂O and 100% oxygen. After intubation, the patient's vital signs included a heart rate of 133 beats/minute, a blood pressure of 124/74 mm Hg and a pulse oximetry of 99%. She was given a second dose of diphenhydramine 50 mg intravenous (IV) along with 10 mg of IV dexamethasone.

Examination of the patient revealed tense swelling extending from her face to her chest that rapidly progressed to involve both upper extremities, her abdomen and bilateral thighs. This was believed to more likely represent subcutaneous emphysema than angioedema. After

intubation, the patient became hypotensive and an epinephrine infusion was started. An arterial blood gas revealed a pH of 7.07, a PCO₂ of 10.2 kPA, a PO₂ of 22.2 kPA and an HCO₃ of 3.3 kPA on volume control ventilation with 100% oxygen. A postintubation portable chest radiograph revealed severe subcutaneous emphysema and a posterior left seventh rib fracture but did not overtly demonstrate a pneumothorax (Fig. 1). Nevertheless, in the face of the patient's progressive decline, it was decided to proceed with left-sided tube thoracostomy, corresponding to the side of the fracture. Prior to the procedure, the patient's heart rate was 136 beats/minute, her blood pressure was 94/52 mm Hg and her O₂ saturation was 40% on pulse oximetry. Upon the initial skin incision, there was an extraordinary rush of air lasting several seconds, after which the patient's vital signs improved and she became easier to manually ventilate. Upon penetration of the pleura there was a second smaller rush of air and a persistent air leak was noted once the thoracostomy tube was attached to suction. Vital signs after chest tube insertion showed a heart rate of 94 beats/minute, blood pressure of 147/74 mm Hg and oxygen saturation of 99% on 100% oxygen.

The patient continued to be weaned from IV epinephrine and was transferred to our level I trauma centre, where she was admitted to the surgical intensive care unit (ICU). A subsequent CT scan of her chest revealed moderate right-sided pneumothorax, small left-sided pneumothorax,

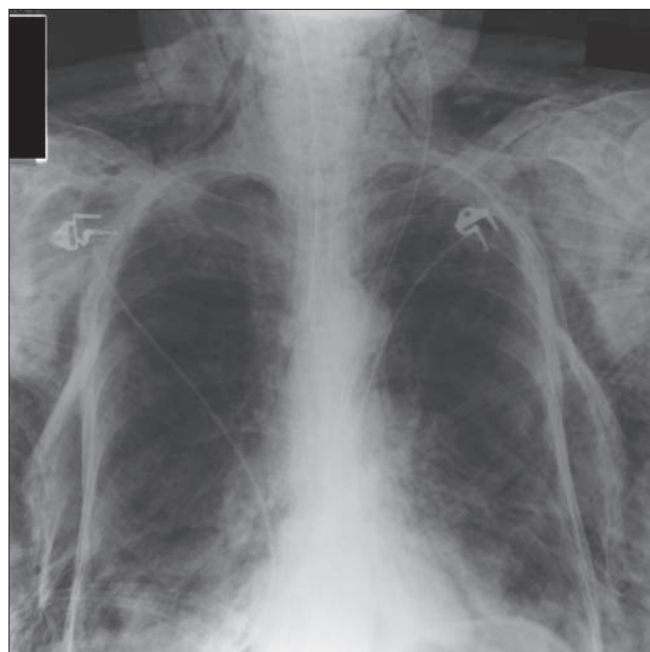


Fig. 1. Portable chest radiograph showing significant subcutaneous emphysema obscuring visualization of the left-sided pneumothorax.

massive subcutaneous emphysema extending into the tissue planes of the neck, a displaced left rib fracture and right anterior rib fractures (Fig. 2 and Fig. 3). The patient received a second chest tube on the right and was followed in the ICU until her air leaks resolved. Her chest tubes were removed and she was discharged in stable condition 7 days later.

Discussion

The differential diagnosis of acute facial swelling with dyspnea includes angioedema, severe soft tissue infection, superior vena cava syndrome and subcutaneous emphysema.¹ Subcutaneous air can result from a number of processes, including blunt or penetrating trauma, barotrauma, infection, malignancy or as a complication of surgical procedures.¹ Spontaneous subcutaneous emphysema can result from any process that acutely raises alveolar pressure, such as labour or excessive cough as can be seen in asthma or cannabis use.^{2,3} Traumatic causes of subcutaneous emphysema include rib fractures, tracheal rupture, esophageal perforation or direct introduction of air to the subcutaneous space through skin wounds.⁴⁻⁶ A thorough evaluation for the portal of air entry is required because of the mortality associated with some causes of subcutaneous emphysema.^{7,8} Infection should be ruled out, as the air may have been produced by gas-forming organisms, which require immediate antibiotics and surgical debridement. Chronic obstructive pulmonary disease (COPD) is a significant risk factor for the development of spontaneous subcutaneous emphysema. The coupling of bullous airspace

disease and alveolar over-distention primes the system for a rupture of the alveolar–interstitial membrane.⁹

Despite the multiple possible etiologies of subcutaneous emphysema, the pathophysiology underlying its development is often uniform. Most commonly, alveolar overdistention, as with a forceful Valsalva manoeuvre or positive pressure ventilation, results in the rupture of peripheral pulmonary alveoli. Air then tracks up the bronchovascular bundle in the interstitial space to the mediastinum. From there, the air may track to the pleural, peritoneal or pericardial spaces, as well as the fascial planes of the neck, chest wall and, occasionally, mammary tissues, resulting in subcutaneous emphysema.¹⁰ Pneumomediastinum presents with subcutaneous emphysema in 70% to 90% of cases.¹¹ Rarely, pneumomediastinum may develop from cervicofacial subcutaneous emphysema in cases of dental extraction, penetrating trauma or head and neck surgery.¹¹⁻¹³ Regardless of the cause, the signs and symptoms of subcutaneous emphysema depend largely on the amount of air present beneath the skin.

Most commonly, pneumomediastinum with subcutaneous emphysema is characterized by chest pain accompanied by thoracic crepitus and distention. Crepitance can often be noted over the supraclavicular fossa and a Hamman crunch may be auscultated over the precordium. Extensive subcutaneous air may cause significant periorbital swelling and ptosis. Distended neck veins indicate compromised peripheral venous return and possible tension pneumothorax or pneumomediastinum. Chest radiographs may reveal

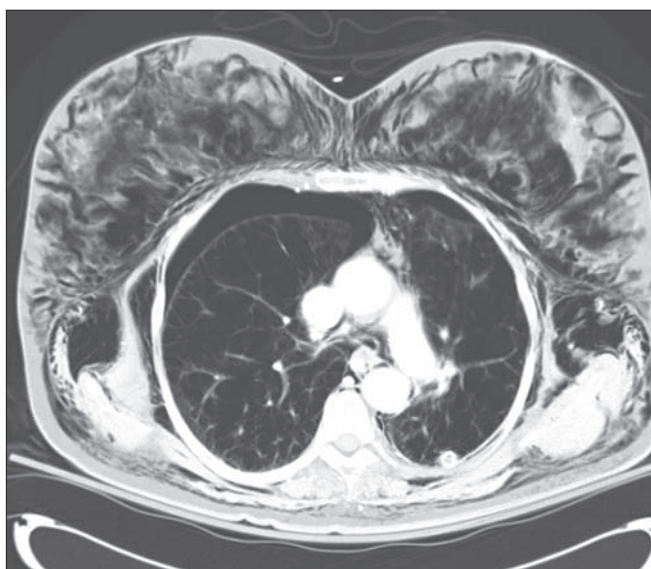


Fig. 2. Noncontrast CT scan of chest with bilateral pneumothoraces and left shift. Extensive subcutaneous emphysema again appears in multiple fascial planes.

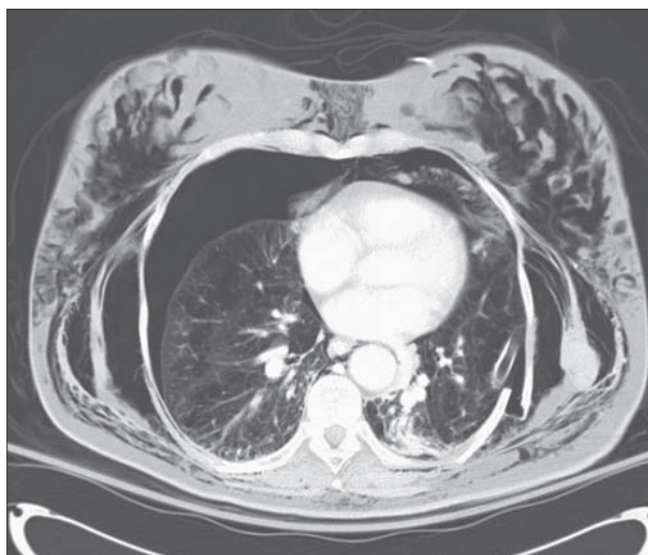

Fig. 3. Noncontrast CT scan of chest also showing bilateral pneumothoraces with shift. The thoracostomy tube is present on the left, and the displaced posterolateral rib fracture is seen on the left. Subcutaneous emphysema is tracking through multiple planes.

a pneumomediastinum or pneumothorax, although massive subcutaneous emphysema may limit the diagnostic value. Therefore, the absence of a pneumothorax with subcutaneous air on a chest radiograph should not exclude the need for surgical decompression, if warranted by the patient's condition.¹

Treatment of subcutaneous emphysema can vary from observation to mechanical ventilation. If the subcutaneous emphysema is regionally limited, painless and does not compromise vision, it may be observed, with resolution expected over 7 to 10 days. In patients recovering from thoracic surgery, painful cutaneous tension or palpebral occlusion from subcutaneous emphysema has been seen in 1.1% of patients.¹⁴ The management of this condition varies. It may involve the creation of infraclavicular "blow holes," insertion of Penrose drains and microdrainage with fenestrated 14-gauge angiocatheters.^{15,16} In cases with hemodynamic instability, the cause is likely obstruction of venous return either by tension pneumothorax or pneumomediastinum. In cases of trauma with subcutaneous emphysema, chest tube(s) should be placed prior to intubation with positive pressure ventilation, for a pneumothorax is likely, even in the absence of radiographic evidence.¹⁷ When associated with tracheal injuries, a pneumomediastinum can be resolved via tracheostomy, because the tissue planes in the neck track directly to the mediastinum.¹⁸ The successful treatment of shock secondary to a tension pneumomediastinum without pneumothorax using either tracheostomy or supportive care has been reported.¹⁹ The administration of prophylactic antibiotics is controversial.

Our case is unique in many ways. Our patient developed massive subcutaneous emphysema hours after a traumatic event and then rapidly progressed to respiratory arrest. While her delayed presentation was not unusual for either angioedema or pneumothorax with subcutaneous emphysema, clinical and historical inconsistencies warrant consideration for undisclosed trauma or abuse. Regardless, our patient's history, recent medication ingestion and decompensation were initially misinterpreted as an allergic reaction. It was only after symptoms progressed that subcutaneous emphysema was recognized. While the patient's change in mental status was likely due to hypercarbia, the mechanism was most likely caused by reduced ventilation from decreased chest wall compliance rather than obstructive lung disease. First, she had no respiratory symptoms the night before to suggest an exacerbation of COPD. Second, her mental status deteriorated acutely over the course of 30 minutes as her subcutaneous emphysema worsened, which is too short a time period to suggest that COPD was the primary process involved. Aubier and colleagues²⁰

postulate that oxygen administration in COPD exacerbation can worsen hypercarbia by both decreasing minute ventilation from reduced hypoxic drive and increasing physiologic deadspace from worsening ventilation-perfusion matching. However, this patient did not have long-standing hypercarbia, as evidenced by her lack of metabolic compensation, nor did her respiratory rate ever fall below 17 breaths/minute during transport. Finally, the patient's pulmonary mechanics rapidly improved once the subcutaneous emphysema was ventilated, whereas respiratory failure because of COPD often takes many days to improve.

The patient's rapid clinical deterioration, history of COPD, presence of rib fractures, hypotension and increasing airway pressure with positive pressure ventilation suggested tension pneumothorax. This was also supported by the dramatic improvement in her condition following a tube thoracostomy. We hypothesize that the patient's initial rib injury and resultant pneumothorax precipitated a life-threatening emergency: the extensive subcutaneous air restricted the chest rise, leading to inadequate ventilation and further barotrauma. Continued positive pressure ventilation fed a vicious cycle of hyperinflation of subcutaneous tissues and conversion of a presumed simple pneumothorax to a tension pneumothorax.

Ironically, the traditional management of following the "ABCs" of respiratory failure exacerbated rather than stabilized our patient's condition. In patients whose clinical condition allows it, chest tube placement prior to intubation should be considered. Furthermore, use of PEEP should be minimized. This case illustrates that subcutaneous emphysema is not only an important sign of underlying pathology, but also a potential cause of respiratory failure and tamponade physiology. In such rare scenarios, care should be taken to consider the absolute need for positive pressure ventilation without surgical decompression.

Acknowledgements: The authors thank Robert E. O'Connor, MD, MPH, for his advice and encouragement during the preparation of this report.

Competing interests: None declared.

References

1. Maggio KL, Maingi CP, Sau P. Subcutaneous emphysema: air as a cause of disease. *Arch Dermatol* 1998;134:557-9.
2. Heppner HJ, Sieber C, Schmitt K. "Usual" cannabis use producing an unusual incident. *Dtsch Med Wochenschr* 2007;132:560-2.
3. Jougon JB, Ballester M, Delcambre F, et al. Assessment of spontaneous pneumomediastinum: experience with 12 patients. *Ann Thorac Surg* 2003;75:1711-4.

4. Endara SA, Boldery JO, Bidstrup BP. Massive subcutaneous emphysema after blunt tracheal rupture. *J Trauma* 2001;50:761.
5. Winshall JS, Weissman BN. Images in clinical medicine. Benign subcutaneous emphysema of the upper extremity. *N Engl J Med* 2005;352:1357.
6. Betjes MG. Medical mystery — the answer. *N Engl J Med* 2000;342:740.
7. Siu W, Seifman BD, Wolf JS Jr. Subcutaneous emphysema, pneumomediastinum and bilateral pneumothoraces after laparoscopic pyeloplasty. *J Urol* 2003;170:1936-8.
8. Dolinski SY, Meek E, Groban L. An unusual case of subcutaneous emphysema. *Anesth Analg* 1999;89:150-1.
9. Launer J. Dr. Scrooge's casebook. *QJM* 2004;97:183-4.
10. Mannarino E, Lupattelli G, Schillaci G. A 32-year-old woman with breast swelling and crepitant rales. *CMAJ* 2004;171:1172.
11. Lopez-Pelaez MF, Roldan J, Mateo S. Cervical emphysema, pneumomediastinum and pneumothorax following self-induced oral injury: report of four cases and review of the literature. *Chest* 2001;120:306-8.
12. Stewart AE, Brewster DF, Bernstein PE. Subcutaneous emphysema and pneumomediastinum complicating tonsillectomy. *Arch Otolaryngol Head Neck Surg* 2004;130:1324-7.
13. Garcia E, Primm P. Penetrating neck trauma: an unusual presentation. *Pediatr Emerg Care* 2000;16:270-2.
14. Leo F, Solli P, Veronesi G, et al. Efficacy of microdrainage in severe subcutaneous emphysema [commentary]. *Chest* 2002;122:1498-9.
15. Cesario A, Margaritora S, Porziella V, et al. Microdrainage via open technique in severe subcutaneous emphysema [commentary]. *Chest* 2003;123:2161-2.
16. Beck PL, Heitman SJ, Mody CH. Simple construction of a subcutaneous catheter for the treatment of severe subcutaneous emphysema. *Chest* 2002;121:647-9.
17. Buchman TG, Hall BL, Bowling WM. Thoracic trauma. In: Kelen GD, Tintanalli JE, Stapczynski JS, editors. *Emergency medicine: a comprehensive study guide*. New York (NY): McGraw-Hill; 2004. p. 1595-1613.
18. Pandey M, Jain A, Mehta A, et al. Endotracheal intubation related massive subcutaneous emphysema and tension pneumomediastinum resulting in cardiac arrest. *J Postgrad Med* 2003;49:188-9.
19. van der Kleij FG, Zijlstra JG. Images in clinical medicine. Pneumomediastinum and severe subcutaneous emphysema. *N Engl J Med* 2000;342:1333.
20. Aubier M, Murciano D, Milic-Emili J, et al. Effects of the administration of O₂ on ventilation and blood gases in patients with chronic obstructive pulmonary disease during acute respiratory failure. *Am Rev Respir Dis* 1980;122:747-54.

Correspondence to: Dr. Michael Perraut, Department of Emergency Medicine, Christiana Care Health System, 4755 Oglethorpe-Stanton Rd., Newark DE 19718; mperraut@christianacare.org