


Letter to the Editor: New Observation

Syndrome of the Trepined: A Rare Presentation of Dorsal Midbrain Dysfunction

Eugénie Girouard^{1,2} , Elisabeth Meloche^{1,2}, Julien Rousseau^{1,2} and Alby Richard^{1,2}

¹Department of Neurosciences, Université de Montréal, Montreal, Quebec, Canada and ²Department of Specialized Medicine, Neurology Service, Centre Hospitalier de l'Université de Montreal, Montreal, Quebec, Canada

Keywords: craniotomy; dorsal midbrain syndrome; nystagmus; Parinaud syndrome; syndrome of the trephined

A 39-year-old Cameroonian female presented with uncontrolled focal seizures characterized by clonic head movements and conjugate right gaze deviation, dysarthria and worsening dysphagia, resulting in involuntary weight loss and dehydration over the past five months. Her past medical history was significant for a high-grade subarachnoid hemorrhage seven years prior due to a left anterior choroidal artery aneurysm rupture. She was treated with endovascular coiling and required decompressive craniectomy with cranioplasty and ventriculoperitoneal (VP) shunting due to hydrocephalus and delayed cerebral ischemia. Long-term complications included structural focal epilepsy, depression, central neuropathic pain, right homonymous hemianopsia and right spastic hemiparesis. Oculomotor examination revealed new onset skew deviation, vertical gaze palsy and convergence retraction nystagmus (video 1).

An electroencephalogram confirmed ongoing electro-clinical seizures originating from the left temporal lobe. The patient's antiseizure medications were adjusted, and seizure control was achieved with lacosamide 150 mg twice daily and levetiracetam 750 mg twice daily.

MRI of the brain showed a sunken aspect of the fronto-temporo-parietal craniectomy flap with decreased volume of the left lateral ventricle and crowding of the quadrigeminal cistern (Figure 1A–C). The VP shunt was then ligated as a temporary measure, which resulted in the re-expansion of the ventricular system and of the craniectomy flap (Figure 2A, B). The patient then underwent a revision of the VP shunt with valve change and replacement of the cranial flap a month later. This was complicated by an epidural collection at the level of the flap (Figure 3A, B), which resolved spontaneously within two weeks (Figure 4A, B). Further medical complications included urinary tract infection, syndrome of inappropriate antidiuretic hormone secretion, anemia, aspiration pneumonia and delirium. Due to these numerous medical complications, it is unclear if the patient showed clinically significant improvement. Her oculomotor examination partially improved, but she remained profoundly dysarthric and dysphagic.

Approximately two weeks after the procedure, the patient developed septic shock, hypoxemic respiratory insufficiency and a profound alteration of consciousness. After discussions with the family, the patient was oriented toward comfort care, and she passed away on the palliative care unit a few days later.

Syndrome of the trephined (SoT) is an underrecognized and underreported entity with a poorly defined occurrence ranging from 1% to 65% of patients with craniotomies.¹ There is no consensus as to the definition, diagnostic criteria or best practice treatment guidelines of this condition. It is thought to occur from a paradoxical inward shift of the brain structures because of the pressure gradient between the atmospheric and intracranial pressures.^{2–5} This syndrome presents within weeks to months, even up to seven years, after craniectomy with clinical findings ranging from discomfort at the site of craniotomy, depressive symptoms, sensorimotor dysfunction or even seizures.^{1–5} Most patients present with a sinking flap morphology at the site of craniotomy, although numerous cases in the literature exist without this finding. Diagnosis of this condition is challenging and often made retrospectively. It can present with a wide array of symptoms, none of which are specific to SoT; it is therefore important to carefully exclude other confusing conditions. Highly suggestive clinical features include a temporary alleviation of symptoms in the supine position and definite improvement following cranioplasty. Radiological features, as were found in our patient, include shifting brain structures such as sunken skip flap, paradoxical herniation, paradoxical midline shift and compression of the third ventricle.

Few studies have reported cases of SoT in patients with a VP or lumboperitoneal shunt.^{2–5} The gradient between the atmospheric and intracranial pressure may be further exacerbated by the VP fluid drainage from the shunt or even dehydration, both of which were present in the case being reported here.^{2,3,5} Another plausible explanation in our case is that bone flap resorption from the prior cranioplasty may have resulted in decreased isolation from atmospheric pressure. The mainstay of treatment consists in restoring the pressure dynamics within the cranial vault. Some

Corresponding author: Eugénie Girouard; Email: eugenie.girouard.med@ssss.gouv.qc.ca

Cite this article: Girouard E, Meloche E, Rousseau J, and Richard A. Syndrome of the Trepined: A Rare Presentation of Dorsal Midbrain Dysfunction. *The Canadian Journal of Neurological Sciences*, <https://doi.org/10.1017/cjn.2025.18>

© The Author(s), 2025. Published by Cambridge University Press on behalf of Canadian Neurological Sciences Federation. This is an Open Access article, distributed under the terms of the Creative Commons Attribution licence (<https://creativecommons.org/licenses/by/4.0/>), which permits unrestricted re-use, distribution and reproduction, provided the original article is properly cited.

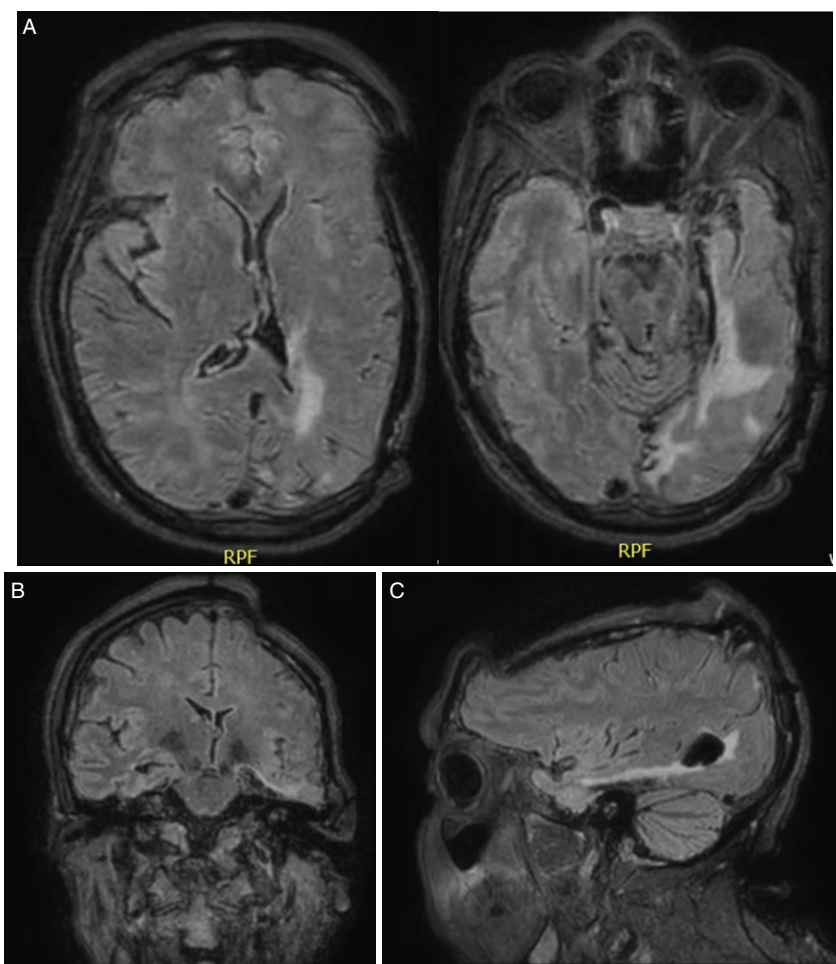


Figure 1. (A) Axial, (B) coronal and (C) sagittal FLAIR non-contrast MRI of the brain of a 39-year-old patient obtained at admission showing left temporal encephalomalacia, a sunken craniectomy flap, crowding of the quadrigeminal cistern and decreased volume of the left lateral ventricle suggestive of cranial hypotension.

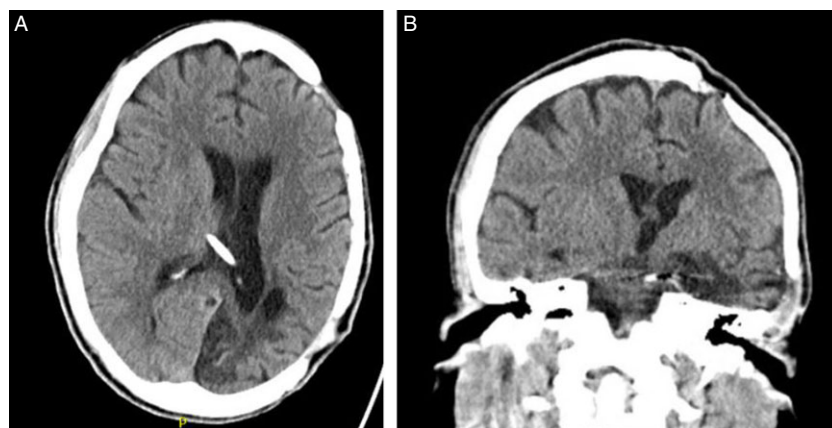


Figure 2. (A) Axial and (B) coronal non-contrast head CT of a 39-year-old patient with syndrome of the trephined after ventriculoperitoneal shunt ligation showing reestablished cranial flap alignment and ventricular re-expansion.

authors recommend temporarily occluding the VP shunt to allow re-expansion of the defect prior to craniotomy.⁶ Cranioplasty should then be performed to correct the pressure gradient and restore neurological function.^{1,3} Studies have shown that this intervention led to significant improvements in quality of life, decreased disability and positive neurological outcomes regarding motor abilities and cognition.^{1,3,5} Although the exact timing of cranioplasty remains to be determined, some authors suggest that early cranioplasty may be associated with more favorable outcomes.^{1,3}

Parinaud or dorsal midbrain syndrome classically presents as a triad of supranuclear upgaze palsy, convergence retraction nystagmus and pupillary light-near dissociation. The complete triad is found in approximately 65% of patients. Other possible findings include upper eyelid retraction or Collier's sign, conjugate primary position downgaze or setting sun sign and loss of convergence. Patients may report difficulty looking up, reduced near visual acuity, diplopia or oscillopsia.⁷ Thorough investigations including neuroimaging should be undertaken to identify the underlying cause and initiate treatment accordingly.

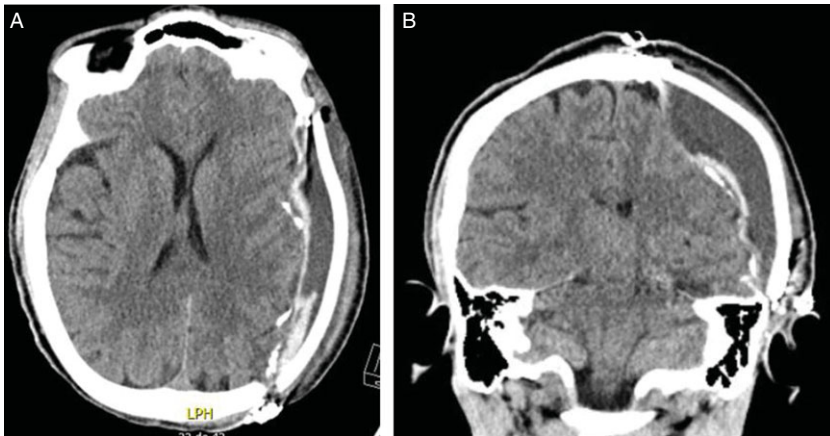


Figure 3. (A) Axial and (B) coronal non-contrast head CT of a 39-year-old patient with cranioplasty complicated by epidural hematoma showing midline shift and mass effect.

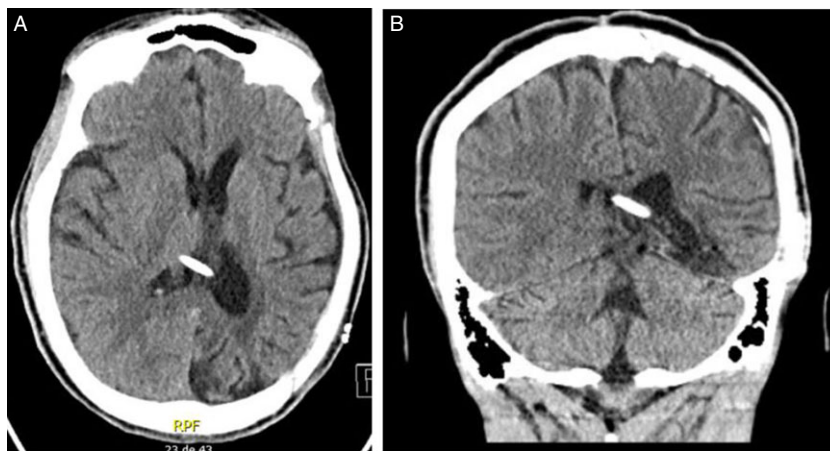


Figure 4. (A) Axial and (B) coronal non-contrast head CT of a 39-year-old patient with syndrome of the trephined after ventriculoperitoneal shunt ligation followed by cranioplasty showing reestablished cranial flap alignment and ventricular re-expansion and resolution of epidural hematoma.

To our knowledge, only one other reported case of oculomotor dysfunction, also characterized by upgaze palsy, related to SoT has been published.⁸ In our case, we hypothesize that the paradoxical shifting of brain tissue due to SoT may have caused crowding of the quadrigeminal cistern and disruption of the vertical oculomotor centers such as the interstitial nuclei of Cajal and the rostral interstitial nucleus of the medial longitudinal fasciculus, resulting in vertical gaze palsy as well as the supranuclear fibers that normally inhibit divergence or convergence neurons. We further hypothesize that her worsening dysarthria and dysphagia may have been explained similarly by a disruption of the corticobulbar tracts. An alternative explanation is that her worsening seizures in the context of a SoT would have exacerbated her dysarthria and dysphagia. While the dorsal midbrain syndrome triad was incomplete in this case, our patient did show improvement following cranioplasty, further comforting our diagnosis of SoT.

Although most cases of SoT occur weeks to months after craniectomy, some have reported cases after up to seven years.¹ Whether it was caused by excessive VP shunt drainage possibly exacerbated by bone resorption in our patient remains unclear, but this might explain the delayed onset of symptoms. The re-expansion of the left ventricle and the craniotomy flap following shunt ligation further support this possibility.

To summarize, we report a case of a post-craniectomy patient presenting with dorsal midbrain syndrome, worsening seizures and deteriorating neurological function in the context of a sunken

craniotomy flap, consistent with SoT. Diagnosis of this syndrome is often challenging, but recognizing such cases is essential as they are often underreported and necessitate prompt neurosurgical consultation for cranioplasty to optimize the chances of restoring neurological function.

Supplementary material. The supplementary material for this article can be found at <https://doi.org/10.1017/cjn.2025.18>.

Acknowledgments. No other contributors participated in the study.

Author contributions. All authors contributed to the conception and design of this study. Eugénie Girouard drafted the manuscript. Elisabeth Meloche, Julien Rousseau and Alby Richard revised it critically for important intellectual content. All authors and coauthors have reviewed and approved the contents of this manuscript. Eugénie Girouard and Julien Rousseau contributed to the preparation of visual elements, data extraction and patient consent. Alby Richard contributed to the supervision.

Funding statement. Funding sources and conflict of interest: The authors declare that no funding was received for this work, and there are no conflicts of interest relevant to this work.

Financial disclosures for the previous 12 months: The authors declare that there are no additional disclosures to report.

Competing interests. None.

Ethical compliance statement. This article did not require an IRB approval, as it was a case report. Information was anonymized, and we obtained an

informed consent form. We confirm that we have read the journal's position on issues involved in ethical publication and affirm that this work is consistent with those guidelines.

References

1. Sveikata L, Vasung L, El Rahal A, et al. Syndrome of the trephined: clinical spectrum, risk factors, and impact of cranioplasty on neurologic recovery in a prospective cohort. *Neurosurg Rev.* 2022;45:1431–1443.
2. Garg R, Aggarwal A, Salunke P. Importance of calvaria in cerebrospinal fluid dynamics: a case of ventriculomegaly and sinking flap syndrome after decompressive craniectomy. *Asian J Neurosurg.* 2018;13:128–129.
3. Jeyaraj P. Importance of early cranioplasty in reversing the “syndrome of the trephine/motor trephine syndrome/sinking skin flap syndrome. *J Maxillofac Oral Surg.* 2015;14:666–673.
4. Rana I, Tripathy LN, Jain H. Syndrome of the trephined following ventriculo-peritoneal shunt in a post-traumatic hydrocephalus patient. *Neurol India.* 2022;70:1676–1677.
5. Ashayeri K, M Jackson E, Huang J, Brem H, R Gordon C. Syndrome of the trephined: a systematic review. *Neurosurgery.* 2016;79:525–534.
6. Liao CC, Kao MC. Cranioplasty for patients with severe depressed skull bone defect after cerebrospinal fluid shunting. *J Clin Neurosci.* 2002;9:553–555.
7. Feroze KB, Patel BC. *Parinaud Syndrome.* StatPearls Publishing LLC; Treasure Island (FL). 2024. Disclosure: Bhupendra Patel declares no relevant financial relationships with ineligible companies.: StatPearls Publishing Copyright © 2024.
8. Gottlob I, Simonsz-Tóth B, Heilbronner R. Midbrain syndrome with eye movement disorder: dramatic improvement after cranioplasty. *Strabismus.* 2002;10:271–277.