

---

# New Developments in the Surgery for Parkinson's Disease

*Christopher Honey, R.E. Gross and A.M. Lozano*

---

**ABSTRACT:** Despite optimization of medical therapy, a large number of patients with Parkinson's disease continue to be disabled. For this group, alternate treatment strategies such as neurosurgical intervention can be considered. Recent advances in neurosurgical techniques and in understanding the pathophysiology of motor disturbances in PD have made surgery safer and more effective. Functional neurosurgical procedures to lesion or electrically modulate dysfunctional basal ganglia circuits or to protect or restore dopaminergic transmission are being increasingly used. These procedures are having a profound impact on the motor disturbances of PD and are producing important improvements in quality of life of patients.

**RÉSUMÉ:** Nouveautés dans le traitement chirurgical dans la maladie de Parkinson. Malgré des améliorations importantes dans le traitement de la maladie de Parkinson (MP), un grand nombre de patients demeurent invalides. Pour ce groupe de patients, d'autres stratégies de traitement comme la neurochirurgie peuvent être considérées. Les progrès techniques récents en neurochirurgie et dans la compréhension de la physiopathologie des troubles moteurs dans la MP ont diminué les risques de la chirurgie et ont augmenté son efficacité. Les interventions neurochirurgicales fonctionnelles pour créer une lésion ou moduler électriquement les circuits dysfonctionnels ou pour protéger ou rétablir la transmission dopaminergique sont de plus en plus utilisées. Ces interventions ont un impact important sur les troubles moteurs dans la MP et procurent aux patients des améliorations importantes de leur qualité de vie.

Can. J. Neurol. Sci. 1999; 26: Suppl. 2-S45-S52

---

Parkinson's Disease (PD) affects approximately 3 in 1000 Canadians.<sup>1</sup> The incidence in age matched cohorts has increased over the years and our aging population will mean even more cases in the future.<sup>2</sup> Despite the best available medical therapy, there continues to be a large segment of the parkinsonian population that continues to have significant disability and for whom alternate treatment strategies are important.

There has been a tremendous resurgence in the surgical therapy for PD. This has been prompted by a combination of factors. First, conventional medical therapies can lose their effectiveness over time, have been ineffective in preventing longterm decline and can in many cases be associated with unacceptable side effects including dopa-induced involuntary movements (dyskinesia) and psychiatric complications. Second, improved neurosurgical techniques have allowed for more consistent results with fewer complications. Third, increased understanding of basal ganglia physiology has provided models which account for some of the pathophysiology of parkinsonian features and a scientific rationale for surgical intervention. This increased understanding has stimulated interest in new surgical targets and strategies. Fourth, transplantation therapy has raised the possibility of longterm reversal of striatal dopamine loss. This review will discuss the surgical treatment of PD in 3 broad categories: i) lesions, ii) deep brain stimulation, iii) transplantation and growth factor therapy. Each section will deal with the background and current indications for these therapies.

## LESIONING

### Thalamotomy

While ventral intermediate (Vim) nucleus thalamotomy is quite effective in relieving tremor,<sup>3</sup> its effects on the other clinical features of PD are lesser and more variable. For this reason, thalamotomy is restricted to patients who have predominantly drug-resistant tremor. This represents a small proportion of the PD population which means that for most patients, the thalamus is not the most appropriate surgical target. Chronic deep brain stimulation of the thalamus, which has similar indications, is a non-lesional alternative to thalamotomy (as discussed below).

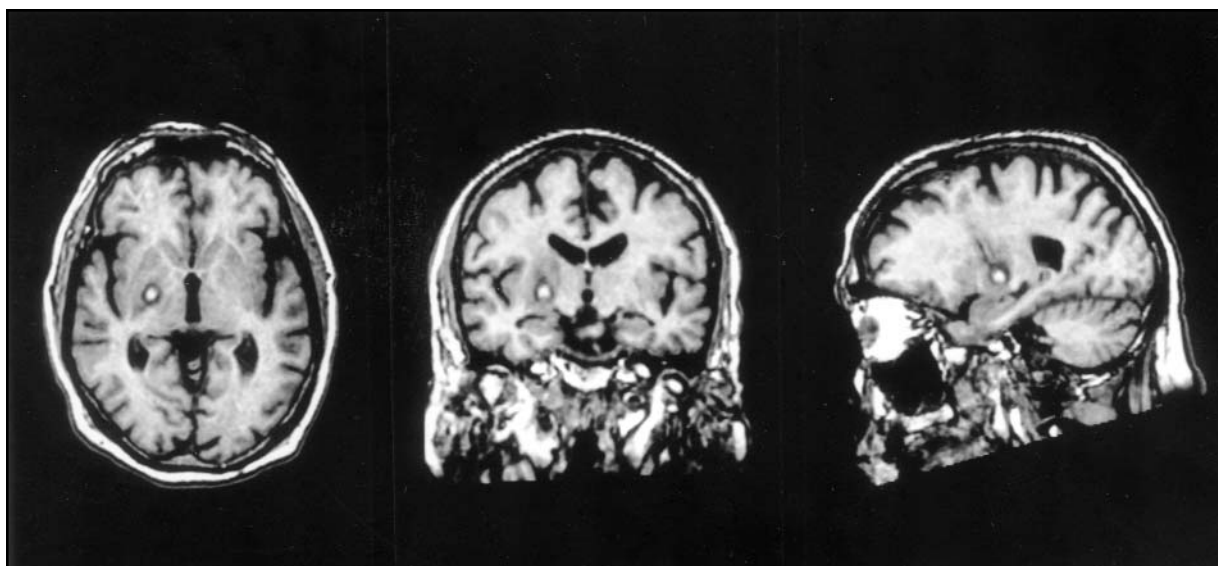
### Pallidotomy

Pallidotomy (Figure 1) is currently the most widely used surgical procedures for advanced PD. Since its reintroduction by Laitinen in 1992,<sup>4</sup> there have been a number of well-designed trials,<sup>5-13</sup> and longer-term studies documenting lasting efficacy are beginning to emerge.<sup>12,13</sup> Nevertheless, there remain a number of issues that have yet to be resolved, in particular its role in relation to other emerging surgical options.

---

From the Division of Neurosurgery, Department of Surgery, University of British Columbia (CH), and University of Toronto (AML, REG)

Reprint requests to: Andres Lozano, Division of Neurosurgery, University of Toronto, The Toronto Hospital, Western Division, 399 Bathurst Street, Toronto, Ontario, Canada M5T 2S8



**Figure 1:** *GPi pallidotomy. This T1 weighted MR image taken 24 hours after surgery shows a right pallidal lesion in a patient with Parkinson's disease in axial, coronal and sagittal planes.*

### Pathophysiological rationale for pallidotomy

In PD, loss of dopaminergic input to the striatum leads to overactivity of the basal ganglia output structures, the internal segment of the globus pallidus (GPi) and the substantia nigra pars reticulata (SNR).<sup>14,15</sup> Current models of basal ganglia function suggest that the heightened GABAergic inhibitory outflow from these output nuclei in parkinsonian states “overinhibits” both thalamic targets (and hence downstream cortical fields) and brainstem targets, leading to the disturbances of motor function.<sup>16,17</sup> The rationale for surgery is based on disrupting this abnormal activity in GPi through lesioning (or chronic electrical blockade) to disinhibit the motor thalamus and cortical motor areas and to normalize motor function. Indeed activation of the supplementary motor area (SMA) has been demonstrated with functional brain imaging following pallidotomy<sup>18,19</sup> (and pallidal deep brain stimulation).<sup>20</sup> However, the contribution of descending pallidal-brainstem pathways, which are poorly defined, is not yet understood. Disinhibition of these pathways (e.g., pedunculopontine, tectospinal) may underlie some the effects of pallidotomy, particularly the axial manifestations of PD and postural instability and gait disturbance (PIGD).

### Indications for pallidotomy

Ideal candidates for surgery are patients with the diagnosis of idiopathic PD who (1) continue to be disabled despite the best available medical treatment, (2) have a history of responsiveness to L-dopa, and (3) have developed complications of long-term L-DOPA treatment (motor fluctuations, wearing-off, drug-induced involuntary movements (dyskinesia)). A complete course of pharmacotherapy is mandatory before surgery, but it is important to recognize when diminishing gains can be expected from medication changes. Contraindications to surgery include (1) parkinsonian syndromes other than PD, (2) fragile medical condition, and (3) cognitive impairment. Parkinsonian features that respond to pallidotomy include drug induced dyskinesias, rigidity, tremor, and bradykinesia. Speech, cognitive, psychiatric, auto-

nomous and gait disturbances are less responsive or unresponsive to unilateral pallidotomy.

### Outcome of pallidotomy

Leksell provided evidence that targeting the posteroventral (PV) pallidum was more effective than the previous target in the anterodorsal pallidum.<sup>21</sup> Laitinen et al. confirmed the efficacy of PV pallidotomy in 38 patients.<sup>4</sup> Two early pilot series used the Core Assessment Program for Intracerebral Transplantation (CAPIT) protocol,<sup>22</sup> which incorporates the United Parkinson's Disease Rating Scale (UPDRS), a dyskinesia rating scale and timed motor tests, to demonstrate the efficacy of microelectrode-guided GPi pallidotomy.<sup>5,23</sup> A number of studies have now shown efficacy at three and six months, with improvements in off-period UPDRS total motor scores (17 - 46% decrease from baseline) and on-period drug-induced dyskinesias (43 - 92% decrease).<sup>5-13,23</sup> Improvements in on-period functioning have generally not been reported, except for dyskinesia, although patients spend more time in the on-period. Effects are greater for contralateral bradykinesia, rigidity and tremor than for ipsilateral signs. Improvements in PIGD are less significant (31% decrease) and more short-lived.<sup>11,12</sup> Longer-term trials have demonstrated continued efficacy for off-period signs (except PIGD) at two years<sup>12</sup> and three years<sup>13</sup> follow-up. The benefits gained from pallidotomy are associated with improvements in patients' activities of daily living, and can restore some measure of functional independence in patients.<sup>12</sup>

The proximity of the posteroventral pallidum to the optic tract and internal capsule subjects these structures to risk from pallidotomy. Transient effects consist mainly of facial paresis or dysarthria related to encroachment of edema along the internal capsule. Transient changes in mental status are not uncommon. The incidence of visual field defects ranges from 0 - 8% in series that used microelectrode mapping for target selection,<sup>12,24</sup> and 0 to 40 % in those series that did not.<sup>21,25</sup>

## BRAIN STIMULATION FOR PD

Chronic brain stimulation is emerging as an alternative to the placement of lesions for the treatment of Parkinson's disease (Figure 2). The targeting and localization procedures for lesioning or deep brain stimulation (DBS) are, at first approximation, similar. Only in the last stage of surgery, when the target has been identified and physiological corroboration has been obtained do the two techniques differ. Modern DBS electrodes are multipolar and are activated by implanted programmable pulse generating devices that are fitted with lithium batteries which are capable of lasting several years. The large number of possible stimulation parameters (choice of active electrodes, rate, pulse width, frequency and amplitude of stimulation) enhance the adaptability of deep brain stimulation. The advantage of stimulation versus lesioning is its safety, reversibility and adaptability. These important properties of the stimulation technique lessen the severity and impact of adverse effects and provide the possibility of adjustment of stimulation parameters as the clinical features change over time. This is at the expense of the extra time and effort required to carefully study the effects produced with each new setting.

### Vim thalamus DBS for tremor

The ventral lateral thalamic nuclei are populated by neurons that fire in synchronous bursts whose timing is similar to peripheral tremor as originally described by Guiot et al., in 1962.<sup>26</sup> Neurosurgeons have known that intraoperative electrical stimulation in areas of the thalamus populated by tremor-synchronous cells can be sufficient to momentarily arrest tremor. Lesions in the ventral intermediate nucleus (Vim thalamotomy) are highly effective but can be associated with motor, sensory, cerebellar, speech and other complications. Because of the potential serious complications and the irreversible nature of lesioning the nervous system, neurosurgeons have sought alternate procedures to achieve the effectiveness of thalamotomy while reducing the risk of unwanted effects.

The work of Benabid and his colleagues<sup>27</sup> in 117 patients (80 PD, 20 essential tremor and 17 other) indicates that chronic VIM stimulation is highly effective for tremor, with over 85% of patients having a very good or excellent response with little or no tremor evident in the contralateral arm. While effective for

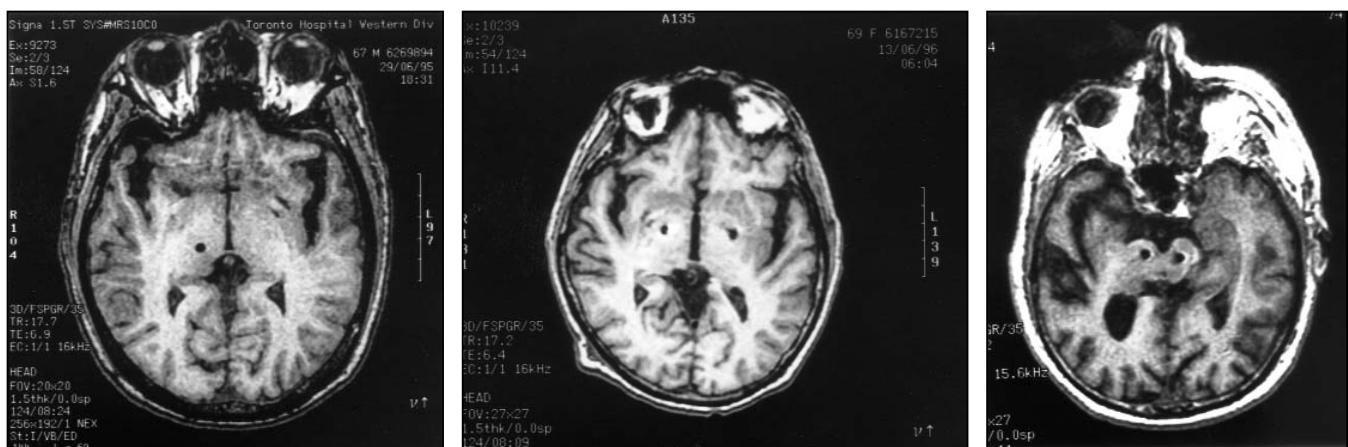
tremor, VIM stimulation did not influence bradykinesia or rigidity. Recently, Koller et al.<sup>28</sup> have shown an 80% reduction in contralateral arm tremor in 29 patients with essential tremor (ET) and 24 patients with PD tremor with VIM DBS at one year follow up. This was associated with a greater improvement in disability for ET patients than for PD patients who have associated non-tremor motor dysfunction. The side effects of stimulation are reversible, and usually mild and accepted provided the intensity of stimulation produces significant benefits on tremor.

### Globus pallidus DBS

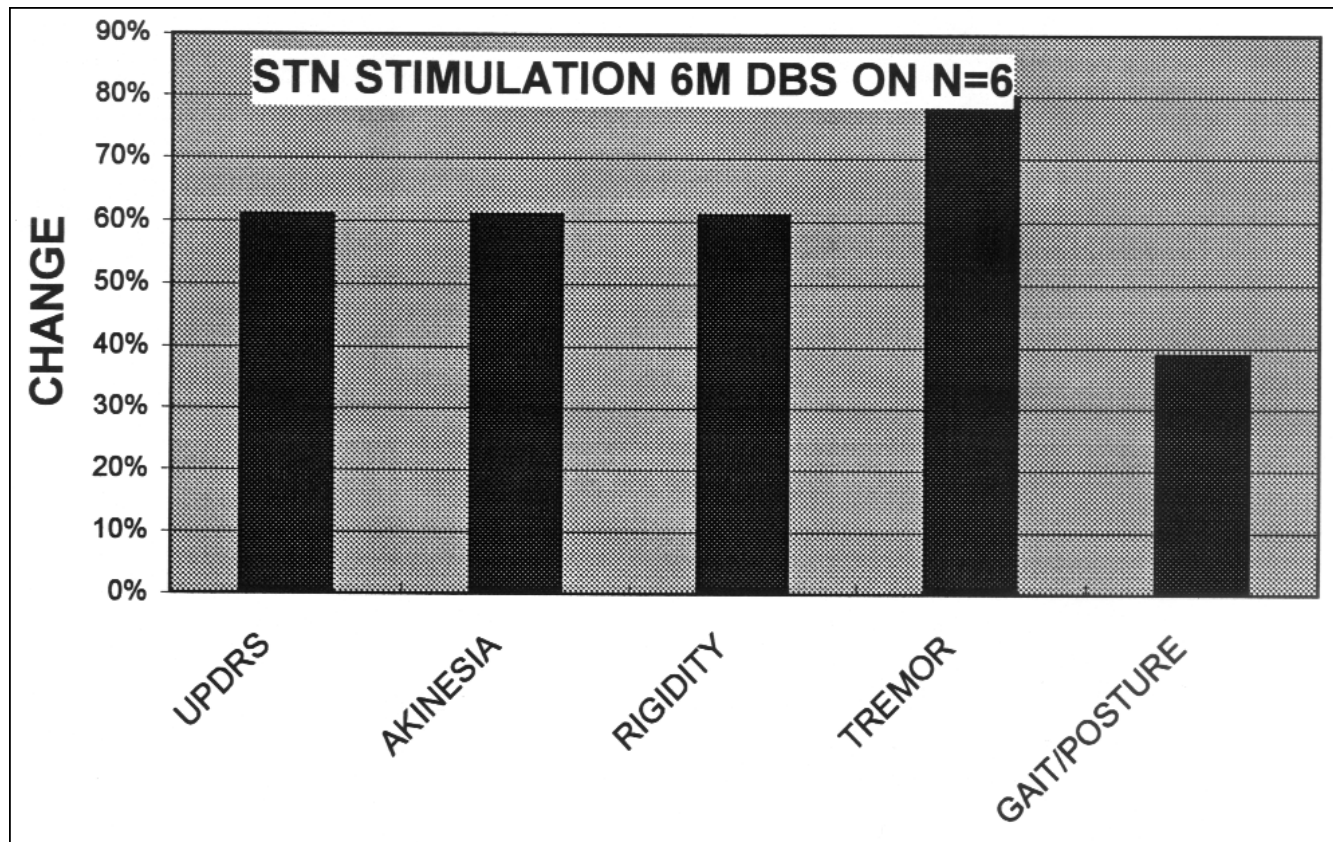
To date, several reports outlining the clinical features of bilateral GPi stimulation have appeared. Siegfried and his group<sup>29</sup> used a monopolar electrode with stimulation parameters of 130 HZ, 210 microseconds, and intensities of 0.75 to 1 volt. They reported improvements in all parkinsonian symptoms with bilateral GPi stimulation. Benefits were observed in bradykinesia, gait, speech and drug induced dyskinesias. Other groups<sup>30,31</sup> have also reported striking improvements in all major parkinsonian features with GPi stimulation, while another<sup>32</sup> has found it to be of lesser benefit. The clinical effects are dependent on which parts of the pallidum are stimulated and which stimulating parameters are used.<sup>33,34</sup> Recent functional imaging data<sup>20</sup> suggest that GPi stimulation improves parkinsonian features by activating supplementary motor cortical areas whose underactivity in PD is thought to underlie major clinical signs and symptoms. This finding suggests that pallidal stimulation blocks GPi overactivity to disinhibit the downstream thalamus and thalamocortical system. These preliminary results support the therapeutic effectiveness of GPi stimulation and indicate that this therapeutic modality warrants further study. Recent work shows that pallidotomy can be combined with contralateral pallidal DBS to provide clinical benefit with the advantage of the reversibility of DBS.<sup>35</sup>

### STN stimulation

Subthalamic nucleus (STN) stimulation represents an exciting new development in Parkinson's disease surgery. STN is glutamatergic and drives both GPi and the SNr, the two nuclei which constitute the collective output of the basal ganglia. It is therefore strategically situated to exert a powerful influence on motor function. Reducing STN activity would diminish the driving of



**Figure 2:** T1 weighted MRI images of patients with unilateral Vim DBS electrode (left), bilateral GPi electrodes (centre) and bilateral STN electrodes (right).



**Figure 3:** Percent improvement in parkinsonian features (UPDRS motor, akinesia, rigidity, tremor and gait/posture scores) with STN stimulators turned on in 6 PD patient in the “off” drug state studied in a double blind fashion six months after bilateral STN DBS implants. (Data from R Kumar, AE Lang and AM Lozano)

GPI and SNr thereby lessening the inhibition of thalamocortical projections and the motor cortical system. Such an intervention would thus be expected to facilitate movement.

Because the prospects of hemiballism are unacceptable, lesioning STN has so far not been routinely used in humans. In a pioneering report from Benabid and his colleagues,<sup>36</sup> three patients undergoing bilateral STN stimulation with implanted quadripolar electrodes showed striking improvements in all motor disabilities in Parkinson’s disease. In these patients evaluated using the UPDRS scale three months after surgery, activity of daily living scores improved by 58-88%, and motor scores by 42-84%. This has been recently confirmed in a larger series.<sup>37</sup> Our own results<sup>38</sup> in seven patients evaluated in double-blind fashion six months after bilateral STN DBS electrode insertion are shown in the figure below show a similar level of benefit. Stimulation parameters and drugs were adjusted to avoid dyskinesias, particularly those induced by stimulation.

The mechanism of action of STN stimulation is not known. The simplest hypothesis is that the stimulation reduces or inactivates STN excitatory glutamatergic projections which drive the inhibitory GPi and SNr. Whatever the mechanism, STN stimulation represents an important development in the understanding and treatment of movement disorders.

#### TRANSPLANTATION

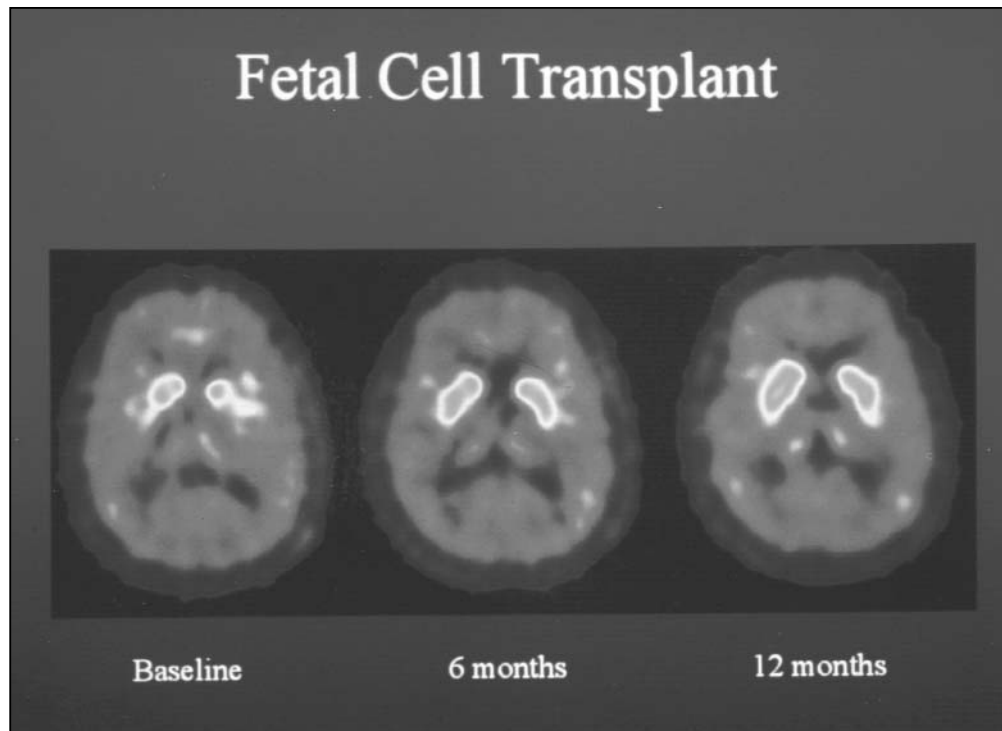
Medications and basal ganglia surgery can produce sympto-

matic improvement in PD but neither corrects the underlying pathology of the disease: dopamine deficiency due to loss of midbrain substantia nigra pars compacta neurons.<sup>39</sup> Transplantation therapy offers the possibility of replacing these lost neurons.<sup>40-41</sup> This review will focus on the clinical application of neural transplantation for PD. Clinical trials have utilized i) adrenal medulla,<sup>42-47</sup> ii) fetal mesencephalon,<sup>48-60</sup> and iii) xenografts<sup>61</sup> as a source of dopaminergic secretion.

#### Adrenal Medulla Grafts

The first clinical trial of transplantation for PD used autologous adrenal medulla.<sup>42</sup> Studies in rodents showed that motor behaviour caused by dopaminergic depletion could be reversed by adrenal medullary grafts.<sup>62</sup> Adrenal chromaffin cells are known to secrete dopamine (as a precursor to adrenaline).<sup>63,64</sup> Backlund et al.<sup>42</sup> therefore hoped to replace the reduced striatal dopamine in PD by direct implantation of dopamine secreting adrenal chromaffin cells. Autologous adrenal medullary grafts avoid the immune rejection and ethical considerations inherent in fetal mesencephalon transplants.

The first patient was treated in Lund, Sweden in 1982. An adrenalectomy was performed under general anaesthetic, the medulla was dissected out and then stereotactically implanted into his caudate. The motor improvements were modest and short lived.<sup>42</sup> Two additional patients also had little benefit.<sup>43</sup> Soon thereafter, two Mexican patients were reported to have dramatic effects following a similar operation.<sup>44</sup> Although this later trial



**Figure 4:** Fluoro-dopa PET scan of a PD patient with bilateral fetal mesencephalic transplants to the putamen.

was done without standard motor rating scales, it spurred a tremendous interest in adrenal medullary grafting. During the next two years, over 300 patients were transplanted in North America, with disappointing results. Modest improvements in motor scores were seen in 30% of patients but this was outweighed by the high morbidity and mortality of adrenalectomy in these patients.<sup>65</sup> As a result, clinical adrenal transplants have been abandoned in Canada, Europe and the United States. Basic research continues on co-transplanting growth factors to enhance adrenal tissue survival and function.<sup>66</sup>

#### Fetal Mesencephalon Grafts

A combination of factors led to human fetal mesencephalon clinical trials. First, fetal mesencephalon grafts produced better motor improvement than adrenal medullary grafts in rodent and primate models of PD.<sup>64</sup> Second, transplanting neurons offered the potential for synaptic communication and thus modulation between the graft and the host (chromaffin cells could act only as cellular mini-pump).<sup>67</sup> Third, the clinical trials using chromaffin cells were unsuccessful.<sup>65</sup>

Early studies of fetal mesencephalon transplants from China, Mexico and Sweden showed promising results. Following technical modifications designed to improve transplant survival, Lindvall reported reduced rigidity and off time in two patients.<sup>51</sup> Positron emission tomography (PET) at the University of British Columbia showed increased flurodopa uptake (a sign of graft survival and function) eight months post-transplant in these patients. Subsequent studies confirmed these promising results.<sup>52-54</sup> The impact of the Yale study, however, was lessened by a post mortem diagnosis of striatonigral degeneration in one of their four patients.<sup>52</sup> Some studies with poor outcomes were criticized for using techniques uncondusive to transplant sur-

vival.<sup>55</sup> The most impressive data came from Lund where two patients with a parkinsonism secondary to poisoning from 1-methyl-4-phenyl-1,2,3,6-tetrahydropyridine (MPTP) were dramatically improved (one coming off all medications) with PET data showing survival of the graft at two years.<sup>54</sup>

Three important concepts developed from these studies. First, a unified rating scale was needed to compare reports from different institutions.<sup>68</sup> Second, PET imaging was crucial to demonstrate graft survival and function *in vivo* (an example of the PET imaging is shown in Figure 4). Third, more work was needed to improve fetal dopaminergic neuronal survival following transplantation. Animal studies continued to expand the knowledge of fetal dopaminergic neuronal survival by determining the ideal age,<sup>69</sup> techniques<sup>70</sup> and whether immunosuppression<sup>71</sup> is required. The latest studies have been impressive.<sup>36-40</sup> The Tampa group has reported histologic proof of graft survival eighteen months post transplant in a patient who died following an unrelated orthopaedic procedure.<sup>72</sup> Over 200,000 dopaminergic neurons were counted innervating the host striatum in an organotypic pattern. Ultrastructural studies demonstrated graft-host synaptic connections. This work provides proof of concept that fetal mesencephalon grafts can survive in the host striatum and improve the motor dysfunction of PD. Two randomized prospective NIH-funded trials are underway.

Despite the successful results of fetal transplantation in PD, few workers in the field believe it will be routinely used to treat their patients. The two problems facing this therapy are i) insufficient tissue (the Tampa group uses up to eight fetuses per patient) and ii) the procedural difficulty (centres must consent for infectious disease screening, sterile abortions, rapid fetal dissection and neurosurgical implantation). The field will undoubtedly proceed to more wide-spread clinical use once an alternative source

of human fetal tissue is found. Basic scientists are testing i) genetically engineered cells,<sup>73,74</sup> ii) encapsulated cells,<sup>75,76</sup> iii) gene therapy,<sup>77-80</sup> and iv) xenografts.<sup>81,82</sup> Genetically modified cells (fibroblasts with the genes for dopamine production) have reversed motor behaviours in animal models of PD but have been hindered by long-term downregulation of the genes. Encapsulated cells (dopamine secreting tumours or cell lines wrapped in polymers with size selective pores, which permit the diffusion of small molecules but exclude host antibodies or T-cells) can bypass the immune system but will not allow synaptic communication and may not provide long-term survival. The direct inoculation of genes into the striatum may allow recruitment of non-dopaminergic neurons to produce dopamine. Finally, xenografts (tissue from different species) have shown promising results in animal models. One clinical trial using fetal pig mesencephalon has completed transplants in twelve PD patients and is awaiting follow-up data.

#### GROWTH FACTOR THERAPY

Neurotrophic factors are secreted by target tissues and guide the development, guidance and maintenance of the neurons which innervate them.<sup>83</sup> The use of a dopaminergic neurotrophic factor could have three beneficial effects in PD. First, it may reduce the loss of dopaminergic neurons and thus slow the progression of the disease. Second, it may stimulate sprouting of terminals which could store more dopamine, better buffering the striatal dopamine level, and thus reduce "on-off" phenomena. Third, it may stimulate the remaining dopaminergic neurons to increase their dopamine production potentially making up for their reduced number.

Glial cell line-derived neurotrophic factor (GDNF) has been shown to increase dopaminergic neuronal survival and dopamine uptake *in vitro*.<sup>84</sup> Studies *in vivo* have demonstrated that GDNF can i) increase tyrosine hydroxylase expression and neurite density in the substantia nigra of rodents,<sup>85</sup> ii) prevent neuronal loss after nigral toxin injection in rodents,<sup>86</sup> and iii) improve motor function in primates made Parkinsonian by exposure to MPTP.<sup>87</sup> These pre-clinical studies have led to on going randomized, double-blind, placebo-controlled trial of GDNF intraventricular infusion in PD.

#### CONCLUSION

We have seen surgical treatments playing an important role in the treatment of PD in the 1950's and 1960's only to virtually disappear with the advent L-Dopa in the late 1960s. Scientific advances are now driving the renaissance in surgical therapies in the treatment of patients who continue to be disabled despite the best available medical therapies. Some of the procedures currently in use such as pallidotomy are being rediscovered while others like transplantation and stimulation are novel and exciting developments. There are many new avenues to follow, each of which will increase our understanding and the effectiveness with which PD can be treated.

#### ACKNOWLEDGEMENT

The authors would like to thank Drs AE Lang, WD Hutchison and JO Dostrovsky for ongoing collaboration and review of the manuscript. AML is supported by a Medical Research Council of Canada Clinician-Scientist Award. This work is supported by the Parkinson's Foundation of Canada.

#### REFERENCES

1. Rajput AH. Frequency and cause of Parkinson's disease. *Can J Neurol Sci* 1992; 19(1 Suppl): 103-107.
2. Lilienfeld DE, Chan E, Ehland J, et al. Two decades of increasing mortality from Parkinson's disease among the U.S. elderly. *Arch Neurol* 1990; 47(7): 731-734.
3. Tasker, RR. Thalamotomy. *Neurosurg Clin North Am* 1990; 1: 841-864.
4. Laitinen LV, Bergenheim AT, Hariz MI. Leksell's posteroventral pallidotomy in the treatment of Parkinson's disease. *J Neurosurg* 1992; 76: 53-61.
5. Lozano AM, Lang AE, Galvez-Jimenez N, et al. Effect of GPi pallidotomy on motor function in Parkinson's disease. *Lancet* 1995; 346: 1383-1387.
6. Kishore A, Turnbull IM, Snow BJ, et al. Efficacy, stability and predictors of outcome of pallidotomy for Parkinson's disease. Six-month follow-up with additional 1-year observations. *Brain* 1997; 120: 729-737.
7. Kopyov O, Jacques D, Duma C, et al. Microelectrode-guided posteroventral medial radiofrequency pallidotomy for Parkinson's disease. *J Neurosurg* 1997; 87: 52-59.
8. Krauss JK, Desaloms JM, Lai EC, et al. Microelectrode-guided posteroventral pallidotomy for treatment of Parkinson's disease: postoperative magnetic resonance imaging analysis. *J Neurosurg* 1997; 87: 358-367.
9. Uitti RJ, Wharen REJ, Turk MF, et al. Unilateral pallidotomy for Parkinson's disease: comparison of outcome in younger versus elderly patients. *Neurology* 1997; 49: 1072-1077.
10. Samuel M, Caputo E, Brooks DJ, et al. A study of medical pallidotomy for Parkinson's disease: clinical outcome, MRI location and complications. *Brain* 1998; 121: 59-75.
11. Baron MS, Vitek JL, Bakay RA, et al. Treatment of advanced Parkinson's disease by posterior GPi pallidotomy: 1-year results of a pilot study. *Ann Neurol* 1996; 40: 355-366.
12. Lang AE, Lozano AM, Montgomery E, et al. Posteroventral medial pallidotomy in advanced Parkinson's disease. *N Engl J Med* 1997; 337: 1036-1042.
13. Fazzini E, Dogali M, Sterio D, Eidelberg D, Beric A. Stereotactic pallidotomy for Parkinson's disease: a long-term follow-up of unilateral pallidotomy. *Neurology* 1997; 48: 1273-1277.
14. Filion M, Tremblay L. Abnormal spontaneous activity of globus pallidus neurons in monkeys with MPTP-induced parkinsonism. *Brain Res* 1991; 547: 142-151.
15. Miller WC, DeLong MR. Altered tonic activity of neurons in the globus pallidus and subthalamic nucleus in the primate MPTP model of parkinsonism. In: Carpenter MB, Jayaraman A, ed. *The Basal Ganglia 2*. New York: Plenum Press, 1987: 415-427.
16. DeLong MR. Primate models of movement disorders of basal ganglia origin. *Trends Neurosci* 1990; 13: 281-285.
17. Albin RL, Young AB, Penney JB. The functional anatomy of basal ganglia disorders. *Trends Neurosci* 1989; 12: 366-375.
18. Grafton ST, Waters C, Sutton J, Lew MF, Couldwell W. Pallidotomy increases activity of motor association cortex in Parkinson's disease: a positron emission tomographic study. *Ann Neurol* 1995; 37: 776-783.
19. Samuel M, Ceballos-Baumann AO, Turjanski N, et al. Pallidotomy in Parkinson's disease increases supplementary motor area and prefrontal activation during performance of volitional movements an H2(15)O PET study. *Brain* 1997; 120: 1301-1313.
20. Davis KD, Taub E, Houle S, Lang AE, Dostrovsky JO, Tasker RR, et al. Globus pallidus stimulation activates the cortical motor system during alleviation of parkinsonian symptoms. *Nature Medicine* 1997; 3: 671-674.
21. Svännilsson E, Torvik A, Lomo R, Leksell L. Treatment of Parkinsonism by stereotactic thermolesions in the pallidal region. *Acta Psychiatr Neurol Scand* 1960; 35: 358-377.
22. Langston JW, Widner H, Goetz CG, et al. Core assessment program for intracerebral transplantations (CAPIT). *Mov Disord* 1992; 7: 2-13.
23. Dogali M, Fazzini E, Kolodny E, et al. Stereotactic ventral pallidotomy for Parkinson's disease. *Neurology* 1995; 45: 753-761.

24. Biouesse V, Newman NJ, Carroll C, et al. Visual fields in patients with posterior GPi pallidotomy. *Neurology* 1998; 50: 258-265.
25. Sutton JP, Couldwell W, Lew MF, et al. Ventroposterior medial pallidotomy in patients with advanced Parkinson's disease. *Neurosurgery* 1995; 36: 1112-1116; discussion 1116-1117.
26. Guiot G, Hardy J, Albe-Fessard D. Délimitation précise des structures sous-corticales et identification de noyaux thalamiques chez l'homme par l'électrophysiologie stéréotaxique. *Neurochirurgia (Stutt)* 1962; 51: 1-18.
27. Benabid AL, Pollak P, Gao DM, et al. Chronic electrical stimulation of the ventralis intermedius nucleus of the thalamus as a treatment of movement disorders. *J Neurosurg* 1996; 84: 203-214.
28. Koller W, Pahwa R, Busenbark K, et al. High-frequency unilateral thalamic stimulation in the treatment of essential and parkinsonian tremor. *Ann Neurol* 1997; 42: 292-299.
29. Siegfried J, Lippitz B. Bilateral chronic electrostimulation of ventroposterolateral pallidum: a new therapeutic approach for alleviating all parkinsonian symptoms. *Neurosurgery* 1996; 35: 1126-1130.
30. Volkmann J, Sturm V, Weiss P, et al. Bilateral high-frequency stimulation of the internal globus pallidus in advanced Parkinson's disease. *Ann Neurol* 1998; 44: 953-61.
31. Gross C, Rougier A, Guehl D, et al. High-frequency stimulation of the globus pallidus internalis in Parkinson's disease: a study of seven cases. *J Neurosurg* 1997; 87(4): 491-498.
32. Tronnier VM, Fogel W, Kronenbueger M, Steinvoth S. Pallidal stimulation: an alternative to pallidotomy? *J Neurosurg* 1997; 87(5): 700-705.
33. Bejjani B, Damier P, Arnulf I, et al. Pallidal stimulation for Parkinson's disease. Two targets? *Neurology* 1997; 49(6): 1564-1569.
34. Krack P, Pollak P, Limousin P, et al. Opposite motor effects of pallidal stimulation in Parkinson's disease. *Ann Neurol* 1998; 43(2): 180-192.
35. Galvez-Jimenex, N, Lozano A, Tasker R, et al. Pallidal stimulation in Parkinson's disease patients with a prior unilateral pallidotomy. *Can J Neurol Sci* 1998; 25: 300-305.
36. Limousin P, Pollak P, Benazzouz A, et al. Effect of parkinsonian signs and symptoms of bilateral subthalamic nucleus stimulation. *Lancet* 1995; 345: 91-95.
37. Limousin P, Krack P, Pollak P, et al. Electrical stimulation of the subthalamic nucleus in advanced Parkinson's disease. *N Engl J Med* 1998; 339: 1105-1111.
38. Kumar R, Lozano AM, Kim YJ, et al. Double-blind evaluation of subthalamic nucleus deep brain stimulation in advanced Parkinson's disease. *Neurology* 1998; 51: 850-855.
39. Kish, S.J., Shannak, K, Hornykiewicz O. Uneven pattern of dopamine loss in the striatum of patients with idiopathic Parkinson's disease. *N Engl J Med* 1988; 318: 876-880.
40. Olanow CW, Freeman TB, Kordower JH. Neural transplantation as a therapy for Parkinson's disease. *Adv Neurol* 1997; 74: 249-269.
41. Mehta V, Spears J, Mendez I. Neural transplantation in Parkinson's Disease. *Can J Neurol Sci* 1997; 24(4): 292-301.
42. Backlund EO, Granberg PO, Hamberger B, et al. Transplantation of adrenal medullary tissue to striatum in parkinsonism. First clinical trials. *J. Neurosurg* 1985; 62: 169-173.
43. Lindvall O, Backlund EO, Farde L, et al. Transplantation in Parkinson's disease: two cases of adrenal medullary grafts to putamen. *Ann Neurol* 1987; 22: 457-468.
44. Madrazo I, Drucker-Colin R, Diaz V, et al. Open microsurgical autograft of adrenal medulla to the right caudate nucleus in Parkinson's disease: a report of two cases. *N Engl J Med* 1987; 316: 831-834.
45. Allen GS, Burns RS, Tulipan NB, et al. Adrenal medullary transplantation to the caudate nucleus in Parkinson's disease. Initial results in 18 patients. *Arch Neurol* 1989; 46: 487-491.
46. Bakay RAE. Preliminary report on adrenal medullary grafting from the American Association of Neurological Surgeons GRAFT project. *Restorative Neurol Neurosci* 1989; 1: 158.
47. Kelly PJ, Ahlskog JE, Van Heerden JA, et al. Adrenal medullary autograft transplantation into the striatum of Parkinson's disease. *Mayo Clin Proc* 1989; 64: 282-290.
48. Jiang N, Jiang C, Tang A, et al. Human foetal brain transplant trials in the treatment of Parkinsonism. *Acta Acad Medicin Shanghai* 1987; 14(1): 77.
49. Madrazo I, Leon V, Torres C, et al. Transplantation of fetal substantia nigra and adrenal medulla to the caudate nucleus in two patients with Parkinson's disease. *N Engl J Med* 1988; 318: 51.
50. Lindvall O, Rehnström S, Gustavii B, et al. Fetal dopamine-rich mesencephalon grafts in Parkinson's disease. *Lancet* 1988; 2: 1483-1484.
51. Lindvall O, Brundin P, Widner H, et al. Grafts of fetal dopamine neurons survive and improve motor function in Parkinson's disease. *Science* 1990; 247: 547.
52. Spencer DD, Robins RJ, Naftolin F, et al. Unilateral transplantation of human fetal mesencephalic tissue into the caudate nucleus of patients with Parkinson's disease. *N Engl J Med* 1992; 327: 1541-1548.
53. Freed CR, Breeze RE, Rosenberg NL, et al. Survival of implanted fetal dopamine cells and neurologic improvement 12 to 46 months after transplantation for Parkinson's disease. *N Engl J Med* 1992; 327: 1549-1555.
54. Widner H, Tetud J, Rehnström S, et al. Bilateral fetal mesencephalic grafting in two patients with Parkinsonism induced by 1-methyl-4-phenyl-1,2,3,6-tetrahydropyridine (MPTP). *N Engl J Med* 1992; 327: 1556-1563.
55. Hitchcock ER, Kenny BG, Clough CG, et al. Stereotactic implantation of foetal mesencephalon (STIM): the UK experience. *In: Dunnett SB, Richards S-J, eds. Neural Transplantation: From Molecular Basis to Clinical Applications. Progress in Brain Research. Amsterdam: Elsevier, 1990: 723-728.*
56. Molina H, Quinones R, Alvarez L, et al. Transplantation of human fetal mesencephalic tissue in caudate nucleus as treatment for Parkinson's disease: the Cuban experience. *In: Lindvall O, Bjorklund A, Widner H, eds. Intracerebral Transplantation in Movement Disorders. Restorative Neurology, Vol. 4, Amsterdam: Elsevier, 1991: 99-110.*
57. Peschanski M, Defer G, Guyen JP, et al. Bilateral motor improvement and alteration of L-dopa effect in two patients with Parkinson's disease following intrastriatal transplantation of foetal ventral mesencephalon. *Brain* 1994; 117: 487-499.
58. Lopez-Lozano JJ, Bravo G, Brera B, et al. Long-term follow-up in 10 Parkinson's disease patients subjected to fetal brain grafting into a cavity in the caudate nucleus: the clinica Puerta de Hierro experience. *Transplant Pro* 1995; 27(1): 1395-1400.
59. Freeman TB, Olanow CW, Hauser RA, et al. Bilateral fetal nigral transplantation into the postcommissural putamen in Parkinson's disease. *Ann Neurol* 1995; 38(3): 379-388.
60. Freed CR, Breeze RE, Leehey MA, et al. Eight years experience with fetal neurotransplantation in patients with advanced Parkinson's disease. *Soc Neurosci Abst* 1996; 22(2): 481.3.
61. Savel'ev SV. Outlook for the use of nerve tissue xenotransplantation in neurosurgery. *Arkhiv Patologii.* 1995; 57(2): 1118.
62. Freed WJ, Morihisa JM, Spoor E, et al. Transplanted adrenal chromaffin cells in rat brain reduce lesion induced rotational behaviour. *Nature* 1981; 292: 351-352.
63. Wurtman RJ, Pohorecky LA, Baliga BS. Adrenocortical control of the biosynthesis of epinephrine and proteins in the adrenal medulla. *Pharmacol Rev* 1972; 24: 411-426.
64. Brown VJ, Dunnett SB. Comparison of adrenal and foetal nigral grafts on drug-induced rotation in rats with 6-OHDA lesions. *Exp Brain Res* 1989; 78: 214-218.
65. Goetz CG, Stebbins GT, Klawans HL, et al. United Parkinson Foundation Neural Transplantation Registry on adrenal medullary transplants: presurgical, and 1 and 2 year follow-up. *Neurology* 1991; 41: 1719-1722.
66. Date I, Shingo T, Ohmoto T, et al. Longterm enhanced chromaffin cell survival and behavioral recovery in hemiparkinsonian rats with cogenerated polymerencapsulated human NGFsecreting cells. *Neurology* 1997; 147(1): 1017.
67. Lund R, Hauscha S. Transplanted neural tissue develops connections with host rat brain. *Science* 1976; 193: 582-584.
68. Kordower JH, Freeman TB, Chen EY, Mufson EJ, Sanberg PR, Hauser RA, Snow B and Olanow CW. Fetal nigral grafts survive and mediate clinical benefit in a patient with Parkinson's disease. *Mov Disord* 1998; 13: 383-393.

69. Freeman TB, Sanberg PR, Navelt GM, et al. Influence of donor age on the survival of solid and suspension intraparenchymal human embryonic micrografts. *Cell Transplant* 1995; 4: 141-145.
70. Nikkhah G, Cunningham MG, Jodicke A, et al. Improved graft survival and striatal reinnervation by microtransplantation of fetal nigral cell suspensions in the rat Parkinson's model. *Brain Res* 1994; 633: 133-143.
71. Sloan DJ, Wood MJ, Charlton HM. The immune response to intracerebral neural grafts. *Trends Neurosci* 1991; 14(8): 341-346.
72. Kordower JH, Freeman TB, Snow BJ, et al. Neuropathological evidence of graft survival and striatal reinnervation after the transplantation of fetal mesencephalic tissue in a patient with Parkinson's disease. *N Engl J Med* 1995; 332: 1118-1124.
73. Levivier M, Przedborski S, Bencsics C, et al. Intra-striatal implantation of fibroblasts genetically engineered to produce brain-derived neurotrophic factor prevents degeneration of dopaminergic neurons in a rat model of Parkinson's disease. *J Neurosci* 1995; 15(12): 7810-7820.
74. Tornatore C, Baker-Cairns B, Yadid G, et al. Expression of tyrosine hydroxylase in an immortalized human fetal astrocyte cell line; *in vitro* characterization and engraftment into the rodent striatum. *Cell Transplant* 1996; 5(2): 145-163.
75. Maysinger D, Piccardo P, Cuello AC. Microencapsulation and the grafting of genetically transformed cells as therapeutic strategies to rescue degenerating neurons of the CNS. *Rev Neurosci* 1995; 6(1): 1533.
76. Date I, Miyoshi Y, Ono T, et al. Preliminary report of polymer-encapsulated dopamine-secreting cell grafting into the brain. *Cell Transplant* 1996; 5; (5 Suppl 1): S1719.
77. Whittemore SR, Eaton MJ, Onifer SM. Gene therapy and the use of stem cells for central nervous system regeneration. *Adv Neurol* 1997; 72: 113-119.
78. Freese A, Stern M, Kaplitt MG, et al. Prospects for gene therapy in Parkinson's disease. *Mov Disord* 1996; 11(5): 469-488.
79. Freeman TB. From transplants to gene therapy for Parkinson's disease. *Exp Neurol* 1997; 144(1): 47-50.
80. Horellou P, Mallet J. Gene therapy for Parkinson's disease. *Mol Neurobiol* 1997; 15(2): 241-256.
81. Galpern WR, Burns LH, Deacon TW, et al. Xenotransplantation of porcine fetal ventral mesencephalon in a rat model of Parkinson's disease: functional recovery and graft morphology. *Exp Neurol* 1996; 140(1): 113.
82. Dinsmore JH, Pakzaban P, Deacon TW, et al. Survival of transplanted porcine neural cells treated with F(ab')<sub>2</sub> antibody fragments directed against donor MHC class in a rodent model. *Transplantation Proc* 1996; 28(2): 817-818.
83. Oppenheim RW. The neurotrophic theory and naturally occurring motoneuron death. *Trends Neurosci* 1989; 12: 252-255.
84. Lin LH, Doherty DH, Lile JD, et al. GDNF: a glial cell line-derived neurotrophic factor for midbrain dopaminergic neurons. *Science* 1993; 260: 1130-1132.
85. Hudson J, Granholm AC, Gerhardt GA, et al. Glial cell line-derived neurotrophic factor augments midbrain dopaminergic circuits *in vivo*. *Brain Res Bulletin* 1995; 36(5): 425-432.
86. Shults CW, Kimber T, Martin D. Intra-striatal injection of GDNF attenuates the effects of 6-hydroxydopamine. *Neuroreport* 1996; 7(2): 627-631.
87. Gash DM, Zhang Z, Ovadia A, et al. Functional recovery in parkinsonian monkeys treated with GDNF. *Nature* 1996; 380(6571): 252-255.