

EXPERIMENTAL INVESTIGATIONS ON FRAMBOESIA TROPICA (YAWS).

By ALDO CASTELLANI, M.D.,
Director of the Clinic for Tropical Diseases, Colombo, Ceylon.

(Plates XV and XVI and One Figure.)

IN this paper I propose to record briefly the results of my investigations on the inoculation of framboesia in the lower animals and other experimental researches on the disease.

Inoculation of Yaws in Monkeys.

My first experiments, made at the beginning of 1905, on a "purple-faced monkey" (*Semnopithecus cephalopterus*) were negative. In February and March of 1906 I inoculated three monkeys of the genus *Macacus*, with positive results in one case. The monkey which was successfully inoculated with yaws was later inoculated with syphilis with positive results. In the meantime Neisser, Baerman and Halberstädter (1906) published a report on their results in the inoculation of yaws in monkeys, coming to the conclusion that monkeys of a high as well as those of a low type are susceptible to infection with yaws; and that monkeys immunized against syphilis do not become immune against yaws. I have continued the investigation on numerous monkeys of the genus *Macacus* and *Semnopithecus*. In both genera the positive results are fairly numerous, provided the scarifications on which the yaws material is inoculated are made as deep as possible. I quote two of the experiments which gave positive results.

Monkey No. 4 (Macacus pileatus). 10. XI. 06. The scrapings taken from a non-ulcerated yaws papule were thoroughly rubbed into the scarified spots over the left eyebrow. The slight local inflammatory reaction caused by the scarification subsided in three days. Nineteen days after the inoculation a very small flattened

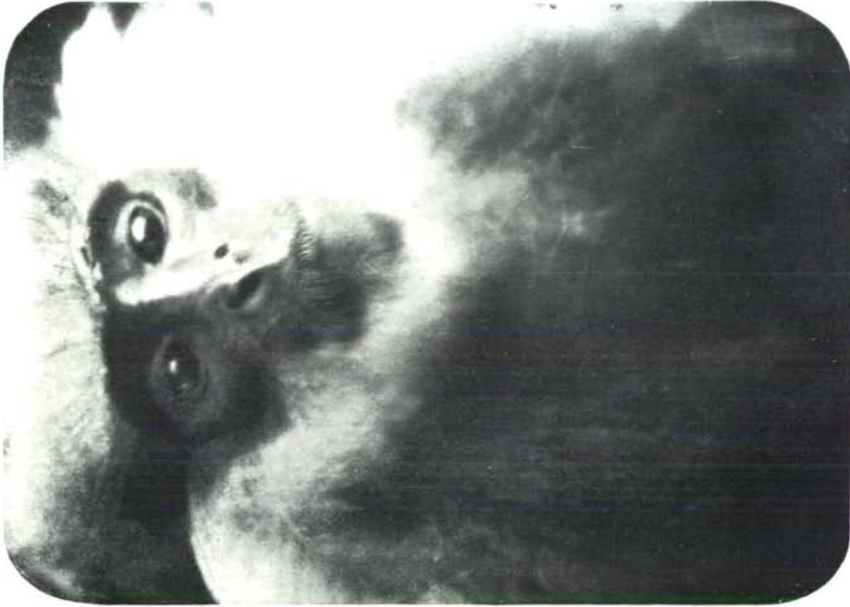

Fig. 2.

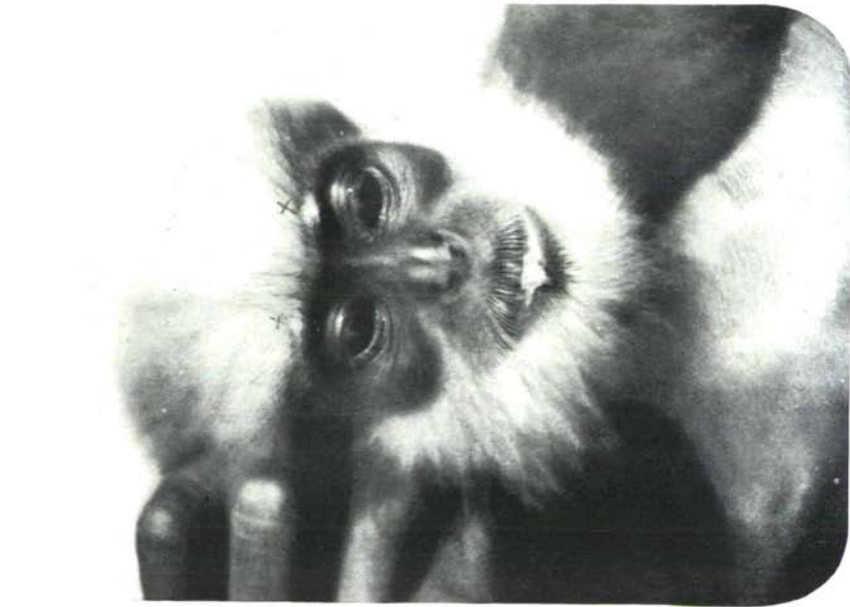

Fig. 1.

Figs. 1 & 2. Experimental Yaws. Framboetic lesion at the place of inoculation (eyebrows) in monkeys.

papule, surrounded by an infiltrated zone, appeared at the seat of inoculation. The lesion soon became enlarged and moist, the secretion drying into a thick crust. On removing this crust a granulating raw surface was seen. Two months later, the first lesion being still present, four more papules appeared, two on the lower part of the forehead, close to the primary lesion, and two just over the upper lip. One of these lesions disappeared after a few days; the others became moist and a yellowish crust formed on each of them. All of these papules remained small and disappeared after three months, leaving tiny dark marks. The eruption was evidently very irritable, as the monkey was continually scratching. It is possible that the papules observed two months after the first lesion appeared, may represent results of auto-inoculation by scratching rather than a true secondary eruption.

Monkey No. 17 (Semnopithecus priamus). 15. x. 06. Scrapings taken from a non-ulcerated papule of a yaws patient were well rubbed into deep scarifications over the left eyebrow. Forty-five days later three slightly elevated spots appeared which soon fused together into an infiltrated mass, covered by a thick crust; the lesion increased to the size of a sixpenny piece. No other lesions appeared. The lesion is still present and of the same size (31. I. 1907). It was examined for the *Spirochaeta pertenuis* on three different occasions, twice with positive results.

Altogether eight monkeys of the genus *Macacus* and 11 of the genus *Semnopithecus* have been inoculated with scrapings taken from the eruptive lesions of yaws patients: the inoculation was successful in five monkeys of the first genus and nine of the second. The incubation period has varied from a minimum of 19 days to a maximum of 92. The appearance of the lesion developing at the seat of inoculation was practically the same in all cases, viz. an infiltrated spot slowly increasing in size and soon becoming moist, the secretion drying into a thick crust. When the crust was removed a raw granulating red surface was seen. With the exception of three cases the eruption remained localized at the point of inoculation and no other eruption appeared. Of the three cases in which eruption developed some time after the primary lesion, in one, as I have already mentioned (monkey No. 4), two small papules appeared on the lower part of the forehead, in the vicinity of the primary lesion, and two others above the upper lip. Of the other two monkeys, in one, a rather large moist papule appeared on the lower lip three months after the primary sore had developed; in the other, three small papules, which soon broke and became covered with a crust, developed on the lower part of the forehead, close to the primary lesion, two and a half months after the first lesion had appeared. See Plate XV.

Inoculation of Monkeys with the Blood of the General Circulation from a Yaws Patient.

About 5 c.c. of blood were withdrawn (19. ix. 1906) aseptically from a vein at the bend of the elbow of a patient suffering from a typical yaws eruption on the legs, back and face, but not on the arms; the needle, therefore, could be inserted through perfectly normal skin without touching any yaws lesion. One c.c. of the blood was well rubbed into deeply scarified spots on the right eyebrow of a *Macacus*. Thirty-three days later, a small deeply raised, brownish papule appeared. Before the papule became moist a scraping was taken and stained with Leishman's method in the manner I have described elsewhere (26. xi. 1905). Many *Sp. pertenuis* were present. The papule slowly enlarged and became covered with a crust. The lesion disappeared after three months; no other lesions developed.

This experiment shows that:

1. Monkeys can be successfully inoculated with the blood of a yaws patient.
2. The *Spirochaeta pertenuis* is, at least temporarily, present in the blood of the general circulation, though so far I have not been able to detect it microscopically.

Inoculation of Monkeys with the Splenic Blood derived from a Case of Yaws.

19. ix. 1906. About 1 c.c. of splenic blood was obtained by puncturing the spleen of a patient affected with typical yaws; film preparations showed very rare *Sp. pertenuis*. The splenic blood was inoculated into two *Mac. pileatus* in the usual manner.

The result was positive in one monkey, a framboetic papule developing after an incubation period of 36 days; the result was negative in the other monkey.

Inoculation of Monkeys with the Cerebro-spinal Fluid of Yaws Patients.

15. ix. 1906. Four monkeys (2 *Mac. pileatus* and 2 *Semn. priamus*) were inoculated with the cerebro-spinal fluid derived from three different patients affected with yaws. The cerebro-spinal fluid was in all the cases perfectly limpid; on centrifugalization it did not show any sediment and *Sp. pertenuis* could not be found, though it was present in the skin lesions of the same patients.

Up to date (15. ii. 1907), four and a half months after inoculation, the result has been negative.

Inoculation of Filtered Yaws Virus.

14. IX. 06. The scrapings were taken from non-ulcerated human papules containing *Sp. pertenuis* in exceptional abundance. No other germs could be detected microscopically or by cultural methods. The scrapings were mixed and well triturated with normal saline solution. Preparations made from this mixture showed many *Sp. pertenuis*. Part of the mixture was then inoculated in the usual manner into two *Mac. pileatus*. The rest of the mixture was filtered through a Berkefeld filter (12 A); preparations made from the filtrate did not show the presence of the spirochaete. The filtrate was inoculated into three *Mac. pileatus* and one *Semn. priamus*. Both monkeys inoculated with the unfiltered material developed—one after 25 days, the other after 40 days—framboetic papules at the seat of inoculation, covered by a thick crust. Films made from the scrapings of the framboetic lesions of both monkeys contained *Sp. pertenuis*. The four monkeys inoculated with filtered material have not shown any lesions either at the place of inoculation or in any other region of the body, though six months have elapsed since the inoculation.

This experiment tends to prove that *Sp. pertenuis* is the true cause of yaws, for when it is removed from yaws material, the latter is no longer infective.

Inoculation of Syphilis in Monkeys previously Inoculated with Yaws.

Monkey No. 4 (Mac. pileatus) was successfully inoculated with yaws in February, 1906. On 16. VI. 1906, scrapings from a primary sore of a syphilitic man were well rubbed into scarified spots on the prepuce of the monkey's penis. On the 26th day after inoculation a small vesicle surrounded by a reddish halo appeared. The vesicle burst, leaving an erosion surrounded by infiltrated tissue. The glands of both groins became enlarged and hard, and could be easily felt. No secondary eruption appeared, but, as shown by Metchnikoff and Roux, this is almost always the case when experimenting with monkeys of a low type.

Monkey No. 11 (Mac. cynomolgus), 21. VIII. 06. Inoculated with yaws material on the left eyebrow; a framboetic papule developed on 22. IX. 06. Inoculated over the right eyebrow with syphilitic virus taken from a primary human sore on 30. XI. 1906. After 42 days a brownish papule developed surrounded by an infiltrated zone.

The monkey still presents (15. II. 1907) the framboetic lesion as well as the syphilitic sore; no secondary eruption has appeared.

Simultaneous Inoculation of Yaws and Syphilis.

Monkey No. 27 (Mac. pileatus) 10. IX. 06. Inoculation (1) with human yaws virus taken from a non-ulcerated papule on the left eyebrow, and (2) human syphilitic virus on the right eyebrow. The syphilitic material was taken from a primary human sore. After 32 days the left eyebrow, inoculated with yaws, showed three small flattened papules, which fused together into an elevated infiltrated mass

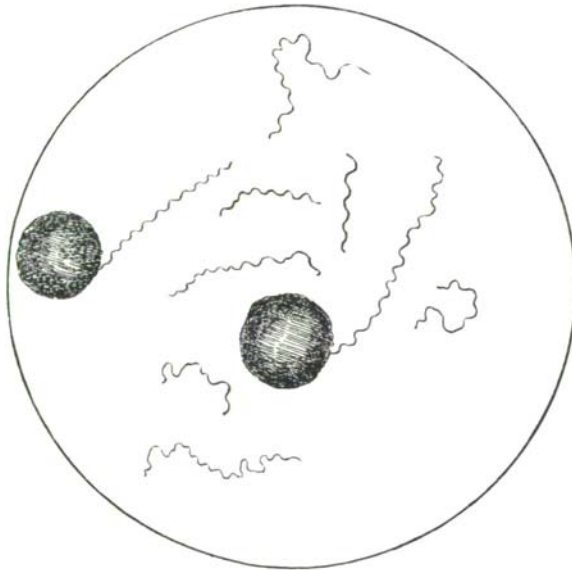
the size of a pea, covered by a thick crust. The right eyebrow, inoculated with syphilitic material, 39 days after inoculation, presented a tiny brown papule, which soon broke and became covered with a slight crust.

As regards the appearance of the yaws and syphilitic lesions, the yaws lesion was larger, more elevated and covered by a much thicker crust. The syphilitic lesion disappeared after two months, while the framboetic lesion is still present (15. II. 1907).

Transmission of Yaws from Monkey to Monkey.

Monkey No. 21 (Mac. pileatus) was inoculated on the left eyebrow with the virus of human yaws taken (19. IX. 06) from a non-ulcerated papule. From the infiltrated spot, which appeared 40 days later and which contained *Sp. pertenuis*, a scraping was taken and inoculated (22. XI. 06) into three *Mac. pileatus* and four *Semn. priamus*.

Of the three monkeys of the same species as No. 21, two gave positive results, the incubation period being 31 days in one case and 42 in the other. Of the four monkeys of a different species to No. 21, one only gave a positive result, after an incubation period of 67 days.



S. pertenuis. Preparation taken from a monkey inoculated with Framboesia.

Incidence of the Sp. pertenuis¹ in Monkeys Inoculated with Yaws, in comparison with the incidence of the Sp. pertenuis in Man suffering from Yaws.

The results of the investigation are collected in the following two tables.

TABLE I.

Incidence of the Spirochaeta pertenuis in monkeys inoculated with yaws.

Material investigated	No. of monkeys examined	No. of monkeys in which positive results were obtained
Primary lesion at the seat of inoculation ...	16	15
Framboetic papules which appeared some time after the primary lesion ...	3	2
Spleen juice ...	4	3
Bone marrow ...	4	1
Blood, general circulation ...	15	0
Smears from liver ...	4	0
Lymphatic glands ...	6	3
Brain substance ...	4	0
Cerebro-spinal fluid ...	4	0

TABLE II.

Incidence of the Spirochaeta pertenuis in yaws patients.

Material investigated	No. of cases examined	No. of cases in which positive results were obtained
Primary lesion ...	6	6
Unbroken papules of the general eruption ...	76	73
Ulcerated papules of the general eruption ...	76	52
Blood of the general circulation ...	20	0
Spleen blood ...	5	3
Cerebro-spinal fluid ...	6	0
Lymphatic glands ...	11	6

Comparing Table I with Table II, it will be seen that the incidence of *Sp. pertenuis* is practically constant in the eruptive lesions both in man and in inoculated monkeys. In the monkeys I have experimented with, the eruption does not become general, as in man; notwithstanding this we must admit that in monkeys also we have to do with a generalized

¹ This spirochaete was found by me in a case of yaws in February 1905, when I considered it to be a *Spirillum*. The discovery by Schaudinn of a spirochaete in syphilis, published soon afterwards, induced me to work at the subject in a systematic manner. The yaws spirochaete was first described by me (17. vi. 1905) under the name of *Spirochaeta pertenuis*. Later, (16. xi. 1905), I suggested the name of *Sp. pallidula*, on account of its resemblance to the spirochaete found in syphilis. According to the laws of nomenclature, however, the correct name is *Sp. pertenuis*.

infection, as proved by the presence of *Sp. pertenuis* in the spleen and lymphatic glands.

Microscopic Examination of the Lesions in Experimental Yaws.

Monkey No. 4 (Mac. pileatus). In this monkey, 19 days after inoculation, as already described, a small infiltrated spot appeared at the point of inoculation over the left eyebrow. The lesion became moist, the secretion drying into a thick crust and attaining the size of a sixpenny piece in about two weeks. Two months later, the first lesion being still present, of the same size and with the same characters, four more papules appeared; two close to the first lesion and two just above the upper lip. These papules remained always of small size and disappeared within three months. It is possible that these four papules were due to auto-inoculation by scratching; it cannot be excluded, however, that they might represent a partial secondary eruption, comparable to the general secondary eruption which appears in man; it must be remembered that though the skin lesions in experimental yaws—with the monkeys I have used—are generally localized at the point of inoculation, the infection is general, as clearly proved by the presence of the *Sp. pertenuis* in the spleen of the animals.

On 1. vi. 1906 the crust from the primary lesion was removed; from the raw, elevated, granulating surface, a piece of tissue was cut, divided into small portions and fixed in different ways (alcohol, sublimate, etc.); then imbedded in paraffin. Sections were stained by various methods (Pappenheim's, etc.). The two papules which appeared above the upper lip were also removed and investigated by the same methods. The results of the histological examination are briefly the following:—

I. *Primary lesion.*

- (a) A well marked proliferation of the interpapillary processes.
- (b) A cellular infiltration consisting of (1) numerous typical plasma cells, found diffusely, with no definite arrangement; (2) some extravasated polymorphonuclear leucocytes; (3) small mononuclear leucocytes, connective tissue cells and a few mast-cells. No true giant cells were observed. The fibrous stroma was very delicate and scarce.

II. *Papules removed from the lip* presented practically the same appearances, only the proliferation of the interpapillary processes is much less marked.

Comparing these results with those found by Macleod, Unna, Nicholls, and myself, in man, it would seem that the histological structure is practically the same in human as in experimental yaws.

The Bordet-Gengou Reaction in Yaws.

I have applied this reaction to yaws, following the technique used in syphilis by Wassermann, Neisser and Brück (10. v. 1906). As is well known, the principle of the reaction is as follows: when complement is mixed with the complex antigen + immune-body, and afterwards some sensitized red blood corpuscles are added, no haemolysis takes place, as the complement has been already taken up by the complex antigen + immune-body, and cannot, therefore, become fixed to the haemolytic receptors.

If the complex antigen + immune-body is absent, or only antigen or only immune-body is present, then the complement will remain free and on addition of the sensitized red blood corpuscles, will become fixed to the haemolytic receptors, and haemolysis will take place. From the absence or presence of haemolysis we can therefore detect the presence or absence of the complex antigen + immune-body. As the following experiments prove, it is possible to demonstrate the existence of specific yaws antibodies and antigen.

Experiment I. To the extract of non-ulcerated yaws papules containing abundant *Sp. pertenuis*, some serum (heated to 55° C.) was added, derived from a monkey which had been successfully inoculated with yaws and which had been afterwards treated at intervals with subcutaneous inoculations of yaws material. Then some fresh guinea-pig serum was added (complement) and, after a certain time, some sensitized red blood corpuscles—in my experiments goats' corpuscles—treated with inactivated serum from a rabbit which had been inoculated several times with goats' corpuscles.

Result : no haemolysis.

The experiment was repeated, using the extract of papules taken from six other cases of yaws. The result was constantly the same, namely, no haemolysis took place.

Experiment II. Same procedure as in Experiment I, using, instead of the extract of yaws papules, the extract of leprosy nodules.

Result : well marked haemolysis.

Experiment III. Same procedure, using the extract of nodules taken from a case of pseudo-granuloma pyogenicum.

Result : haemolysis.

Experiment IV. Same procedure, using, instead of the extract of yaws papules, the extract of syphilitic condylomata.

Result : haemolysis.

Experiment V. Same procedure, using the extract of a syphilitic primary sore which contained many *Sp. pallida* Schaudinn.

Result : haemolysis.

Experiment VI. Extract of yaws papules containing *Sp. pertenuis* + serum (heated to 55° C.) of a monkey immunized for syphilis + fresh guinea-pig serum + sensitized corpuscles.

Result : haemolysis.

The experiment was repeated, using the extract of papules from six different cases of yaws ; haemolysis always resulted. It is to be noted that the serum of the monkey contained, with certainty, syphilitic antibodies, as no haemolysis took place when it was inactivated and then had added to it the extract of a primary syphilitic sore, then fresh guinea-pig serum (complement), then sensitized corpuscles.

Experiment VII. Extract of yaws papules + serum (heated to 55° C.) derived from a normal monkey + fresh guinea-pig serum (complement) + sensitized corpuscles.

Result : haemolysis well marked.

Experiment VIII. Extract of spleen juice obtained by puncture of a case of typical yaws + inactivated serum of a monkey immunized for yaws + complement + sensitized corpuscles.

Result : no haemolysis.

Experiment IX. Same procedure as in Experiment VIII, using, instead of the serum of a monkey immunized for yaws, the serum of a monkey immunized for syphilis.

Result : haemolysis.

The above experiments show that it is possible to detect specific yaws antigen in the yaws papules and in the spleen of cases of yaws, and specific yaws antibodies in the blood of monkeys treated with inoculation of yaws material.

The experiments IV, V, VI, IX show also that yaws antibodies and antigen are different from syphilis antibodies and antigen, and therefore syphilis and yaws differ specifically.

Communicability of Yaws. Do Insects play a part in the transmission of the Disease?

It is well known that yaws is in most cases conveyed by direct contact from person to person, usually by absorption of the virus through some pre-existing abraded surface, or through small wounds or ulcerations, which frequently are present on the skin of natives. The simple contact of the virus on normal skin is not sufficient to cause infection ; but very slight abrasions, for instance those due to scratching, are sufficient for the entrance of the virus.

Women are frequently infected by their children, the primary lesion appearing often on the mammae. In the native women of Ceylon the primary lesion frequently develops on the skin of the trunk just above

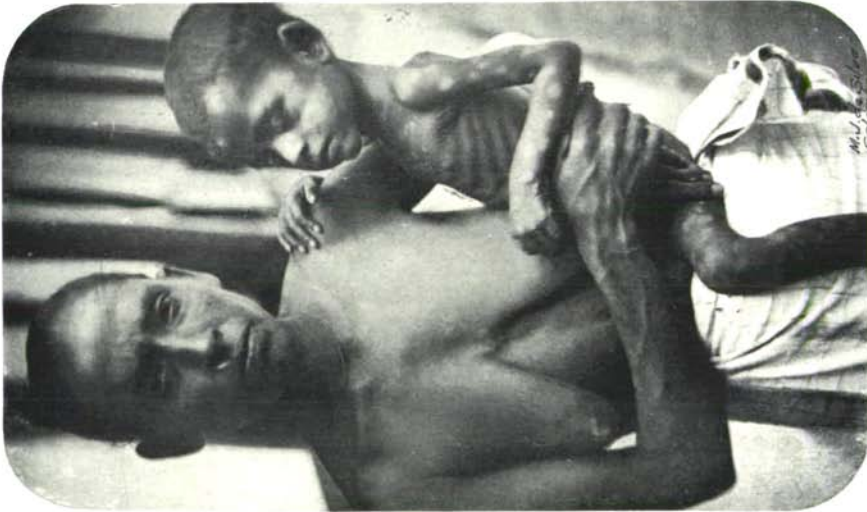

Fig. 1.

Fig. 1. Photograph showing how Ceylon women carry their children, the primary framboetic sore being often found in such women above the hip.

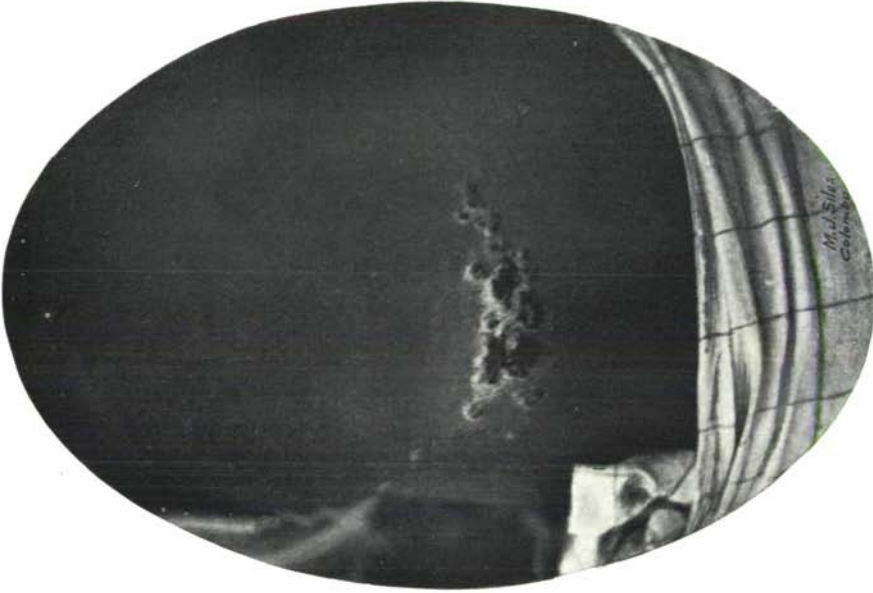


Fig. 2.

Fig. 2. Primary framboetic sore surrounded by lesions of secondary eruption. The same woman as in the picture alongside.

the hip (Plate XVI, Fig. 2). This is due to their habit of carrying the child astride of the hip, as shown on Plate XVI, Fig. 1. If, therefore, a yaws lesion is present on the scrotum or nates of the child it will be continually rubbed against the skin of the mother and she will become infected through any slight abrasion already present or through any abrasion which may be caused by the friction.

In my opinion, however, there can be little doubt that in certain cases insects may carry the disease. It is very noticeable that flies eagerly crowd on the open sores of yaws patients. In the hospitals, as soon as the dressings are removed, the yaws ulcerations become covered with flies sucking with avidity the secretion, which they may afterwards deposit in the same way on ordinary ulcers of other people. Ants are also occasionally found on yaws ulcerations as well as on ordinary ulcers.

In the classical work of Nuttall (1899, p. 34) on the rôle of insects as carriers of parasitic diseases, several authors are quoted (Alibert, Hirsch, Cadet, Wilson) who believe that the infection may be conveyed from one individual to another by flies. Wilson states that this belief prevails also among the natives of the West Indies.

I may quote some of the experiments I have made to prove that flies are instrumental in the dissemination of the disease.

Experiment I (10. xi. 06). Some scrapings were collected from slightly ulcerated papules of a yaws patient. The *Sp. pertenuis* was present, together with various other thicker spirochaetes. (*Sp. obtusa*; *Sp. acuminata*) but no bacteria. The scrapings were placed in a sterile Petri dish. Ten flies (*Musca domestica* and allied species), caught in the rooms of the Bacteriological Institute, were placed inside the Petri dish and left there for half an hour. They fed greedily on the material; then their mouth parts and legs were examined for spirochaetes, extracts and films being made: in nine flies the spirochaetes of the thicker types were found; in two also the *Sp. pertenuis*. As a control five flies were caught the same day, in the same room and examined at once, with negative results as regards the presence of spirochaetes.

Experiment II (12. i. 07). Twenty flies were collected from the rooms of the Bacteriological Institute. The buccal apparatus and legs of five were removed and examined by making extracts and films: no spirochaetes of any kind were present. The other 15 flies were divided in several groups and placed on various semi-ulcerated papules of three yaws patients presenting the *Sp. pertenuis*, and spirochaetes of the thicker type which are often found in semi-ulcerated lesions. The flies were kept in place by covering the papules with a piece of gauze made to adhere to the skin by means of collodion all round the margin. All the flies fed greedily on the ulcerated papules. After two hours the mouth parts were removed, extracts and films made and stained. Out of the 15 flies so examined, in 14 it was possible to detect the coarse spirochaetes, and in two, the *Sp. pertenuis*, as well as the thicker ones.

Transmission of Yaws to Monkeys by means of Flies fed on Yaws Material.

Experiment III (15. XI. 06). Thirty flies were fed in a sterile Petri dish for half an hour on scrapings taken from non-ulcerated papules of a case of yaws, containing only the *Sp. pertenuis*. Three *Semnopithecus priamus* and two *Macacus pileatus* were then infected in this way: over the left eyebrow of each monkey very numerous deep scarifications were made; then five flies, deprived of their wings, were applied to the scarified spots and kept there by means of a piece of gauze smeared with collodion at the margins; the monkeys were prevented from removing the gauze by tying their legs. After two hours the gauze and the flies were removed. Of these monkeys, one *Semnop. priamus* after 45 days developed a small infiltrated spot, which soon became enlarged and covered with a thick crust. The microscopical examination of the lesion showed the presence of *Sp. pertenuis*. The other five monkeys gave negative results.

Experiment IV. Twenty-eight flies (*Musca domestica* and similar species) were caught in one of the rooms of the Bacteriological Institute. The legs and buccal organs of five were removed and examined for spirochaetes, numerous preparations being made, with negative results. The remaining flies, deprived of their wings, were placed on two slightly ulcerated lesions of a yaws patient. The flies were kept on the ulcers by means of pieces of gauze, the margins of which were made to adhere to the skin with a little collodion. The flies readily sucked the secretion of the ulcers. After one hour the flies were removed. Meanwhile seven *Semnopithecus priamus* had been deeply scarified over their eyebrows, and several flies which had fed on the ulcerated yaws lesions were placed on the scarified areas of each monkey and kept in place there for two hours by using the device already described.

One of the monkeys, 46 days later, developed a slightly infiltrated spot, which slowly enlarged into a framboetic nodule covered by a thick crust; the microscopical examination of films taken from this nodule showed the presence of *Sp. pertenuis*. In another monkey, 67 days after inoculation, three tiny papules developed at the place of inoculation; they soon fused together into an infiltrated mass covered by a thick crust. Films made from scrapings of the lesion contained the *Sp. pertenuis*. The remaining five monkeys, so far (15. II. 1907), have given negative results.

SUMMARY AND CONCLUSIONS.

1. Monkeys are susceptible to yaws. The skin eruption in the monkeys I have experimented with (*Semnopithecus priamus* and *Macacus pileatus*) is, as a rule, confined to the seat of inoculation but the infection is general, as is proved by the presence of the *Spirochaeta pertenuis* in the spleen and lymphatic glands.

2. Material obtained from persons suffering from yaws and apparently containing *Spirochaeta pertenuis* only is infective to monkeys.
3. When the *Spirochaeta pertenuis* has been removed from this material by filtration, the latter becomes inert.
4. The inoculation of blood from the general circulation and blood taken from the spleen of yaws patients into monkeys may give positive results.
5. The inoculation of the cerebro-spinal fluid of yaws patients gives negative results.
6. Monkeys successfully inoculated with yaws do not become immune for syphilis.
7. Monkeys successfully inoculated with syphilis do not become immune for yaws.
8. By means of the Bordet-Gengou reaction, it is possible to detect specific yaws antibodies and antigen.
9. Yaws antibodies and antigen are entirely different from syphilitic antibodies and antigen.
10. The presence of the *Spirochaeta pertenuis* in monkeys experimentally inoculated, as well as in yaws patients, is practically constant in the unbroken eruptive lesions; the *Spirochaeta* is frequently present in the spleen and lymphatic glands.
11. Yaws is generally conveyed by actual contact, but under certain circumstances it may be conveyed by flies and possibly by other insects.

REFERENCES.

- ALIBERT. Quoted by Nuttall (1899, p. 34).
- CASTELLANI, A. (17. VI. 1905). *Journ. Ceylon Branch Brit. Med. Assoc.*
 — (5. VIII. 1905). *Brit. Med. Journ.*, vol. II. p. 282.
 — (12. VIII. 1905). *Lancet*, vol. II. p. 468.
 — (11. XI. 1905). *Brit. Med. Journ.*, vol. II. p. 1280.
 — (1. I. 1906). *Journ. Trop. Med.*, vol. IX. p. 1—4.
- NEISSER, BAERMAN and HALBERSTÄDTER (10. VII. 1906). *Münchener med. Wochenschr.*, vol. LIII. p. 1337.
- NUTTALL, G. H. F. (1899). On the rôle of insects, etc., as carriers of bacterial and parasitic diseases. *Johns Hopkins Hosp. Reports*, vol. VIII. p. 34.
- RAT (1891). *Yaws, its Nature and Treatment*. London: Waterlow & Sons, Ltd.
- WASSERMANN, NEISSER and BRÜCK (10. v. 1906). *Deutsche med. Wochenschr.*, vol. XXXII. p. 745.