

The Treatment of Trigeminal Neuralgia in Patients with Multiple Sclerosis using Percutaneous Radiofrequency Rhizotomy

Caglar Berk, Constantine Constantoyannis, Christopher R. Honey

ABSTRACT: Background: Trigeminal neuralgia (TN) has a higher incidence among patients with multiple sclerosis (MS) than in the general population. This cohort of MS patients with TN presents a series of management challenges including poor tolerance of antineuralgic medications and occasional bilateral presentation. We analyzed our surgical series of MS patients presenting with TN who were treated with percutaneous radiofrequency rhizotomy to estimate the success, failure and recurrence rate of this procedure for those patients. **Methods:** Surgical reports were retrospectively reviewed between the years 1996-2000. Patients with MS and TN who received a percutaneous rhizotomy during that time were included in the study and followed until the end of 2002. Data regarding age, sex, duration of MS and pain, response to medical treatment, pain distribution and surgical outcome were evaluated. **Results:** There were thirteen patients with MS and medically refractory TN treated with percutaneous radiofrequency rhizotomy. The average age at diagnosis for MS was 41 with TN beginning an average of eight years later. Following rhizotomy, complete pain relief without the need for any medication was achieved in 81% of the patients. The addition of medications resulted in pain control in the remaining patients. During a mean follow-up period of 52 months, there was a 50% recurrence rate. There were no complications related to the procedure and the associated facial numbness was well-tolerated. **Conclusions:** Percutaneous radiofrequency rhizotomy is a safe and effective method for the treatment of TN in patients with MS. The unique susceptibility of this cohort to the side effects of antineuralgic medications may require early consideration of rhizotomy.

RÉSUMÉ: La rhizotomie percutanée par courants de radiofréquence dans le traitement de la névralgie du trijumeau chez des patients atteints de sclérose en plaques. Introduction: L'incidence de la névralgie du trijumeau (NT) est plus élevée chez les patients atteints de sclérose en plaques (SEP) que dans la population générale. Les patients atteints de SEP qui présentent une NT sont difficile à traiter, entre autres parce qu'ils tolèrent mal les médicaments antinévralgiques et que, chez certains, la symptomatologie est bilatérale. Nous avons analysé notre série de cas chirurgicaux de patients atteints de SEP et présentant une NT qui ont été traités par rhizotomie percutanée par courants de radiofréquence afin d'évaluer le taux de succès, d'échec et de récurrence chez ces patients. **Méthodes:** Les dossiers chirurgicaux de 1996 à 2000 ont été révisés rétrospectivement. Les patients atteints de SEP et de NT qui ont subi une rhizotomie percutanée par courants de radiofréquence pendant cette période ont été inclus dans l'étude et suivis jusqu'à la fin de 2002. Les données sur l'âge, le sexe, la durée de la SEP et de la douleur, la réponse au traitement médical, la distribution de la douleur et le résultat chirurgical ont été évalués. **Résultats:** Treize patients atteints de SEP et de névralgie du trijumeau réfractaire au traitement médical ont subi une rhizotomie percutanée par courants de radiofréquence. L'âge moyen au moment du diagnostic de SEP était de 41 ans et en moyenne la névralgie du trijumeau était apparue huit ans après le diagnostic. Suite à la rhizotomie, 81% des patients étaient complètement soulagés et n'avaient pas besoin de médicaments. L'ajout d'une médication a contrôlé la douleur chez les autres patients. On a observé un taux de récurrence de 50% pendant le suivi d'une durée moyenne de 52 mois. Il n'y a eu aucune complication reliée à l'intervention et l'engourdissement facial résultant de la chirurgie était bien toléré. **Conclusions:** La rhizotomie percutanée par courants de radiofréquence est une méthode sûre et efficace pour traiter la NT chez les patients atteints de SEP. Il faut envisager la rhizotomie tôt dans la prise en charge de ces patients à cause de leur sensibilité particulière aux effets secondaires des antinévralgiques.

Can. J. Neurol. Sci. 2003; 30: 220-223

Trigeminal neuralgia (TN) is the most common cranial neuropathy with an average incidence of four per 100,000 in the normal population.¹ This incidence may rise to 2% in patients with a degenerative central nervous system disease such as multiple sclerosis (MS).²⁻⁵ Most patients are treated initially with a variety of medications (e.g. carbamazepine, gabapentin, phenytoin, and baclofen). For those who do not receive adequate pain relief on medications or who can not tolerate their side effects, surgery is an excellent option. Although the best surgical treatment for TN in the general population remains a controversy,^{6,7} percutaneous procedures are widely accepted as

the surgical treatment of choice for TN in patients with MS.⁵

This study reviews the results of percutaneous radiofrequency rhizotomy for TN in patients with MS, treated at the tertiary

From the Surgical Centre for Movement Disorders, Stereotactic and Functional Neurosurgery, University of British Columbia, Vancouver, British Columbia, Canada.
RECEIVED DECEMBER 12, 2001. ACCEPTED IN FINAL FORM FEBRUARY 24, 2003.
Reprint requests to: C.R. Honey, Director, Surgical Centre for Movement Disorders, Stereotactic and Functional Neurosurgery, University of British Columbia, Suite 325, 700 West 10th Avenue, Vancouver, BC, Canada V5Z 4E5

neurosurgery referral centre for the province of British Columbia.

PATIENTS AND METHODS

Patient population

The records of the senior author (CRH) at the Division of Neurosurgery, University of British Columbia, were retrospectively reviewed for the surgical treatment of TN between the years 1996-2000. There were 86 patients treated for TN. Among them, 13 (15%) were diagnosed with clinically definite MS according to the criteria defined by Poser.⁸ Of these patients, three (23 %) were male and ten (77 %) were female. The youngest patient was 41 and the oldest was 75 years old (mean age: 54 years). The age at diagnosis of MS among the patients was 41 ± 11 years (mean \pm standard deviation). The age of onset for TN amongst these patients was 49 ± 13 years (mean \pm standard deviation). Trigeminal neuralgia usually started after the diagnosis of MS, but in two patients TN was the first presenting symptom that eventually led to the diagnosis of MS. The diagnosis of TN was made clinically. Patients described short stabbing or electric pain localized within the trigeminal dermatome. The pain was often triggered by touch (eating, brushing teeth, talking). Between the painful episodes, the patient was pain-free (i.e. it was not a continuous burning dysesthesia). The onset of pain was not associated with dental trauma or a herpetic rash. Although the typical quality of pain was sharp or electrical, a few patients also described initial sharp pain which had then evolved into a more burning quality.

Six patients had right sided pain, four had left sided pain and three (23%) had bilateral pain. The bilateral cases were considered as two different cases (total $n=16$) since they occurred and were managed at separate surgical sessions. None of the patients had pain in the first division, five (31%) had pain in the second division, seven (44%) had pain in the third division and four (25%) had pain both in the second and third divisions.

Patient selection criteria

All the patients included in the study had been diagnosed with clinically definite MS by a neurologist. Patients were referred for surgery if their medications (e.g. carbamazepine, phenytoin, gabapentin, and/or baclofen) failed to relieve pain or produced intolerable side effects. All patients had CT and/or MRI scans to exclude any other intracranial pathology that might be causing symptomatic TN. All the TN patients with MS were offered percutaneous radiofrequency rhizotomy as the surgical treatment of choice.

Surgical technique

All procedures were done under neuroleptanesthesia using intravenous pulses of propofol (Abbott, Montreal, QC) under the supervision of an anesthesiologist. The foramen ovale was punctured as previously described using fluoroscopic guidance in the lateral and submentovertical projections.⁹ The anteroposterior location of the foramen was often found at the junction of the clivus and petrous apex on lateral x-ray projection. After the foramen was passed, the stylet was replaced with the lesioning electrode (either the Rosomoff cordotomy type, or Tew kit, straight or curved; 5mm open tip, Radionics

Inc., Burlington, MA). The final position of the electrode was manipulated to produce paresthesia in the affected division(s) of the trigeminal nerve with stimulation (0-0.02V, 1msec, 50Hz). Once the localization was confirmed, lesions were made at 65 – 70°C or 80-110 mA for 60 seconds. Following each lesion, the patients were tested for hypalgesia in the desired territory. Our ideal endpoint was reached when patients could feel the touch of a pinprick but could not determine if it was sharp or dull. The patients were usually discharged on the same day. Patients were weaned off their pain medications during the postoperative period.

RESULTS

A timeline depicting each patient's pain and procedures is presented in the Figure. The mean follow-up from the time of the first rhizotomy was 52 months (range: 24-84 months). Each side of the bilateral TN cases was considered as a separate case to calculate a procedural recurrence rate of 50% (26 procedures/13 patients) at some point during their follow-up. This relatively high rate of recurrence may partially be due to the fact that MS is a progressive disease and pain cured in one division may reappear in another. Two patients had 'a recurrence' of their neuralgia on the same side of the face but in a different division.

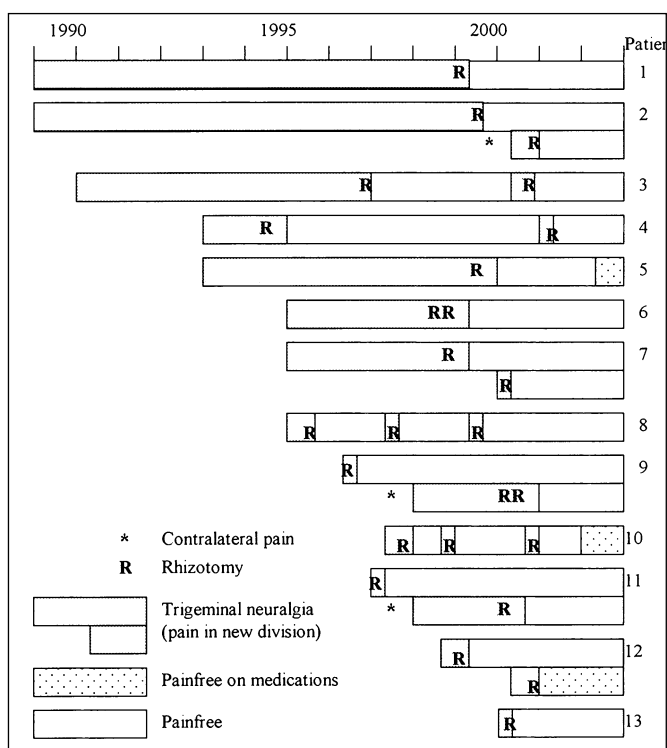


Figure: Timeline of trigeminal neuralgia (1989-2003)
The pain for each patient is shown over time (1989 – 2003). The three patients who developed new pain on the opposite side were considered new cases of trigeminal neuralgia not recurrences. There were two patients who developed neuralgia in a different division of the trigeminal nerve on the same side of the face; they were considered as recurrences.

The pain in the original division was well-controlled throughout follow-up. In those patients who initially obtained complete pain relief following their rhizotomy but later had a recurrence in the same location, the mean time for recurrence was 30 months.

Eight cases were managed with a single rhizotomy. Complete pain relief with discontinuation of all medications was achieved in seven cases. One patient in this group required a lower dose of their antineuralgic medication to remain pain-free. A second procedure was needed to control the pain in six cases. In this group, five patients were able to remain off all medications. A third procedure was needed to control pain in two cases, of which one did not require any medications during the post-operative period. We were, therefore, able to achieve complete pain relief without any need for postoperative medication in 13/16 cases (81%). Complete pain relief (with any number of procedures) requiring some postoperative medication was achieved in the remaining three cases (19%). Complete pain relief, either with or without antineuralgic medication, was therefore achieved in 100% of patients with TN due to MS using percutaneous radiofrequency rhizotomy. There were no complications of the procedure (e.g. anesthesia dolorosa, corneal ulceration, inability to chew). The facial numbness created by this procedure appears to be well-tolerated in this cohort. Patients typically no longer notice the numbness after a few months.

DISCUSSION

The Canadian collaborative study involving 15,504 patients quoted the prevalence of MS at 100 per 100,000.¹⁰ This is higher than the average figures for most parts of the world.¹¹ The clinical association of TN with MS is well-known. Patients with MS develop TN with an average incidence of 2%.²⁻⁵ There are many hypotheses regarding the pathophysiology of TN in MS.¹² Demyelination could result in increased excitability of the trigeminal caudalis nucleus although this has not been confirmed pathologically.^{4,13} Demyelination of the trigeminal nerve could result in ephaptic transmission.¹⁴ In our surgical TN series, 15% (13/86 patients) of the patients with TN had MS. In a similar tertiary setting, Sweet reported comparable rates with 16% of his TN patients with MS.¹⁵

The age of onset of TN in MS is the same or slightly younger than for idiopathic TN (except when TN is the only or presenting symptom that leads to the diagnosis of MS).⁵ The mean age of our patients was 54 years. They developed TN an average of eight years after their diagnosis of MS. In two of our patients, however, pain was the presenting symptom that led to the diagnosis of MS. In standard neurological practice, almost all the patients with TN (regardless of etiology) are first managed with either one or a combination of medications such as carbamazepine, gabapentin, phenytoin, or baclofen. Patients with MS, however, are especially prone to develop drug intolerance such as sedation or exacerbation of other MS symptoms.¹⁶ There is a perception that percutaneous rhizotomy should be reserved as a very last resort for the treatment of TN in patients with MS. We would argue that it should be considered sooner. Patients do not necessarily have to put up with medication side effects to be pain-free. In our experience, rhizotomy is safe and effective. Patients often report that they are

as happy to be off their antineuralgic medications as they are to be pain-free.

Bilateral cases of TN are always more challenging and their management more controversial.¹⁷ This also applies to the patients with TN and MS. Bilateral TN is significantly more common in MS patients (18%) when compared to the normal population (5%).^{2,4,5,18} As bilateral lesioning of the trigeminal ganglion may cause severe difficulty in chewing, eating and swallowing due to masseter paralysis and loss of tactile sensation in the mouth, milder lesioning of the ganglion is advised.^{2,18} As a precaution, it is preferable to manage those cases with sequential, not simultaneous, surgical sessions.^{5,17} We had three bilateral cases in our series that were managed successfully this way.

Although the surgical treatment for idiopathic TN remains controversial, we advocate percutaneous rhizotomy for those with MS.^{6,7} There are reports of success following microvascular decompression² but in cases of spontaneous demyelination unrelated to a vascular compression, this more invasive approach may fail.¹⁹⁻²¹ We have favoured radiofrequency lesioning because our experience suggests that the location and extent of the lesion can be more precisely controlled than with glycerol or balloon compression. Reports of radiosurgery for trigeminal neuralgia are increasing although the benefit may be delayed and there is little information on how patients with MS tolerate this treatment.

Percutaneous radiofrequency rhizotomy has proven to be safe and effective in large series of idiopathic TN.^{22,23} "Complete success" with a percutaneous rhizotomy procedure should mean a pain-free patient off all pain medication. Our complete success rate with MS patients (81%) was comparable to those quoted in literature both for idiopathic and MS related cases.^{5,21,22} Patients with MS do not appear to have a higher complication rate following rhizotomy⁵ and there were no complications in our series. None of our patients developed anesthesia dolorosa, difficulty chewing, corneal complications, painful dysesthesia, or intolerance of their facial numbness. Pain can occasionally take longer to disappear postoperatively in MS patients. We therefore recommend a slow taper of their antineuralgic medications.

We found a high proportion (15%) of our patients with TN had MS. The occurrence of TN in young patients or bilaterally should prompt an investigation for MS. Neurologists may wish to consider rhizotomy earlier for their TN patients with MS because this cohort has an especial poor tolerance to their antineuralgic medications. Percutaneous radiofrequency rhizotomy was an effective method of pain control in our series. Satisfactory pain control was achieved in all patients and all antineuralgic medications were discontinued 81%.

REFERENCES

1. Maxwell RE. Clinical diagnosis of trigeminal neuralgia and differential diagnosis of facial pain. In: Rovit RL, Murali R, Janetta PJ, (Eds). *Trigeminal Neuralgia*. Baltimore: Williams & Wilkins, 1990, 53-77.
2. Brisman R. Trigeminal neuralgia and multiple sclerosis. *Arch Neurol* 1987; 44: 379-381.
3. Hooze JP, Redekop WK. Trigeminal neuralgia with multiple sclerosis. *Neurology* 1995; 45: 1294-1296.

4. Jensen TS, Rasmussen P, Reske-Nielsen E. Association of trigeminal neuralgia with multiple sclerosis: clinical and pathological features. *Acta Neurol Scand* 1982; 65: 182-189.
5. Kanpolat Y, Berk C, Savas A, Bekar A. Percutaneous controlled radiofrequency rhizotomy in the management of patients with trigeminal neuralgia due to multiple sclerosis. *Acta Neurochir (Wien)* 2000; 142: 685-690.
6. Kanpolat Y, Jho HD, Tew JM, et al. Trigeminal neuralgia: clinical controversy. *Surg Neurol* 1996; 45: 406-408.
7. Berk C, Honey CR. Microvascular decompression for trigeminal neuralgia in patients over 65 years of age. *Br J Neurosurg* 2001; 15:76.
8. Poser CM, Paty DW, Scheinberg L. New diagnosis criteria for multiple sclerosis: guidelines for research protocols. In: Poser CM, Paty DW, Scheinberg L, et al (Eds). *The Diagnosis of Multiple Sclerosis*. New York: Thieme Stratton, 1984, 225-229.
9. Sweet WH, Wepsic JG. Controlled thermocoagulation of trigeminal ganglion and rootlets for differential destruction of pain fibers: Part I. Trigeminal neuralgia. *J Neurosurg* 1974; 39: 143-156.
10. Ebers GC, Yee IML, Sadovnick AD, et al. Conjugal multiple sclerosis: population-based prevalence and recurrence risks in offspring. *Ann Neurol* 2000; 48: 927-931.
11. Victor M, Ropper AH. *Principles of Neurology*. New York: McGraw Hill, 2001, 954-982.
12. Fromm GH, Terrence CF, Maroon JC. Trigeminal neuralgia: current concepts regarding etiology and pathogenesis. *Arch Neurol* 1984; 41: 1204-1207.
13. Iraqui VJ, Wiederholt WC, Romine JS. Evoked potentials in trigeminal neuralgia associated with multiple sclerosis. *Arch Neurol* 1986; 43: 444-446.
14. Kerr FW. Pathology of trigeminal neuralgia: light and electron microscopic observations. *J Neurosurg* 1967; 26: 132-137.
15. Sweet WH. The pathophysiology of trigeminal neuralgia. In: Gildenberg PL, Tasker RR, (Eds). *Textbook of Stereotactic and Functional Neurosurgery*. New York: McGraw Hill, 1998, 1667-1686.
16. Sweet WH. The treatment of trigeminal neuralgia. *N Engl J Med* 1986; 315: 174-177.
17. Berk C. Bilateral trigeminal neuralgia: a therapeutic dilemma. *Br J Neurosurg* 2001; 15: 198.
18. Brisman R. Bilateral trigeminal neuralgia. *J Neurosurg* 1987; 67: 44-48.
19. Broggi G, Franzini A, Servello D, et al. Microvascular decompression: is it a rational surgical operation for trigeminal neuralgia in MS patients? *Acta Neurochir (Wien)* 1998; 140: 853.
20. Crooks DA, Miles JB. Trigeminal neuralgia due to vascular compression in multiple sclerosis: postmortem findings. *Br J Neurosurg* 1996; 10: 85-88.
21. Taha JM, Tew JM Jr. Comparison of surgical treatments of trigeminal neuralgia. Percutaneous techniques and posterior fossa exploration (abstr.). *J Neurosurg* 1994; 80: 383.
22. Kanpolat Y, Savas A, Bekar A, Berk C. Percutaneous controlled radiofrequency rhizotomy for the treatment of idiopathic trigeminal neuralgia: 25-year experience with 1600 patients. *Neurosurgery* 2001; 48: 524-534.
23. Tekkok IH, Brown JA. The neurosurgical management of trigeminal neuralgia. *Neurosurg Quart* 1996; 6: 89-107.