


Kai Tang¹ , Jiayi Wu², Xiaoxi Liu¹ and Shuiyun Wang¹

Brief Report

Cite this article: Tang K, Wu J, Liu X, and Wang S (2024) Paediatric hypertrophic cardiomyopathy secondary to Danon disease. *Cardiology in the Young* **34**: 201–204. doi: [10.1017/S1047951123003815](https://doi.org/10.1017/S1047951123003815)

Received: 11 May 2023
Revised: 11 September 2023
Accepted: 12 October 2023
First published online: 22 November 2023

Keywords:

cardiomyopathy; Danon disease; LAMP-2; mutation

Corresponding author:

S. Wang; Email: wsymd@sina.com

Kai Tang and Jiayi Wu are contributed equally to this work.

¹Department of Cardiovascular Surgery, State Key Laboratory of Cardiovascular Disease, National Center for Cardiovascular Diseases, Chinese Academy of Medical Sciences, Peking Union Medical College, Fuwai Hospital, Beijing, China and ²Department of Pathology, Key Laboratory of Carcinogenesis and Translational Research (Ministry of Education), Peking University Cancer Hospital and Institute, Beijing, China

Abstract

Danon disease is a rare X-linked disorder caused by deficiency of the lysosome-associated membrane protein-2. We report a case of hypertrophic obstructive cardiomyopathy secondary to a novel mutation in the lysosome-associated membrane protein-2 gene in a 10-year-old male adolescent. We performed a modified extended Morrow procedure to minimise the risk of death and improve the patient's quality of life. The patient did not have exertional dyspnoea, and auscultation did not reveal a cardiac murmur at 1-year follow-up.

Hypertrophic cardiomyopathy can cause cardiac hypertrophy and even premature death.¹ Danon disease, an X-linked dominant disorder associated with mutations in the lysosome-associated membrane protein-2 gene², is characterised by hypertrophic cardiomyopathy and concomitant skeletal myopathy. Male carriers usually manifest with cardiomyopathy before 20 years of age.³ Lysosome-associated membrane protein-2 deficiency results in the accumulation of autophagic vacuoles in tissues, including within cardiac muscles. We report a paediatric case of hypertrophic cardiomyopathy in a patient with Danon disease, who underwent a modified extended Morrow procedure. Genetic analysis of the lysosome-associated membrane protein-2 gene showed a hemizygous c.973-974insC (p. L325fs) variant, which resulted in a frameshift and premature stop codon.

Case report

The patient's guardian provided written informed consent for study participation and for disclosure of the patient's data. The patient initially presented to the Division of Pediatrics at 3 years of age for evaluation of unexplained elevation of liver enzymes (alanine transaminase and aspartate transaminase). Clinical examination revealed no exertional dyspnoea, cardiac murmur, or hepatomegaly at that consultation. He was referred to another hospital for evaluation of a cardiac murmur and was diagnosed with left ventricular hypertrophy at 7 years of age. The echocardiogram revealed hypertrophic cardiomyopathy, with a peak instantaneous gradient of 33mmHg. The intraventricular septal thickness was 20.6 mm. There was no left ventricular outflow obstruction at that time. He was referred to the cardiology clinic at our hospital at 10 years of age for management of hypertrophic obstructive cardiomyopathy. The patient's mother was first diagnosed with hypertrophic cardiomyopathy at the age of 12 years, and she underwent successful heart transplantation at the age of 30 years. Sequence analyses of 392 genes [including galactosidase, acid -1,4-glucosidase, lysosome-associated membrane protein-2, etc] were performed in the patient and his parents. Only a lysosome-associated membrane protein-2 mutation was found in the boy. Genetic analysis showed a hemizygous c.973-974 insC (p.L325fs) variant of lysosome-associated membrane protein-2, which resulted in a frameshift and a premature stop codon. The patient's mother was heterozygous for this variation (Fig. 1).

The patient's physical and mental status examinations were unremarkable. He was asymptomatic except for dyspnoea on exertion. Neurologic examination revealed no muscle atrophy or abnormal muscle tone. The routine urine test and renal function tests were within normal range. Intraocular pressure was 15mmHg on left and 18mmHg on right. Ophthalmic examination does not reveal myopia, lenticular opacities, and peripheral pigmentary retinopathy. Electrocardiography showed a wide QRS complex, sinus rhythm, an incomplete right bundle branch block, ST changes, and signs of left ventricular hypertrophy. Auscultation revealed a rough systolic ejection murmur over the left third intercostal space. Blood pressure was 100/69mmHg. Cardiac MRI and echocardiography (Fig. 2) revealed significant hypertrophy and obstruction of the left ventricular (interventricular septum 30 mm, peak left ventricular outflow tract gradient 88 mmHg) and mitral valve insufficiency. Laboratory abnormalities included the following: creatine kinase 606 mg/dL (reference:0–200 IU/L),

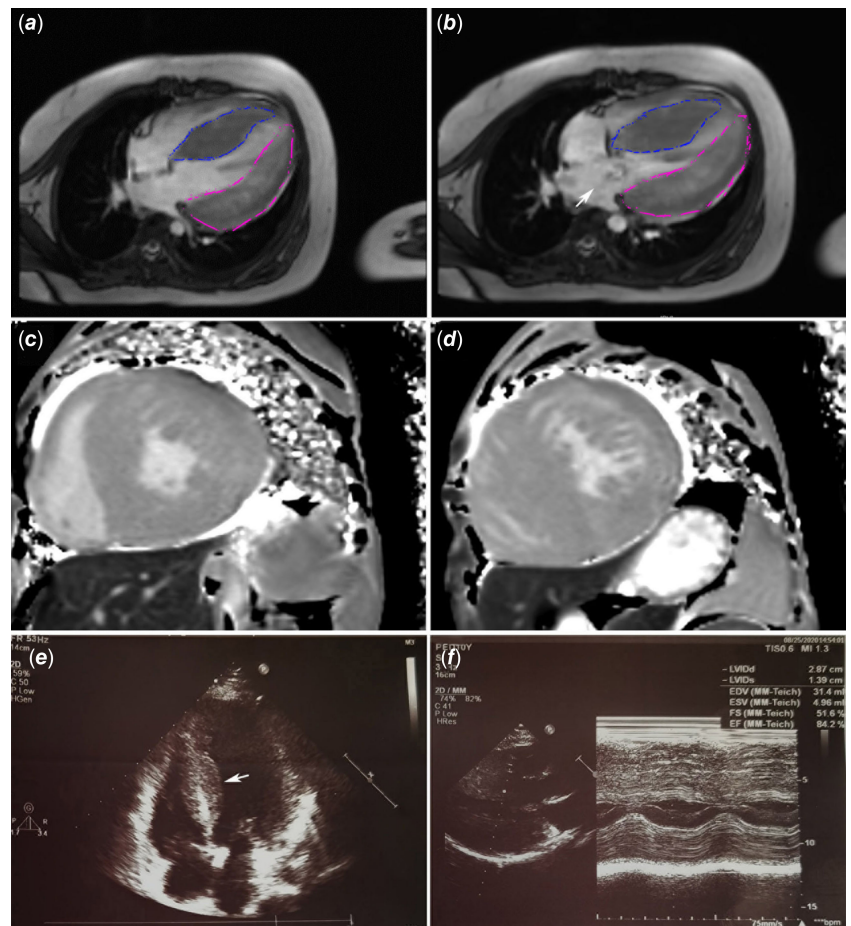
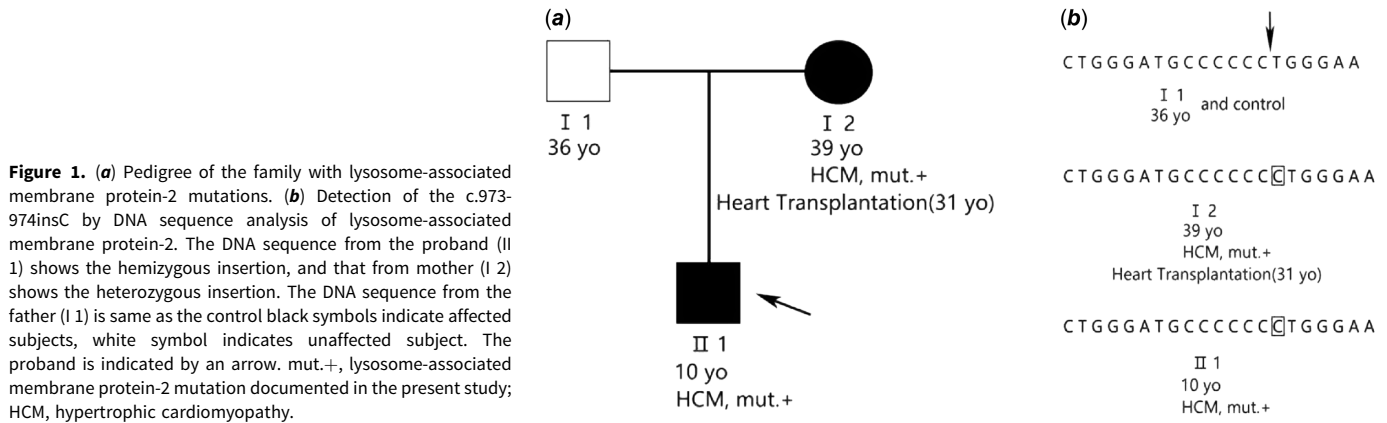


Figure 2. Cardiac MRI and echocardiographic scan showing hypertrophy and obstruction of the left ventricle. **(a–b)** A high-velocity jet can be detected as an area of high signal intensity within the left ventricular outflow tract on the four-chamber view. **(c–d)** Short-axis images show symmetric thickening of the left ventricular myocardium. **(e)** Apical four-chamber view. **(f)** Parasternal long-axis view. LV = left ventricle; MRI = magnetic resonance imaging, blue line of dashes: ventricular septum, red line of dashes: left ventricular wall.

aspartate transaminase 240 IU/L (reference: 9–50 IU/L), alanine transaminase 122 IU/L (reference: 9–50 IU/L), and n terminal pro-B type natriuretic peptide 28,496 pg/mL (reference: <150 pg/mL). The patient showed progression of hypertrophic obstructive cardiomyopathy and mitral valve insufficiency; therefore, we performed a modified extended Morrow procedure. Histopathological evaluation of myocardial tissue (Fig. 3) showed fibres containing small vacuoles and intracellular accumulation of autophagic vesicles. He was discharged home on atenolol 12.5 mg quaque die (QD). The patient had no exertional dyspnoea and auscultation did not reveal a cardiac murmur at 1-year follow-up. His N terminal pro-B type natriuretic peptide (705 pg/mL) remains

mildly elevated. Increased liver enzymes (aspartate transaminase 258 U/L, alanine transaminase 123 U/L) and creatine kinase (CK) (420 U/L) plasma levels were observed. Echocardiography (Fig. 3) revealed an interventricular septum measuring 18 mm and peak left ventricular outflow tract gradient of 7 mmHg. The echocardiogram and treatment of the patient from 2013 to 2022 are shown in Table 1.

Discussion

Nishino first described mutations in the lysosome-associated membrane protein-2 gene as the pathogenetic mechanism

Table 1. The echocardiogram and treatment of the patient from 2013 to 2022

	2013.10	2014.1	2018.7	2019.12	2020.8	2021.3	2022.3
Age(year and month)	3y2m	3y5m	7y11m	9y4m	10y	10y7m	11y7m
LVEF(%)	72	71	69	74	70	72	62
Interventricular septum(mm)	6	9	20.6	25.5	30	33	18
LVOT gradient(mmHg)	NA	5.2	33	59	49	88	7
LVED(mm)	33.8	31	32	32	31	31	40
LVOTO	NO	NO	NO	YES	YES	YES	NO
Treatment	No regular medication		Coenzyme Q10, Atenolol		Surgery		Coenzyme Q10,Atenolol

LVEF = left ventricular ejection fraction; LVOT = left ventricular outflow tract; LVED = left ventricular end diastolic diameter; LVOTO = left ventricular outflow track obstruction.

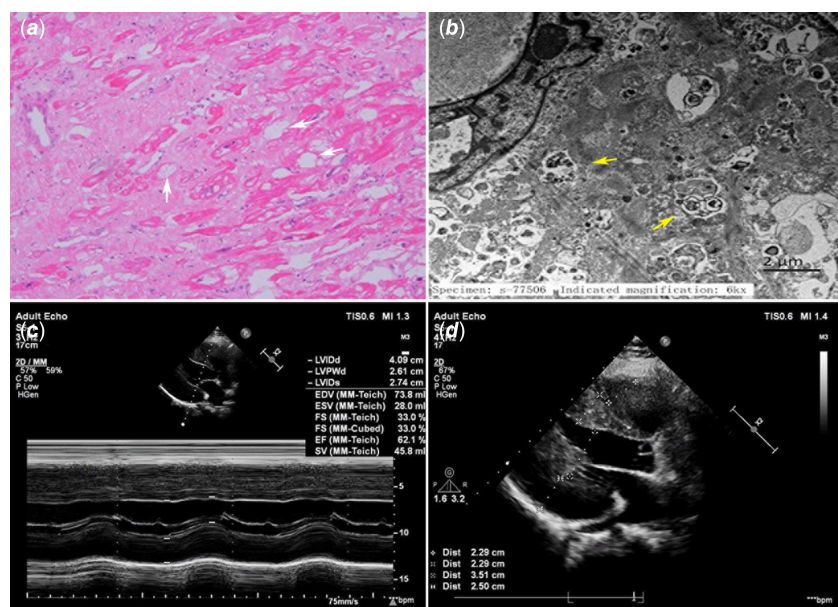


Figure 3. (a) Histopathological evaluation of a myocardial tissue specimen showing significant cardiomyocyte hypertrophy accompanied by widespread vacuolar degeneration (white arrow). (b) Glycogen accumulation is observed within cardiomyocytes in addition to intracellular accumulation of autophagic vesicles (yellow arrow). (c-d) Echocardiographic scan showing reduced thickness of the basal segment of the ventricular septum and a normal left ventricular outflow tract.

underlying Danon disease.⁴ Danon disease may present with primary cardiomyopathy, which is typically severe and shows early onset.⁵ Additionally, cardiomyopathy in patients with this disease is invariably life-threatening in males; in a study of 20 male patients, 19 died before 30 years of age.³ Premature deaths were due to severe heart failure or arrhythmia in all cases. Our patient presented with hypertrophic cardiomyopathy but without skeletal myopathy and intellectual disability; therefore, early diagnosis was important to avoid sudden death in our patient with Danon disease. We recommend that lysosome-associated membrane protein-2 gene testing should be considered in patients diagnosed with hypertrophic cardiomyopathy with evidence of elevated serum CK and/or transaminases. Cardiac transplantation remains the mainstay of treatment for cardiomyopathy in patients with Danon disease.⁶ However, the patient may die while waiting for a heart transplant or due to allograft rejection after cardiac transplantation.⁷ Our patient was only 10 years old, and an appropriate donor was unavailable. His phenotype is restricted to heart disease. Arad described this phenotype could be due to the residual function of the lysosome-associated membrane protein-2 protein.⁸ There is no specific guideline for cardiomyopathy caused by Danon disease. However, in the presence of significant cardiac

hypertrophy with obstruction, myectomy for individuals with hypertrophic cardiomyopathy could be considered.⁹ Obstruction causes an increase in left ventricular systolic pressure, which leads to a complex interplay of abnormalities including elevation of left ventricular diastolic pressure, prolongation of ventricular relaxation, myocardial ischaemia, mitral regurgitation, and a decrease in forward cardiac output. The mechanism of the outflow tract gradient was thought to be caused by systolic contraction of the hypertrophied basal ventricular septum basal and the mitral valve leaflets encroaching on the left ventricular outflow tract.¹⁰ Our patient didn't have significant SAM. He could generate large left ventricular outflow tract gradients under exercise. Importantly, it has been established that left ventricular outflow tract obstruction contributes to the heart failure. Acute obstruction can cause a sudden death. His parents didn't want to take a risk. Based on our rich experience in myocardial resection surgery and the wishes of the patient's parents. After discussions within hospital, it is believed that myocardial resection is beneficial. The patient may obtain a long-term survival after relieving the left ventricular outflow obstruction. Therefore, we performed a modified extended Morrow procedure to minimise the mortality risk and improve quality of life. The patient did well in the post-operative period and

had no difficulty climbing stairs during school. We observed an excellent surgical outcome at 1-year post-operative follow-up. The modified extended Morrow procedure may be a useful alternative to cardiac transplantation in patients with Danon disease. However, the information about long-term prognosis after modified extended Morrow procedure therapy in such patients is limited.

Intracellular accumulation of autophagic vacuoles represents the histopathological hallmark of Danon disease.¹¹ Histopathological evaluation revealed small vacuoles in myocardial tissue specimens in our patient. Autophagic vacuoles were observed within hepatocytes in a lysosome-associated membrane protein-2-deficient mouse model;¹² liver enzyme abnormalities detected in most patients with Danon disease may be attributable to this fact. Our patient was initially evaluated at 3 years of age for unexplained elevation of liver enzymes. Therefore, it is important to perform muscle biopsies and genetic analysis in patients with unexplained abnormalities in liver enzymes. The hemizygous c.973-974 insC (p.L325fs) variant was identified as an lysosome-associated membrane protein-2 variant in our patient.

Conclusions

We report a lysosome-associated membrane protein-2 variant (c.973-974 insC) in a male adolescent with early-onset cardiomyopathy. The modified extended Morrow procedure may serve as a useful therapeutic strategy to minimise the risk of mortality and improve quality of life as well as prognosis in these patients.

Author contributions. KT, JW, and SW contributed to conception and design of the study. SW is the surgeon of operation. XL organised the database. KT wrote the first draft of the manuscript. JW wrote sections of the manuscript. All authors read and approved the final version of the manuscript

Financial support. This work was financially supported by the Fundamental Research Funds for the Central Universities (3332022019). The authors confirm that there are no known conflicts of interest associated with this publication.

Competing interests. None.

References

1. Maron BJ. Cardiology patient pages. Hypertrophic cardiomyopathy. *Circulation* 2002; 106: 2419–2421.
2. Ng KM, Mok PY, Butler AW, et al. Amelioration of X-linked related autophagy failure in Danon disease with DNA methylation inhibitor. *Circulation* 2016; 134: 1373–1389.
3. Sugie K, Yamamoto A, Murayama K, et al. Clinicopathological features of genetically confirmed Danon disease. *Neurology* 2002; 58: 1773–1778.
4. Nishino I, Fu J, Tanji K, et al. Primary LAMP-2 deficiency causes X-linked vacuolar cardiomyopathy and myopathy (Danon disease). *Nature* 2000; 406: 906–910.
5. Cenacchi G, Papa V, Pegoraro V, Marozzo R, Fanin M, Angelini C. Review: Danon disease: review of natural history and recent advances. *Neuropathol Appl Neurobiol* 2020; 46: 303–322.
6. Regelsberger G, Hoftberger R, Pickl WF, et al. Danon disease: case report and detection of new mutation. *J Inher Metab Dis* 2009; 32: S115–22.
7. Sabourdy F, Michelakakis H, Anastasakis A, et al. Danon disease: further clinical and molecular heterogeneity. *Muscle Nerve* 2009; 39: 837–844.
8. Arad M, Maron BJ, Gorham JM, et al. Glycogen storage diseases presenting as hypertrophic cardiomyopathy. *N Engl J Med* 2005; 352: 362–372.
9. Taylor MRG, Adler ED. Danon disease. In: Adam MP, Mirzaz GM, Pagon RA, et al (eds). *GeneReviews*[®] [Internet]. University of Washington, Seattle (WA), Seattle, 2020: 1993–2023.
10. Bernard JG, Barry JM, Robert OB, et al. 2011 ACCF/AHA guideline for the diagnosis and treatment of hypertrophic cardiomyopathy: a report of the American college of cardiology foundation/American heart association task force on practice guidelines. *Circulation* 2011; 124: 2761–2796.
11. Rowland TJ, Sweet ME, Mestroni L, Taylor MR. Danon disease - dysregulation of autophagy in a multisystem disorder with cardiomyopathy. *J Cell Sci* 2016; 129: 2135–2143.
12. Tanaka Y, Guhde G, Suter A, et al. Accumulation of autophagic vacuoles and cardiomyopathy in LAMP-2-deficient mice. *Nature* 2000; 406: 902–906.