

Scratch the surface: Histopathology of foot-pad dermatitis in turkeys (Meleagris gallopavo)

J Stracke^{*†}, D Klotz[‡], P Wohlsein[‡], S Döhring[§], N Volkmann[†], N Kemper[†] and B Spindler[†]

[†] Institute for Animal Hygiene, Animal Welfare and Farm Animal Behaviour, University of Veterinary Medicine Hannover, Foundation, Bischofsholer Damm 15, 30173 Hannover, Germany

[‡] Department of Pathology, University of Veterinary Medicine Hannover, Foundation, Bünteweg 17, 30559 Hannover, Germany

[§] Faculty of Agricultural Sciences and Landscape Architecture, University of Applied Sciences Osnabrück, Am Krümpel 31, 49090 Osnabrück, Germany

* Contact for correspondence: jenny.stracke@tiho-hannover.de

Abstract

Foot-pad dermatitis (FPD) is an important indicator of animal welfare in turkeys (*Meleagris gallopavo*). The present study aimed to evaluate the reliability and validity of a commonly used five-point visual score (VC), assessing FPD based on lesion size by implementing histopathological analysis. In 100 turkey feet (20 per scale scored by the VC), the size of both the foot-pad and the alteration were measured. Subsequently, a histopathological analysis was performed, examining the occurrence and severity grade of different parameters. The study addressed three main goals: (i) examining the reliability of the scoring system concerning the evaluated size of FPD; (ii) assessing histopathological parameters to analyse patterns, reflecting the categories of the scoring system; and (iii) finding threshold values to avoid the occurrence of ulcerations. The study found good observer reliabilities for the VC, but measuring the relative size of alterations resulted in divergent values according to the original specifications. With regard to the histopathological parameters, no clear patterns were found in the respective VC scoring levels. However, ulcerations revealed a significant effect on the size of the alteration, showing a greater grade of severity with increasing lesion size. Regarding the occurrence of ulcerations, optimum threshold values could be identified even in very small lesions. This study helps contribute to a better understanding of the pathophysiology of FPD. It also raises the question as to whether, in light of animal welfare concerns, threshold values of visual systems should be adjusted to avoid ulcerations, considering the outcome of our histopathological assessment.

Keywords: animal welfare, foot-pad dermatitis, FPD, histopathology, scoring systems, turkeys

Introduction

Foot-pad dermatitis (FPD) is one of the most important indicators for monitoring the welfare of poultry. The prevalence of FPD in turkeys (*Meleagris gallopavo*) throughout Europe is high. Krautwald-Junghanns *et al* (2011) surveyed 66 flocks (11,860 animals in total) in Germany and found a prevalence of 34% in males and 60% in females in the 16th week of life. Allain *et al* (2009) detected severe foot-pad lesions, with a prevalence of 41% in French flocks. In Swedish populations, Berg (1998) found prevalences of 20 and 78% for severe and mild lesions, respectively. She also surveyed Swedish broiler farms and documented a prevalence of 5–10% for severe lesions and 10–35% for mild lesions (Berg 1998). While for broilers (*Gallus gallus domesticus*), FPD is an acknowledged welfare indicator (with 18 states requesting the recording of FPD by national law [Report from the Commission to the European Parliament and the Council 2018]), the evaluation of FPD in turkeys is voluntary. However, the apparent incidence of FPD in turkeys, means comparable regulations regarding turkeys can soon be expected to be adopted (Hocking *et al* 2017).

The absence of legal standards for turkey production throughout Europe (Allain *et al* 2013) means that each country has its own regulations for turkey husbandry, based mostly on recommendations and voluntary actions. In Germany, beyond the regulations of the German Animal Welfare Act (Status 2006, TierSchG) and the German Order on the Protection of Animals and the Keeping of Production Animals (Status 2006, TierSchNutzTV), the ‘National Parameters for Voluntary Agreements for the Keeping of Turkeys’ (Status 2013, German designation: Bundeseinheitliche Eckwerte für eine freiwillige Vereinbarung zur Haltung von Mastputen) serves as a guideline for turkey husbandry (Bergmann *et al* 2013). In this guideline, the evaluation of foot-pad health is a major parameter to ensure adequate animal-keeping. Furthermore, quality assurance programmes require the evaluation of foot-pad health and the provision of feedback to both the farmer and the control organisations when slaughter capacity exceeds 500 animals per hour (QS; Qualität und Sicherheit GmbH, Germany 2019). Therefore, the scoring of FPD is established in most German slaugh-

terhouses, usually embedded in a benchmark system. Monitoring FPD at the slaughterhouse and on-farm is also an accepted tool throughout Europe and the United States (for the UK and US, see Clark *et al* 2002 and for Europe, see Hocking *et al* 2008; Pritchard 2012).

Monitoring such indirect welfare indicators is the first step towards improving awareness and, as a result, the consequences of the management of farmed animals in the long term. The first promising results from Denmark were shown in a study by Kyvsgaard *et al* (2013). They reported that a rapid decline in foot-pad lesions in broilers became obvious in the first three years after the introduction of an action plan to control and monitor FPD at slaughter.

The causes of FPD are reported to be multifactorial, ie genetic, nutritional, and management-related (Shepherd & Fairchild 2010; da Costa *et al* 2014), with wet litter assumed to be the main cause (Martland 1984; Mayne 2005; Mayne *et al* 2007a; El-Wahab *et al* 2011). Therefore, FPD is not only an indicator of animal health but may also be a suitable animal-based indicator for husbandry and environmental conditions (Toppel *et al* 2019).

FPD is described as a contact dermatitis of the plantar surface of birds' feet (Greene *et al* 1985). It is defined by inflammatory processes and skin lesions, which are characterised by brown discolourations on the plantar surface of the metatarsal foot-pad and the toes. These can range from hyperkeratosis (described as a thickening of the epidermis) to necrotic alterations, which might affect the surface and subjacent structures, superficially (erosion) or deeply (ulceration) (Greene *et al* 1985; Martrenchar *et al* 2002).

In turkeys, Hocking *et al* (2008) introduced a standardised system to evaluate the severity of FPD. They proposed the use of a five-step visual score, based on the size of the colour-changed areas on the metatarsal pad.

This scoring system fulfils a whole set of requirements necessary for reliability and validity of scoring systems: scoring systems must be quick and easy to use while reflecting the problem in measurable and assessable categories. Therefore, they must be clearly defined, while repeatability between different classifiers should be possible. The scoring system by Hocking *et al* (2008) fulfils these criteria and is used in most slaughterhouses in Europe to evaluate FPD.

However, visual scoring is generally problematic — superficial assessment is unable to provide information about the subjacent incidents and looking beyond the surface is often a key component of welfare assessment. As described above, FPD can range from relatively mild alterations to severe damage such as erosions or even ulcerations. The occurrence of ulcerations is highly relevant, as they are most likely to induce pain (Martland 1984; Haslam *et al* 2007; Weber Wyneken *et al* 2015), even if there is a current lack of studies providing strong evidence for painfulness in turkeys. In broilers, the occurrence of ulcerations has been included in the Implementary Rules of the Lower Saxonian

Ministry of Nutrition (2015) and also been adapted for other German federal states (Piller *et al* 2020).

Histopathological examinations can help to assess the severity of foot-pad changes with greater scrutiny (Michel *et al* 2012). A number of studies have analysed the effects of wet litter or litter quality on histopathological alterations on the foot-pad (Mayne *et al* 2007a; El-Wahab *et al* 2011; Youssef *et al* 2011). All indicated that wet litter affects both the external (visual) and histopathological severity of FPD. Mayne *et al* (2007a) emphasised that histopathological changes were not always detectable by external (visual) scoring before reproducing their findings in a follow-up study, in which only weak correlations were found between external and histopathological scores (Mayne *et al* 2007b). However, as the histopathological findings were combined in a scoring scheme, no conclusions can be drawn regarding a correlation between external scores and specific histopathological parameters. A study by Piller *et al* (2020) showed comparable results in broilers. While they generally found a relationship between macroscopic scores and histopathological findings, histopathological mild lesions could not easily be assigned to specific visual scoring levels. A recent study by Toppel *et al* (2019) presented the first results comparing macroscopic scoring (by Hocking *et al* 2008) with histological findings. In their discussion, they stated that histological findings were correlated with the macroscopic scoring. However, their sample size comprised ten feet with two feet per scoring level. Therefore, even if it is a good starting point, drawing conclusions from these results might be difficult.

Thus, the presented study aimed to describe, in more detail, the interactions between macroscopic scores and histopathological findings. It addresses three main questions: (i) is a visual scoring system reliable in representing the correct size of alterations on the foot-pad; (ii) are there histopathological patterns, reflecting the categories of a commonly used scoring system to evaluate FPD based on the size of the alteration; and (iii) where would be the threshold to avoid the occurrence of ulcerations? It is our assertion that drawing a link between visually inaccessible pathologies and their superficial expression will improve and validate the application of FPD in turkeys as an animal welfare indicator.

Materials and methods

Study animals

The feet of turkeys (male and/or female animals, BUT 6, Aviagen Turkeys Ltd, UK) were sampled at a German slaughterhouse at the end of the fattening phase. Two different sets of feet were used in this study: a first set was collected in order to calculate observer reliability for the visual scoring (Part 1) and a second was used to analyse the feet in more detail (Part 2). The visual scoring type was referred to as 'visual classification' (VC).

To calculate the observer reliability for the VC (Part 1), 300 pairs of mixed sex feet (200 female bird feet, 400 male)

were used. Feet were sampled from the slaughter-line in random order and scored macroscopically by two observers (research scientists from two different German scientific institutions), using the scoring system described in Table 1. Since both observers were experienced in the assessment of FPD, observer training consisted of a verbal recapitulation of the defined thresholds. Feet from one pair were scored separately at staggered times.

In the second part of this study, male bird feet were sampled in random order from the slaughter-line and scored macroscopically (450 pairs of feet in total). Only the right foot per pair was used for further analysis. Of those, 100 were picked in a pseudo-randomised order, with the criterion of including 20 feet per scoring class into the sample.

Scoring system (Parts 1 and 2)

For the VC, a five-point scoring system was used, adapted from Hocking *et al* (2008) (see Figure 1).

Surface measurements (Part 2)

Photographs were taken with a digital camera (Canon EOS 600D, Krefeld, Germany) and from the images the feet were scored macroscopically. Images were also utilised to measure the percentage of foot-pad surface alterations using ImageJ software (Rasband, WS, ImageJ, US National Institutes of Health, Bethesda, MD, USA; <https://imagej.nih.gov/ij/>, 1997-2018). Therefore, both the metatarsal foot-pad (reference) and the alteration on the foot-pad were tagged using the 'freehand tool' in the software programme. The metatarsal foot-pad was characterised by its kurtosis, with the borders being defined at the start of the curvature. The number of pixels on the surface area of both the reference and alteration was calculated to determine the respective proportion of the altered area compared to the metatarsal foot-pad (relative size of the lesion). All measurements were taken by one observer, repeated three times per picture and the mean values were used for further analysis. Additionally, intra-observer reliability was measured for the complete dataset. Inter-observer reliability was calculated for a random subset of 22 feet.

According to the percentage of the altered area in relation to the reference, these feet were again sorted into respective scoring levels according to the objective of the VC. This classification type was referred to as 'true classification' (TC); see Table 1 for information on the respective percentages.

Histopathology (Part 2)

Tissue was collected from the centre of the largest lesion on each metatarsal foot-pad. Cuts measured approximately 300 × 20 × 7 mm (length × width × height). They were fixed in 10% buffered neutral formalin and embedded in paraffin wax. Cross-sections (3–4 µm thick) were stained using haematoxylin and eosin and observed via light microscopy (Olympus BX53, Waltham, Massachusetts, USA) at 40–400× magnification. Histological analysis was carried out by two experienced pathologists who examined the occurrence and severity grade (mild/moderate/severe) of the different parameters. Both were blinded for the underlying

Table 1 Scoring classes of the visual scoring system (VC).

Scoring level	Definition
0	Intact foot
1	Small, punctual alterations, less than 10% of the foot-pad surface
2	Altered lesion covers less than 25% of the foot-pad surface
3	Altered lesion covers less than 50% of the foot-pad surface
4	Altered lesion covers more than 50% of the foot-pad surface

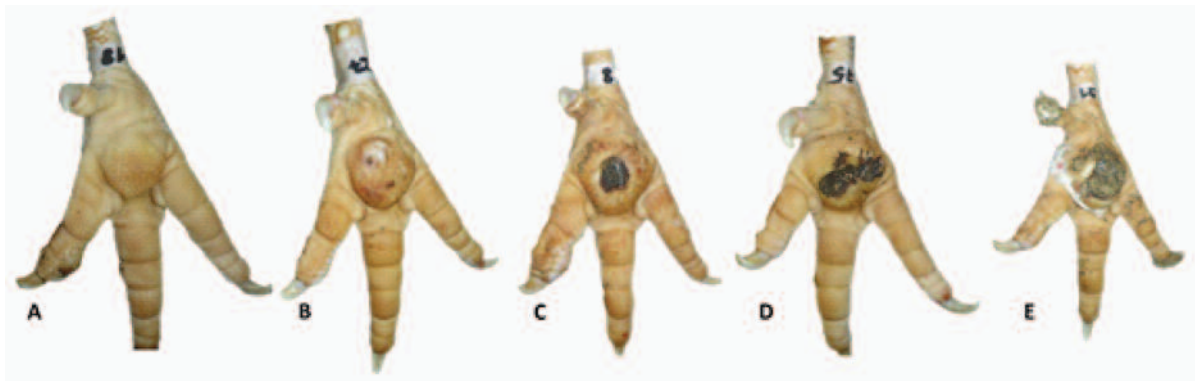
visual score levels and the results of the second observer, respectively. The parameters included hyperkeratosis, erosion and ulceration, re-epithelialised granulation tissue and perivascular pododermatitis (see Figure 2).

Hyperkeratosis was defined as a thickening of the stratum corneum of the epidermis (Freedberg 1993; Mauldin & Peters-Kennedy 2015; Wohlsein *et al* 2015). An erosion was characterised by a superficial epidermal loss with an intact basal membrane (Hargis & Ginn 2009; Mauldin & Peters-Kennedy 2015; Wohlsein *et al* 2015). Ulceration was specified as a complete loss of the epidermis, including the basal membrane and this tends to be associated with an inflammatory reaction termed 'ulcerative dermatitis' (Wohlsein *et al* 2015). Re-epithelialised granulation (or scar) tissue is defined as proliferated fibroblasts with collagenous fibres, both orientated parallel to the surface with blood vessels arranged rectangularly and covered by an overlying squamous epithelium (Hargis & Ginn 2009; Wohlsein *et al* 2015). Perivascular pododermatitis described an inflammatory process of the skin with an infiltration of inflammatory cells around the vessels (Wohlsein *et al* 2015). During evaluation, this parameter was divided into acute and chronic processes, according to the type of inflammatory cells: heterophilic granulocytes and macrophages indicating an acute inflammatory process while infiltration with lymphocytes and plasma cells characterised chronic incidences (Hargis & Ginn 2009; Mauldin & Peters-Kennedy 2015; Wohlsein *et al* 2015). However, for the presented analysis, both were pooled since the acute processes occurred only occasionally.

Severity of grade was evaluated semi-quantitatively (mild/moderate/severe) as based on the estimation and experience of the pathologists. For the semi-quantitative assessment of epidermal hyperplasia and hyperkeratosis, an average of 20 epidermal cell layers and a 1:1 ratio of nuclear-free to nuclear-containing cell layers was deemed clinically unremarkable.

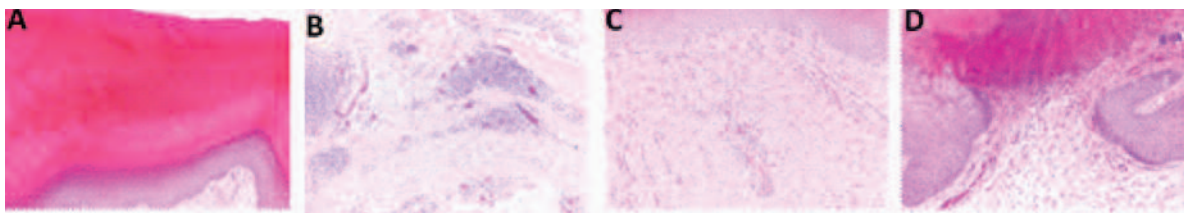
The degree of ulceration was assessed as per the proportion of ulceration in the total area of the slide. Classification of re-epithelialised granulation tissue consisted of simply noting whether or not it was present since the unfeasibility

Figure 1



Visual scoring system (VC) consisting of (A) scoring level 0, (B) scoring level 1, relative size of the lesion: 1.85%, (C) scoring level 2, relative size of the lesion: 18.77%, (D) scoring level 3, relative size of the lesion: 33.75% and (E) scoring level 4, relative size of the lesion: 65.08%. The relative size is calculated as the respective proportion of the altered area compared to the size of the metatarsal foot-pad.

Figure 2



Histological cross-sections (haematoxylin/eosin staining; 2–4 µm thick) showing (A) severe hyperkeratosis with a markedly thickened stratum corneum, (B) severe multifocal pododermatitis with numerous lymphocytes forming perivascular cuffs, (C) re-epithelialised granulation tissue with multiple proliferated blood vessels in a dense, collagenous matrix under an intact epidermis and (D) moderate, chronic ulceration with loss of epidermis, including the basal membrane, accumulation of cellular detritus and granulation tissue formation under the epidermal defect.

of precise differentiation from pre-existing tissue precluded classification in degrees. The infiltration of perivascular inflammatory cells was assessed to be mild in cases with one to three layers of inflammatory cells around a blood vessel, moderate with four to ten cell layers and severe when there was more than ten cell layers. Multiple diagnoses per foot were possible.

Statistical analysis (Parts 1 and 2)

Statistical analyses were performed using SAS/STAT® software (V94, Statistical Analysis Institute, Cary, NC, USA). Observer reliability was calculated using the Krippendorff's alpha with the 'macro' developed by Hayes and Krippendorff (2007). The respective data type (ordinal data for VC; metric data for circumferential measurements) was taken into consideration. Each data set was calculated separately which resulted in values for the inter-observer reliability of the VC, the inter-rater reliability of the surface of the foot-pad and the alteration, and also the intra-observer reliability of the surface of the foot-pad and the alteration. In addition to the Krippendorff's alpha, the prevalence-

adjusted and bias-adjusted kappa (PABAK) was calculated for the comparison of TC and VC.

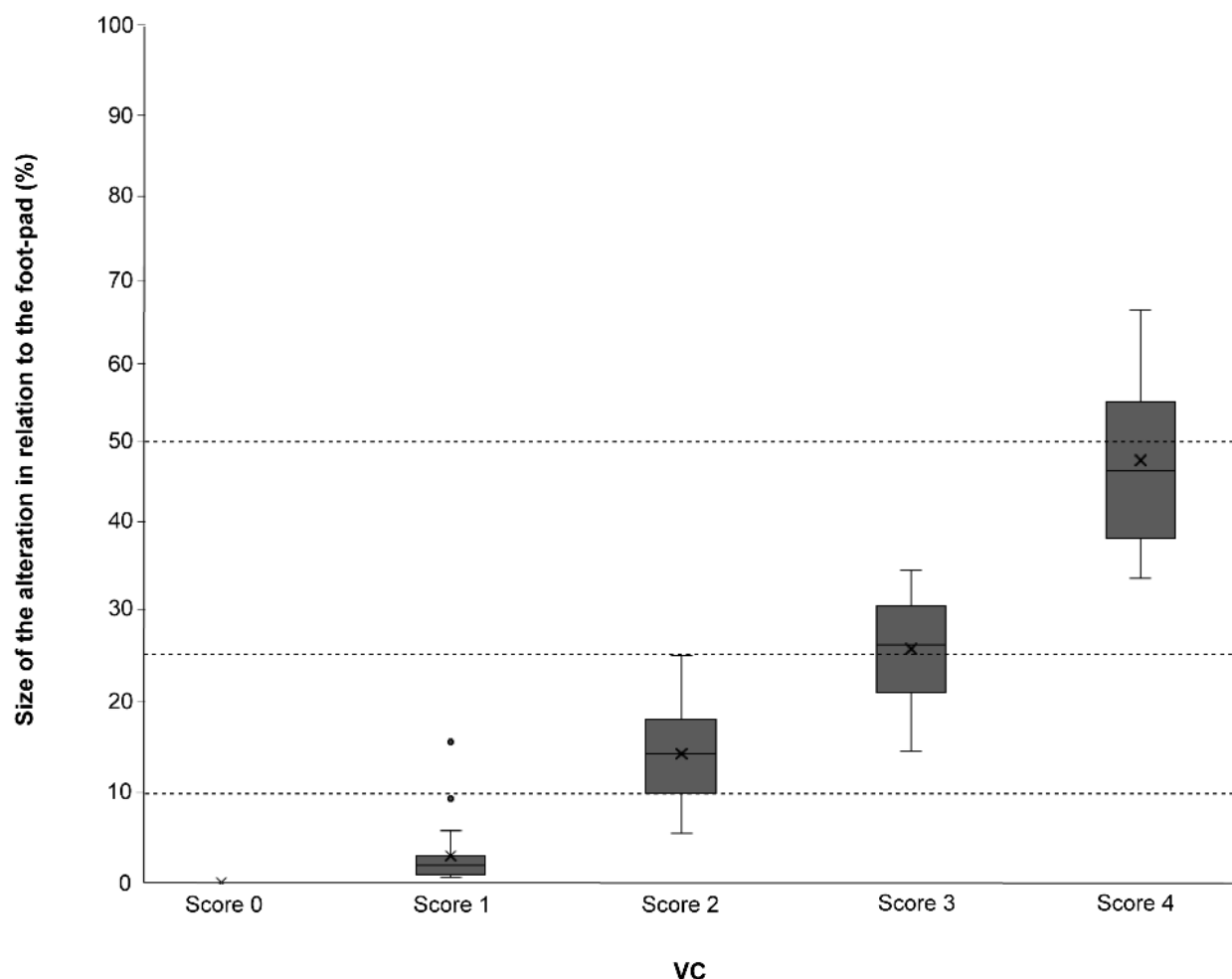
Reliability resulting in Krippendorff's alpha and PABAK, respectively, was valued using the classification proposed by Landis and Koch (1977) (< 0.00 = poor; 0.00–0.20 = slight; 0.21–0.40 = fair; 0.41–0.60 = moderate; 0.61–0.8 = substantial; 0.81–1.00 = almost perfect).

A comparison between VC and TC was carried out descriptively using frequency cross-tables. Agreements between measurements were calculated using the Krippendorff's alpha and the PABAK.

For the analysis of histopathological parameters, a multinomial regression model for each parameter (separately) was used (PROC logistic). To specify the generalised logit function, the link = glogit option was adjusted in the model statement. Predictive probabilities were estimated to describe the relationship between TC and the severity grade of each histopathological parameter.

A generalised mixed model (PROC GLIMMIX) was calculated to analyse the effect of all histopathological parame-

Figure 3



True percentage of alterations on the foot-pad measured by ImageJ software for the visual score (VC). Dotted lines indicate the set threshold levels for the TC (< 10% = Score 1; < 25% = Score 2; < 50% = Score 3; > 50% = Score 4). Data of feet scored by VC are presented as boxplots displaying data range, mean, median, lower and upper quartiles. Outliers are included as dots ($n = 100$).

ters on the percentage of the alteration. Histopathological parameters (occurrence for the re-epithelialised granulation tissue, severity grade for all other parameters) and their two-fold interactions were included as fixed factors, and pairwise comparisons were carried out using Tukey Kramer t -tests. The level of significance was set at $P < 0.05$.

To evaluate cut-off values, a logistic regression was calculated, modelling the outcome of the histopathological results as a dichotomous variable and the percentage of the alteration as a metric variable (PROC logistic, link = logit). The ROC (receiver operating characteristic)-curves and the AUC (area under the ROC curve) were calculated for this model. The ROC-curve results from the specificity and sensitivity of each predictive probability. An ideal diagnostic procedure would result in both having a value of 1. The Youden's Index was calculated for each point on the ROC curve. The maximum value of the index (0–1) is commonly used as a criterion for selecting the optimum cut-off point (Youden 1950).

Results

Observer reliability (Parts 1 and 2)

The calculation of the inter-observer reliability for VC resulted in a Krippendorff's alpha of 0.82. For the surface measurements, the inter-rater reliability analysis revealed Krippendorff's alpha values of 0.81 for the reference and 0.97 for the alteration. Intra-rater reliability calculation resulted in a Krippendorff's alpha of 0.98 for both the reference and the alteration.

Surface measurements (Part 2)

Figure 3 shows the results regarding the percentage of the alteration on the foot-pad for VC. In terms of a comparison of VC and TC, all of the feet in scoring class 0 were valued equally. For scoring class 1, one foot was misclassified by VC; the alteration on this foot-pad showed a value of 15.9%. For scoring class 2, five feet were found to be misclassified by VC, with four of those showing values < 10% and one with a value > 25%. In scoring

Table 2 Agreements between visual classification (VC) and true classification (TC).

TC	VC					Total
	Score 0	Score 1	Score 2	Score 3	Score 4	
Score 0	20	0	0	0	0	20
Score 1	0	19	4	0	0	23
Score 2	0	1	15	7	0	23
Score 3	0	0	1	13	12	26
Score 4	0	0	0	0	8	8
Total	20	20	20	20	20	100

Frequency (%) of feet scored in the individual scoring scales depending on scoring style (VC = five-point scoring system based on the [subjective] evaluation of the size of the lesion; TC = five-point scoring system based on the surface measurement). Scoring levels are based on the size of the alteration (< 10% = Score 1; < 25% = Score 2; < 50% = Score 3; > 50% = Score 4). Coloured scales present the quality of agreements, from perfect agreement in dark grey to partial agreement (difference not more than one scoring level) in (blue).

class 3, seven feet were found to be evaluated incorrectly, with alteration values < 25%. Most misclassifications became obvious in scoring class 4, with 12 feet found to show values < 50% (Figure 3, Table 2).

Comparing VC and TC (including all scoring classes) resulted in a Krippendorff's alpha of 0.94 and a PABAK of 0.69, respectively.

Histopathology: Description of the alteration (Part 2)

Twenty feet were classified within scoring level 0 for the TC, according to the surface measurement. Of those, 100% were found to show hyperkeratosis, with 75.0% revealing a mild form, 15.0% a moderate form, and 10.0% a severe form. Twenty percent of the feet were found to show perivascular pododermatitis, all to a mild degree. Twenty percent of the feet revealed re-epithelialised granulation tissue, whereas two of those were also diagnosed with perivascular pododermatitis. None of those feet were found to show ulcerations. According to calculated probabilities, TC 0 was characterised as having the highest probability of hyperkeratosis of severity grade 1, with all other parameters showing the highest probability of not being observed (Figure 4).

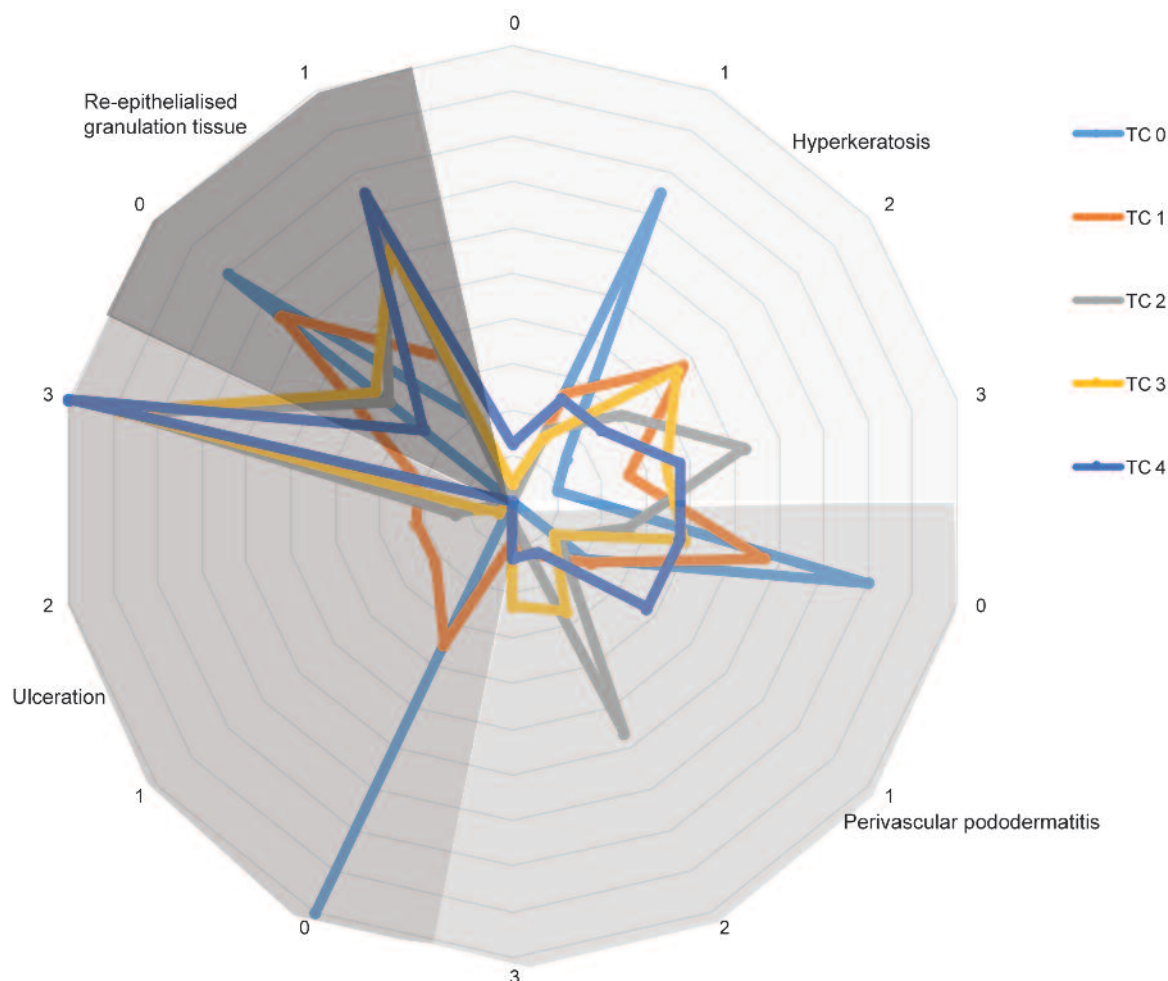
Twenty-three feet belonged in TC level 1 according to the surface measurement. All revealed hyperkeratosis, 26.1% in a mild form, 47.8% in a moderate form, and 26.1% in a severe form. Perivascular pododermatitis was found in 43.4% of those feet, with half of them displaying a mild form, 30.0% a moderate form, and 20.0% a severe form. In 34.8%, re-epithelialised granulation tissue became obvious. Furthermore, 65.1% of the feet showed ulceration, equally separated over the three severity grades. No relationship between the different diagnoses became obvious. According to calculated probabilities, TC 1 was characterised as having the highest probability of hyperkeratosis of a severity grade of 2, with all other parameters showing the highest probability of not being observed (Figure 4).

Scoring level 2 (TC) also comprised 23 feet. Again, all showed hyperkeratosis (17.4% mild, 30.4% moderate and 52.2% severe). A total of 73.8% of the feet were diagnosed with perivascular pododermatitis; of those, 17.6% evinced a mild severity grade, 76.7% a moderate severity grade and 5.7% a severe severity grade. A total of 65.2% of the feet were found to show re-epithelialised granulation tissue and all revealed ulcerations, with 13.0% showing a moderate form and 87.0% a severe form. No relationship between different diagnoses became obvious. Therefore, TC 2 was characterised as having the highest probability of hyperkeratosis of severity grade 3, perivascular pododermatitis of severity grade 2, and the occurrence of re-epithelialised granulation tissue and ulcerations of severity grade 3 (Figure 4).

Scoring level 3 (TC) was found to include 26 feet. All revealed hyperkeratosis, except for one foot; however, here, no epidermis had been left for the assessment. For the feet involved, severity grades ranged from mild (16.0%) to severe (36.0%) and most of the feet were found to show moderate forms (48.0%). Perivascular pododermatitis was observed in 61.5% of the feet (18.7% mild, 43.7% moderate, and 37.6% severe). Re-epithelialised granulation tissue occurred in 61.5% of the feet. Again, all feet revealed ulcerations (3.8% slight, 7.7% moderate, and 88.5% severe). Therefore, TC 3 showed the highest probability of displaying hyperkeratosis of severity grade 2, no multifocal perivascular pododermatitis, the occurrence of re-epithelialised granulation tissue, and ulcerations of severity grade 3 (Figure 4).

Scoring level 4 (TC) comprised eight feet, of which seven were found to show hyperkeratosis, varying as regards severity grade (28.6% mild, 28.6% moderate, and 42.8% severe). However, the leftover foot was found to have no remaining epidermis with which to assess the grade of hyperkeratosis. Perivascular pododermatitis was found in 62.5% of feet (60.0% mild, 20.0% moderate, and 20.0%

Figure 4



Network diagram for different scoring levels of TC and the histopathological parameters for which TC 0 signifies no alteration, TC 1, alteration < 10% of the foot-pad, TC 2, alteration < 25% of the foot-pad, TC 3, alteration < 50% of the foot-pad and TC 4 alteration > 50% of the foot-pad. Hyperkeratosis, perivascular pododermatitis and ulceration are presented by their severity grades (0 = absent, 1 = mild, 2 = moderate, 3 = severe) and re-epithelialised granulation tissue by the occurrence (0 = absent, 1 = present). Scaling shows the percentage of feet diagnosed for the different parameters, with each ring representing 10%.

severe), while granulation tissue occurred in 75.0% of the feet. Again, all were found to show severe ulcerations. Therefore, TC 4 can be characterised as having the greatest probability of showing hyperkeratosis of severity grade 3, no or only mild multifocal perivascular pododermatitis, re-epithelialised granulation tissue, and ulcerations of severity grade 3 (Figure 4).

Erosions were not detected in the presented study. Table 3 provides an overview of the occurrence of the different parameters in the analysed sample size, as well as information on average alteration size.

The severity grade of ulcerations showed a significant effect on the size of the alteration (percentage in relation to the foot-pad) ($F_{3,64} = 14.19$; $P < 0.001$), with the pair-wise comparisons revealing higher values for feet with severe ulceration as compared to the other feet (all $|t| > 3.45$; all $P < 0.01$) and feet

with moderate ulcerations as compared to feet showing no signs of ulcerations ($|t| = 2.73$; $P < 0.05$) (Figure 5).

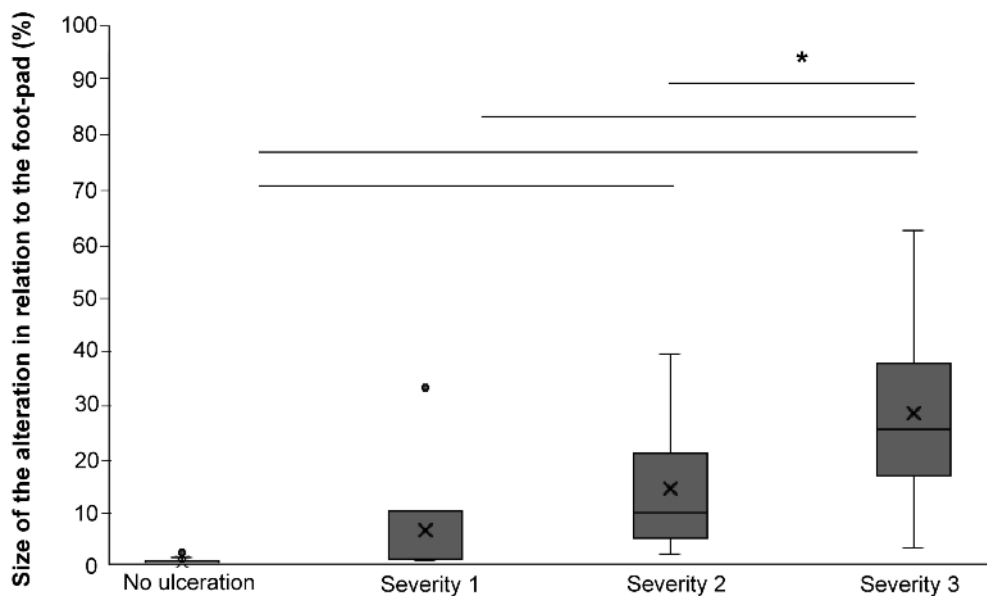
The severity grade of hyperkeratosis was also found to have a significant effect on the size of the alteration ($F_{3,64} = 2.95$; $P < 0.05$), with the pair-wise comparisons revealing this effect to be due to higher levels in feet that were not found to show hyperkeratosis compared to those showing a severity level of 2 or 3 (all $|t| > 2.87$; all $P < 0.05$).

Both the severity of perivascular pododermatitis and the occurrence of re-epithelialised granulation tissue had no effect on the relative size of the alteration (perivascular pododermatitis: $F_{3,64} = 1.45$; $P = 0.1$; re-epithelialised granulation tissue: $F_{1,64} = 0.64$; $P = 0.2$).

No effect of the interaction between parameters could be found either (all $F > 0.5$; all $P > 0.05$).

Table 3 Descriptive analysis of the histopathological parameters for the analysed dataset (n = 100).

Parameter	Severity grade	Percentage of feet (%)	Mean (\pm SD) size of the alteration (%)	Min–Max (%)
Hyperkeratosis	Absence	2	53.9 (\pm 11.7)	45.7–62.2
	Mild	31	11.8 (\pm 19.1)	0–65.0
	Moderate	35	18.4 (\pm 16.1)	0–51.7
	Severe	32	22.7 (\pm 17.4)	0–65.1
Perivascular pododermatitis	Absence	48	14.7 (\pm 19.5)	0–65.1
	Mild	18	18.6 (\pm 21.2)	0–65.0
	Moderate	24	20.6 (\pm 12.5)	1.0–51.7
	Severe	10	31.3 (\pm 16.0)	8.8–54.8
Ulceration	Absence	28	0.4 (\pm 0.8)	0–2.7
	Mild	6	6.7 (\pm 13.6)	0.5–34.5
	Moderate	10	14.6 (\pm 13.4)	1.8–41.0
	Severe	56	29.4 (\pm 16.2)	3.1–65.1
Re-epithelialised granulation tissue	Absence	51	12.9 (\pm 17.2)	0–62.2
	Presence	49	24.2 (\pm 18.2)	0–65.1

Figure 5

Size of the alteration for different severity grades of ulceration. Data are presented as boxplots displaying data range, mean, median, lower and upper quartile. Outlier is included as a dot. * $P < 0.05$; (n = 100).

Cut-off values and resulting performance data

The AUC of the calculated ROC curves was found to be highest for the occurrence of ulcerations (0.98) and hyperkeratosis (0.94), whereas the AUC for multifocal perivascular pododermatitis and the occurrence of re-epithelialised granulation tissue was found to

be lower (0.67 and 0.70, respectively).

Potential cut-off values based on the occurrence of ulcerations are shown in Table 4, which presents values for sensitivity, specificity, and the Youden's Index. The maximum Youden's Index (0.90) was found at an alteration covering 3.1% of the foot-pad.

Discussion

Foot-pad dermatitis is one of the most important animal welfare indicators in turkeys to date, with severity measured according to the size of the alteration on the foot-pad.

According to the classification values proposed by Landis and Koch (1977), the observer reliabilities found in this study can be considered “almost perfect.” Therefore, the VC was deemed an objective method for further use throughout the study. However, both observers in this study were trained in scoring foot-pad dermatitis. This must be borne in mind when one is applying visual systems in practical contexts, as visual scoring is vulnerable to a high subjective error, depending on the observer and the appropriate situation (Meagher 2009; Heitmann *et al* 2018). Particularly when the size of circular structures are being assessed, the observer is exposed to a set of optical illusions that can bias the ratings — for instance, phenomena such as the Ebbinghaus syndrome (ie, perception of size depending on the surrounding conditions) (Axelrod *et al* 2017). This might have an effect when the feet of female and male birds are being evaluated, since foot-pad size differs between the sexes. No differences in observer reliability between sex of the feet were found here (results not presented); however, the size of the foot-pad could affect the performance of the observer. The quality of evaluation also depends on the affective context of the observation, as described in van Ulzen *et al* (2008). The results of the presented study confirm the difficulty of accurately assessing the size of a lesion using a visual score. Most deviations of the real size (TC) were found for scoring levels 3 and 4. The discrepancies we found in the more severe scoring levels may reflect the findings of van Ulzen *et al* (2008) who proposed that circles with a negative affective impact may be perceived as larger than circles with a positive loading. In Germany, this is partly implemented in the health control programme within the National Parameters for Voluntary Agreements for the Keeping of Turkeys (2013), condensing the five-point score to a three-point score by combining scoring classes 0 and 1 and 3 and 4.

However, despite the high number of deviations between both classification types, comparing VC with TC resulted in good reliability according to the Krippendorff’s alpha. This can be explained by the character of the Krippendorff’s alpha, which also takes into account the degree of discrepancies, meaning that if the given score levels differ only slightly (eg by one scoring level), the result would turn out better than if the score-level difference was more pronounced (eg more than one scoring level) (Krippendorff 2011). The PABAK, a reliability coefficient, which considers only perfect agreements, resulted in a reliability of 0.69. It might be more suitable to reflect the missing concordance between classification types when setting the criteria more stringently (ie expecting perfect agreement). However, according to the classification values proposed by Landis and Koch (1977), this result can still be considered substantial. In conclusion, the scoring system seems to be suitable for reliably representing the size of the foot-pad alteration. Using the VC as a scoring system to improve

Table 4 Cut-off values for the occurrence of ulcerations.

Size of the lesion (%)	Sensitivity (%)	Specificity (%)	Youden’s Index
16.0	68	100	0.68
14.9	71	100	0.71
14.2	72	100	0.72
13.3	74	100	0.74
11.6	75	100	0.75
10.8	76	100	0.76
10.4	78	100	0.78
10.1	79	100	0.79
9.5	81	100	0.81
9.4	82	100	0.82
8.8	83	100	0.83
8.7	85	100	0.85
6.0	86	100	0.86
5.6	88	100	0.88
4.1	89	100	0.89
3.1	90	100	0.90
2.7	90	96	0.87
2.5	90	93	0.83
2.3	92	93	0.85
2.2	92	89	0.81
2.2	93	89	0.82
1.8	94	89	0.84
1.4	94	86	0.80
1.2	94	82	0.77
1.1	96	82	0.78
1.0	97	82	0.79
0.9	99	82	0.81
0.7	99	79	0.77
0.7	99	75	0.74
0.6	98	71	0.70
0.5	100	71	0.71
0	100	0	0

The Youden’s Index, sensitivity (%) and specificity (%) were calculated for different sizes of the alteration (%) in relation to the foot-pad. Blue markings highlight the sensitivities and specificities > 80%, dark grey signifies the maximum Youden’s Index.

foot-pad health in turkey husbandry (eg as a benchmark system), therefore, seems to work perfectly well.

However, as well as being objective, repeatable, and reliable (Hocking *et al* 2008), classification systems also require a high degree of validity. This means they must ensure that they reflect the problem/disease as well as possible, especially as such systems are required to withstand economic competition (Lund *et al* 2017; van Harn & de Jong 2017). This might be especially relevant when the VC is used not only to improve — but to also indicate — welfare in turkeys.

Therefore, the present study aimed to examine the underlying pathology in more detail by histopathological analysis. We hypothesised that severity in the histological findings would increase with an increasing size of the alteration. This hypothesis was not confirmed for all of the measured parameters in their entirety, as no clear pattern was found for the scoring classes of TC. However, in assessing the various parameters separately, different features became obvious.

First of all, none of the feet analysed in this study appeared to be intact. At the very least there was evidence of hyperkeratosis in the histopathological findings. Hyperkeratosis — described as thickening of the stratum corneum of the epidermis, resulting in a thickened layer of underdeveloped keratin — is said to result from a permanent irritation of the epidermal surface in response to an external trauma (Shepherd & Fairchild 2010). Even if it might be of minor clinical relevance, hyperkeratosis, albeit a severe case, might be considered pathological. With regard to the European Convention for the Protection of Animals kept for Farming Purposes (Article 7- [...] avoid unnecessary suffering [...]) and the concept of the Five Freedoms (freedom from pain, injury and disease) (Farm Animal Welfare Committee [FAWC] 2009), one could argue that the occurrence of hyperkeratosis should be avoided. However, hyperplasia of the stratum corneum can also be considered a physiological adaptation process. Bearing in mind the weight of the animals, as well as the time of the fattening period, the occurrence of hyperkeratosis might be a protective (and normal) response to the external mechanical stresses to which the animals are exposed, as it would be in humans (Hashmi *et al* 2015). Here, the occurrence of different types of hyperkeratotic processes is reported to result in different degrees of severity with regards to pain (Freeman 2002). In terms of animal welfare, the impact of the occurrence of hyperkeratosis, therefore, must be considered carefully. It would be interesting if comparative studies were conducted with non-domesticated turkeys to reflect the physiological state of turkeys' feet. However, in conjunction with other parameters, the occurrence of hyperkeratosis should be noteworthy, even if no clear linking patterns between parameters could be revealed in the presented study.

Perivascular pododermatitis also occurred in all scoring levels, with it being most pronounced in scoring level 2 and displaying a high probability of a moderate severity grade. Bacterial infections and blunt trauma can cause heterophilic

perivascular pododermatitis, with the presence of heterophilic granulocytes being referred to as an acute process (McGavin & Zachary 2006). On the other hand, lymphocytic perivascular pododermatitis refers mainly to chronic processes. We did not distinguish between both types in this study; however, most of the observed incidents seemed to show an infiltration of lymphocytes, which describes a rather chronic process. Also, re-epithelialised granulation tissue was found in all scoring classes, showing the greatest probabilities in the higher levels (≥ 2). To date, the granulation tissue is not included in the visual scoring schemes used. Even if it might not be relevant to evaluate an acute disease, the granulation tissue might be a valuable indicator to draw retrospective conclusions about the foot-pad health during the entire period of husbandry (Michel *et al* 2012). The formation of granulation tissue is essentially involved in wound healing in poultry (Chen *et al* 2016). It might, therefore, provide indirect evidence of old injuries and, furthermore, reveal aspects of the chronology of the injury period. In chickens, the re-epithelialisation of wounds in the skin starts after three days (Katiyar *et al* 1992). However, the healing process may be influenced by ongoing exposure to the noxae and poorly definable individual influences, including the reactivity of the immune system. As yet, there have been no studies describing wound healing in turkeys' foot-pads. Therefore, re-epithelialisation tissue can be an indicator of either chronic processes during the fattening period (Klambeck *et al* 2019) or a more positive development, caused, for example, by a change in the environment or litter management during husbandry. However, both parameters (perivascular pododermatitis and the re-epithelialised granulation tissue) were not found to affect the size of the alteration. Furthermore, they revealed low AUC values, which is an indicator of the quality of a classifier in regression models. Comparable results were found in a similar study examining the feet of Pekin ducks (*Anas platyrhynchos domesticus*), revealing only weak correlations between perivascular pododermatitis, re-epithelialised granulation tissue, and the size of the lesion (Klambeck *et al* 2019).

By contrast, the severity grade of the ulceration was found to significantly affect the size of the alteration. The occurrence of this parameter resulted in high AUC values, indicating this parameter to be a good classifier for the size of the foot-pad alteration. Equivalent effects were found for the parameter of hyperkeratosis, indicating a decrease in severity grade with an increase in the size of the alteration. However, these latter results can perhaps be overlooked, since they are almost certainly a result of our method of sample collection. Histopathological tissue for analysis was collected from the centre of the lesion; therefore, the bigger the size, the smaller the amount of the epidermis remaining in the individual slide (ie there were two feet in scoring levels 3 and 4, neither of which revealed hyperkeratosis but also with no remaining intact epidermis to measure this parameter).

However, the occurrence and severity grades of ulcerations seem good classifiers for the size of the lesion (or *vice versa*), with there being higher severity grades relative to increases in

alteration size. AUC value, commonly used to discriminate between patients with or without disease, also indicated an excellent diagnostic quality of this parameter (Svets 1988). This confirms the results of Toppel *et al* (2019). Similar results were also found in broiler chickens (Heitmann *et al* 2018; Piller *et al* 2020), with both these studies finding a correlation between ulceration occurrence and increasing lesion size.

Still, it must be noted that no difference was found between scoring levels 2–4 in regard to the occurrence and severity of ulcerations, with all scoring classes showing an equally high probability of severe incidents. The majority of severe ulcerations were found in feet showing an altered size of between 17 and 39%. Therefore, using the scoring system presented would restrict the informative value of a link between ulceration severity and the size of the alteration within scoring classes 0–2. Adjusting the cut-off points between scoring levels would enable the scoring system to provide a more valid reflection of these incidents.

Especially with regard to animal welfare, ulcerations are of high importance, since they are often considered painful, certainly in mammals (for a review in pigs [*Sus scrofa*], see Ison *et al* 2016). Gentle *et al* (2001) showed that chickens dispose of A-delta mechanothermal afferent units (AMT fibres) in the skin of the legs. The researchers concluded that the presence of such AMT fibres implied that birds experience pain rather than showing simple nociceptive responses. Even if this has yet to be proven in turkeys, various studies have indicated a perception of pain and, more precisely, a link with this and FPD in turkeys, also. For example, Hocking and Wu (2013) and Weber Wyneken *et al* (2015) drew indirect conclusions regarding the painfulness of FPD by measuring impaired gait and decreased activity in turkeys. Comparable results were found in broiler chickens whereby McKeegan (2010) found a link between slower movement and the occurrence of FPD, which could be altered via analgesia. Martland (1985) found an interrelation between FPD and an impaired growth rate, which he concluded to be a result of pain-induced inappetence. However, studies into impaired gait are the subject of growing scrutiny since other causes, such as femoral head necrosis (Dinev 2009; Packialakshmi *et al* 2015) and osteomyelitis (Wyers *et al* 1991) are increasingly common in fast-growing poultry. Furthermore, as yet, there have been no studies showing a direct link between different pathologies (eg varying severity grades of ulceration) and specific pain levels or subjective experiences. As a result, there remains a lack of clear evidence on the impact of FPD on animal welfare. Nevertheless, there seems a general acceptance that, until scientific research manages to find evidence for the perception of pain due to FPD in poultry, the prevention of ulcerations should be a goal, especially when FPD is used as an indicator for animal welfare (Ekstrand *et al* 1997; Algers & Berg 2001; Louton *et al* 2020; Piller *et al* 2020). The calculated cut-off values point out that even very small lesions should be taken into account for the avoidance of ulcerations. Youden's Index is a commonly used tool for setting thresholds in diagnostic tests (Youden 1950) based on the sensitivity and specificity of each data-point in the ROC curve. The maximum Youden's Index (0.90) was found at an

altered area of 3.1%. Youden's Index rates both sensitivity (percentage of affected feet correctly identified as showing an ulceration) and specificity (percentage of unaffected feet correctly identified as not showing an ulceration) as equally important. However, even if one accepts the sensitivity for ulceration detection to be as low as 68%, the size of the alteration would be low (16% of the foot-pad). An interesting aspect through which to gain further insight into the development of FPD would be to measure the depth of ulcerations, as was proposed by Große Beilage *et al* (2019), in regard to pain in pigs. However, for now, this appears impossible in turkeys since the development of granulation tissue over the long fattening period blurs the edges of the damage, making it impossible to set adequate reference points indicating the healthy epidermis.

Animal welfare implications

The present study can contribute to improve a standard scoring system for the evaluation of FPD in turkeys. Taking into account our results, discussion should be undertaken regarding the use of FPD as a welfare indicator, especially concerning the set thresholds in the present scoring system and the inclusion of other parameters, such as the occurrence of re-epithelialised granulation tissue.

Looking to the future and the rapid development of automated methods, this might be an opportunity to enhance the quality of FPD evaluation. A basis for such discussions would be further research focusing on the perception of pain in turkeys. Furthermore, future studies should be used to assess the impact of potential refinements on the prevalence of FPD in turkeys in general.

Conclusion

To conclude, the presented results showed the visual score to be reliable in representing the dimension of the alteration. Particularly when implemented as a benchmark, the visual score is effective at sensitising owners to the health status of their animals and to improve food-pad health. However, when FPD is used as an indicator of animal welfare, the classification that's currently in use may have to be more stringent. Our findings suggest that small lesions, as found in VC 1 and 2, were already characterised as ulcerations. Therefore, a refinement of the visual scoring system might be necessary until further research concerning the painfulness of those pathologies can define their role with regard to animal welfare.

Acknowledgements

This study was conducted within the project 'Autowohl: Automatic detection of animal welfare indicators.' The project was supported by funds from the Federal Ministry of Food and Agriculture (BMEL) based on a decision from the Parliament of the Federal Republic of Germany via the Federal Office for Agriculture and Food (BLE) under the innovation support programme. The authors wish to thank everyone involved in this study, especially Walter Wagner and Harald Ulbrich for their help during the practical performance, Dr Ronald Günther for very helpful comments and Rebekka Melloh for editing the pictures of foot-pads. We would also like to thank the reviewers for their suggestions.

References

- Algers B and Berg C** 2001 Monitoring animal welfare on commercial broiler farms in Sweden. *Acta Agriculturae Scandinavica, Section A-Animal Science* 51(30): 88-92. <https://doi.org/10.1080/090647001316923135>
- Allain V, Huonnic D, Rouina M and Michel V** 2013 Prevalence of skin lesions in turkeys at slaughter. *British Poultry Science* 54(1): 33-41. <https://doi.org/10.1080/00071668.2013.764397>
- Allain V, Mirabito L, Arnould C, Colas M, Le Bouquin S, Lupo C and Michel V** 2009 Skin lesions in broiler chickens measured at the slaughterhouse: Relationships between lesions and between their prevalence and rearing factors. *British Poultry Science* 50: 407-417. <https://doi.org/10.1080/00071660903110901>
- Axelrod V, Schwarzkopf DS, Gilaie-Dotan S and Rees G** 2017 Perceptual similarity and the neural correlates of geometrical illusions in human brain structure. *Scientific Reports* 7(1): 1-16. <https://doi.org/10.1038/srep39968>
- Berg CC** 1998 Foot-pad dermatitis in broilers and turkeys. *Acta Universitatis Agriculturae Sueciae Veterinaria, Volume 36*: 26-27
- Bergmann S, Ziegler N, Bartels T, Hübel J, Schumacher C, Rauch E, Brandl S, Bender A, Casalicchio G, Krautwald-Junghanns ME and Erhard MH** 2013 Prevalence and severity of foot pad alterations in German turkey poults during the early rearing phase. *Poultry Science* 92(5): 1171-1176. <https://doi.org/10.3382/ps.2012-02851>
- Chen J, Guillermo T and Escobar J** 2016 Identification of biomarkers for footpad dermatitis development and wound healing. *Frontiers in Cellular and Infection Microbiology* 6: 26. <https://doi.org/10.3389/fcimb.2016.00026>
- Clark S, Hansen G, McLean P, Bond Jr P, Wakeman W, Meadows R and Buda S** 2002 Pododermatitis in turkeys. *Avian Diseases* 46(4): 1038-1044. [https://doi.org/10.1637/0005-2086\(2002\)046\[1038:PIT\]2.0.CO;2](https://doi.org/10.1637/0005-2086(2002)046[1038:PIT]2.0.CO;2)
- Da Costa MJ, Grimes JL, Oviedo-Rondón EO, Barasch I, Evans C, Dalmagro M and Nixon J** 2014 Footpad dermatitis severity on turkey flocks and correlations with locomotion, litter conditions, and body weight at market age. *Applied Poultry Research* 23: 268-279. <https://doi.org/10.3382/japr.2013-00848>
- Dinev I** 2009 Clinical and morphological investigations on the prevalence of lameness associated with femoral head necrosis in broilers. *British Poultry Science* 50: 284-290. <https://doi.org/10.1080/00071660902942783>
- Ekstrand C, Algers B and Svedberg J** 1997 Rearing conditions and foot-pad dermatitis in Swedish broiler chickens. *Preventive Veterinary Medicine* 31: 167-174. [https://doi.org/10.1016/S0167-5877\(96\)01145-2](https://doi.org/10.1016/S0167-5877(96)01145-2)
- Ei-Wahab AA, Beineke A, Beyerbach M, Visscher CF and Kamphues J** 2011 Effects of floor heating and litter quality on the development and severity of foot pad dermatitis in young turkeys. *Avian Diseases* 55(3): 429-434. <https://doi.org/10.1637/9684-021011-Reg.1>
- European Convention for the Protection of Animals kept for Farming Purposes** 1976 <https://www.coe.int/en/web/conventions/full-list/-/conventions/treaty/087>
- Farm Animal Welfare Council (FAWC)** 2009 *Farm Animal Welfare in Great Britain: Past, Present and Future*. <http://www.fawc.org.uk>
- Freedberg IM** 1993 Keratin: a journey of three decades. *The Journal of Dermatology* 20(6): 321-328. <https://doi.org/10.1111/j.1346-8138.1993.tb01293.x>
- Freeman DB** 2002 Corns and calluses resulting from mechanical hyperkeratosis. *American Family Physician* 65(11): 2277
- Gentle MJ, Tilston V and McKeegan DEF** 2001 Mechano-thermal nociceptors in the scaly skin of the chicken leg. *Neuroscience* 106: 643-652. [https://doi.org/10.1016/S0306-4522\(01\)00318-9](https://doi.org/10.1016/S0306-4522(01)00318-9)
- German Animal Welfare Act** 2006 *Amended and promulgated on May 18th, 2006, last changed on June 19th, 2020. Tierschutzgesetz in der Fassung der Bekanntmachung vom 18 Mai 2006 (BGBl I S 1206, 1313), das zuletzt durch Artikel 101 des Gesetzes vom 19 Juni 2020 (BGBl I S 1626) geändert worden ist*. <https://www.gesetze-im-internet.de/tierschg/BjNR012770972.html>
- German Order on the Protection of Animals and the Keeping of Production Animals** 2006 *Amended and promulgated on August 22nd, 2006, last changed on June 30th, 2017. Verordnung zum Schutz landwirtschaftlicher Nutztiere und anderer zur Erzeugung tierischer Produkte gehaltener Tiere bei ihrer Haltung; Tierschutz-Nutztierhaltungsverordnung (TierSchNutzV) in der Fassung der Bekanntmachung vom 22 August 2006 (BGBl I S 2043), die durch Artikel 1 der Verordnung vom 30 Juni 2017 (BGBl I S 94) geändert worden ist*. <https://www.gesetze-im-internet.de/tierschnutzv/BjNR275800001.html>
- Greene JA, McCracken RM and Evans RT** 1985 A contact dermatitis of broilers: clinical and pathological findings. *Avian Pathology* 14: 23-38. <https://doi.org/10.1080/03079458508436205>
- Große Beilage E, Meyer D, Hewicker-Trautwein M, Hartmann M and Kreienbrock L** 2019 Schulterulzera bei Sauen – Entwicklung eines Klassifizierungsschemas für die tierärztliche Bewertung am lebenden Tier. *Proceedings of the 25th Internationale DVG-Fachtagung zum Thema Tierschutz und 1 Internationale Fachtagung zum Thema Ethologie und Tierhaltung* pp 133-138. 14-16 March 2019, Munich, Germany. Deutsche Veterinärmedizinische Gesellschaft EV DVG-Fachgruppe Tierschutz: Gießen, Germany. [Title translation: Shoulder ulcers in sows. Development of a classification scheme for animal welfare assessment in live animals]
- Hargis AM and Ginn PE** 2009 Haut. In: McGavin MD and Zachary JF (eds) *Pathologie der Haustiere* pp 991-1132. Elsevier GmbH: Munich, Germany. [Title translation: Pet pathology]
- Hashmi F, Nester C, Wright C, Newton V and Lam S** 2015 Characterising the biophysical properties of normal and hyperkeratotic foot skin. *Journal of Foot and Ankle Research* 8(1): 35. <https://doi.org/10.1186/s13047-015-0092-7>
- Haslam SM, Knowles TG, Brown SN, Wilkins LJ, Kestin SC, Warriss PD and Nicol CJ** 2007 Factors affecting the prevalence of foot pad dermatitis, hock burn and breast burn in broiler chicken. *British Poultry Science* 48: 264-275. <https://doi.org/10.1080/00071660701371341>
- Hayes AF and Krippendorff K** 2007 Answering the call for a standard reliability measure for coding data. *Communication Methods and Measure* 1: 77-89. <https://doi.org/10.1080/19312450709336664>
- Heitmann S, Stracke J, Petersen H, Spindler B and Kemper N** 2018 First approach validating a scoring system for foot-pad dermatitis in broiler chickens developed for application in practice. *Preventive Veterinary Medicine* 154: 63-70. <https://doi.org/10.1016/j.prevetmed.2018.03.013>

- Hocking PM, Harkness A, Veldkamp T and Vinco LJ** 2017 Do foot pad scores measure turkey welfare? *Proceedings of the 11th Turkey Science and Production Conference* pp 20-23. 9-10 March 2017, Chester, UK
- Hocking PM, Mayne RK, Else RW, French NA and Gatcliffe J** 2008 Standard European footpad dermatitis scoring system for use in turkey processing plants. *World Poultry Science Journal* 64: 323-328. <https://doi.org/10.1017/S0043933908000068>
- Hocking PM and Wu K** 2013 Traditional and commercial turkeys show similar susceptibility to foot pad dermatitis and behavioural evidence of pain. *British Poultry Science* 54: 281-288. <https://doi.org/10.1080/00071668.2013.781265>
- Implementary Rules of the Lower Saxonian Ministry of Nutrition** 2015 *Agriculture and consumer protection for §20 (4; 5). Latest Edition: 31 July 2015, from the German Order on the Protection of Animals and the Keeping of Production Animals (2006)*. http://www.nds-vorvoris.de/jportal/portal/t/ji3/page/bsvorisprod.psm;jsessionid=8F93DE217C1A385FC1EBBE0F60477.jp27?pid=Dokumentanzeige&show-doccase=1&js_peid=Trefferliste&documentnumber=1&numberofresults=1&fromdoctodoc=yes&doc.id=VVND-VVND000035929#focuspoint
- Ison SH, Clutton RE, Di Giminiani P and Rutherford K** 2016 A review of pain assessment in pigs. *Frontiers in Veterinary Science* 3: 108. <https://doi.org/10.3389/fvets.2016.00108>
- Katiyar AK, Vegad JL and Awadhiya RP** 1992 Pathology of inflammatory-reparative response in punched wounds of the chicken skin. *Avian Pathology* 21(3): 471-480. <https://doi.org/10.1080/03079459208418865>
- Klambeck L, Stracke J, Spindler B, Klotz D, Wohlsein P, Schoen HG, Kaufmann F, Kemper K and Andersson R** 2019 First approach to validate a scoring system to assess footpad dermatitis in Pekin ducks. *European Poultry Science* 83. <https://www.european-poultry-science.com/First-approach-to-validate-a-scoring-system-to-assess-footpad-dermatitis-in-Pekin-ducks,QUIEPTYwODMzOTMmTUIEPTe2MTAxNA.html>
- Krautwald-Junghanns ME, Ellerich R, Mitterer-Istyagin H, Ludewig M, Fehlhaber K, Schuster E, Berk J, Petermann S and Bartels T** 2011 Examinations on the prevalence of footpad lesions and breast skin lesions in British United Turkeys Big 6 fattening turkeys in Germany. Part I: Prevalence of footpad lesions. *Poultry Science* 90(3): 555-560. <https://doi.org/10.3382/ps.2010-01046>
- Krippendorff K** 2011 *Computing Krippendorff's alpha-reliability*. http://repository.upenn.edu/asc_papers/43
- Kyvsgaard NC, Jensen HB, Ambrosen T and Toft N** 2013 Temporal changes and risk factors for foot-pad dermatitis in Danish broilers. *Poultry Science* 92: 26-32. <https://doi.org/10.3382/ps.2012-02433>
- Landis JR and Koch GG** 1977 The measurement of observer agreement for categorical data. *Biometrics* 33: 159-174. <https://doi.org/10.2307/2529310>
- Louton H, Piller A, Bergmann S, Erhard M, Stracke J, Spindler B, Kemper N, Schmidt P, Schade B, Boehm B, Kappe E, Bachmeier J and Schwarzer A** 2020 Histologically validated scoring system for the assessment of hock burn in broilers. *Avian Pathology* 49(3): 230-242. <https://doi.org/10.1080/03079457.2020.1712328>
- Lund VP, Nielsen LR, Oliveira ARS and Christensen JP** 2017 Evaluation of the Danish footpad lesion surveillance in conventional and organic broilers: Misclassification of scoring. *Poultry Science* 96: 2018-2028. <https://doi.org/10.3382/ps/pex024>
- Martland MF** 1984 Wet litter as a cause of plantar pododermatitis, leading to foot ulceration and lameness in fattening turkeys. *Avian Pathology* 13: 241-252. <https://doi.org/10.1080/03079458408418528>
- Martland MF** 1985 Ulcerative dermatitis in broiler chickens: The effects of wet litter. *Avian Pathology* 14: 353-364. <https://doi.org/10.1080/03079458508436237>
- Martrenchar A, Boilletot E, Huonnic D and Pol F** 2002 Risk factors for foot-pad dermatitis in chicken and turkey broilers in France. *Preventive Veterinary Medicine* 52: 213-226. [https://doi.org/10.1016/S0167-5877\(01\)00259-8](https://doi.org/10.1016/S0167-5877(01)00259-8)
- Mauldin EA and Peters-Kennedy J** 2015 Integumentary system. In: Maxie G (ed) *Jubb, Kennedy and Palmer's Pathology of Domestic Animals, 6th Edition, Volume 1* pp 509-736. Elsevier: St Louis, Missouri, US. <https://doi.org/10.1016/B978-0-7020-5317-7.00006-0>
- Mayne RK** 2005 A review of the aetiology and possible causative factors of footpad dermatitis in growing turkeys and broilers. *World's Poultry Science Journal* 61: 256-267. <https://doi.org/10.1079/WPS200458>
- Mayne RK, Else RW and Hocking PM** 2007a High litter moisture alone is sufficient to cause footpad dermatitis in growing turkeys. *British Poultry Science* 48: 538-545. <https://doi.org/10.1080/00071660701573045>
- Mayne RK, Else RW and Hocking PM** 2007b High dietary concentrations of biotin did not prevent foot pad dermatitis in growing turkeys and external scores were poor indicators of histopathological lesions. *British Poultry Science* 48(3): 291-298. <https://doi.org/10.1080/00071660701370509>
- McGavin MD and Zachary JF** 2006 *Pathologic Basis of Veterinary Disease*. Elsevier Health Sciences: University of Illinois, Urbana, Illinois, US
- McKeegan D** 2010 *Foot pad dermatitis and hock burn in broilers: Risk factors, aetiology and welfare consequences*. Research Project Final Report, Faculty of Veterinary Medicine, University of Glasgow, UK. <http://randd.defra.gov.uk/Default.aspx?Menu=Menu&Module=More&Location=None&Completed=0&ProjectID=14546>
- Meagher RK** 2009 Observer ratings: validity and value as a tool for animal welfare research. *Applied Animal Behaviour Science* 119: 1-14. <https://doi.org/10.1016/j.applanim.2009.02.026>
- Michel V, Prampart E, Mirabito L, Allain V, Arnould C, Huonnic D, Le Bouquin S and Albaric O** 2012 Histologically validated footpad dermatitis scoring system for use in chicken processing plants. *British Poultry Science* 53: 275-281. <https://doi.org/10.1080/00071668.2012.695336>
- National Parameters for Voluntary Agreements for the Keeping of Turkeys** 2013 *German designation: Bundeseinheitliche Eckwerte für eine freiwillige Vereinbarung zur Haltung von Mastputen, Verband Deutscher Putenerzeuger*. https://www.bmel.de/SharedDocs/Downloads/DE/_Tiere/Tierschutz/ZDG-Eckwerte-Haltung-Mastputen.html
- Packialakshmi B, Rath NC, Huff WE and Huff GE** 2015 Poultry femoral head separation and necrosis: A review. *Avian Diseases* 59: 349-354. <https://doi.org/10.1637/11082-040715-Review.1>

- Piller A, Bergmann S, Schwarzer A, Erhard M, Stracke J, Spindler B, Kemper N, Schmidt P, Bachmeier J, Schade B, Boehm B, Kappe E and Louton H** 2020 Validation of histological and visual scoring systems for foot-pad dermatitis in broiler chicken. *Animal Welfare* 29: 185-196. <https://doi.org/10.7120/09627286.29.2.185>
- Pritchard DG** 2012 The impact of legislation and assurance schemes on alternative systems for poultry. In: Sandilands V and Hocking PM (eds) *Alternative Systems for Poultry: Health, Welfare and Productivity* pp 23-53. CABI: Oxon, UK. <https://doi.org/10.1079/9781845938246.0023>
- Report from the Commission to the European Parliament and the Council** 2018 *Report from the Commission to the European Parliament and the Council on the application of Directive 2007/43/EC and its influence on the welfare of chickens kept for meat production, as well as the development of welfare indicators*. <https://eur-lex.europa.eu/legal-content/EN/TXT/?uri=CELEX:32007L0043>
- Shepherd EM and Fairchild BD** 2010 Footpad dermatitis in poultry. *Poultry Science* 89: 2043-2051. <https://doi.org/10.3382/ps.2010-00770>
- Swets KA** 1988 Measuring the accuracy of diagnostic systems. *Science* 240: 1285-1293. <https://doi.org/10.1126/science.3287615>
- Toppel K, Spindler B, Kaufmann F, Gauly M, Kemper N and Andersson R** 2019 Foot pad health as part of on-farm-monitoring in turkey flocks. *Frontiers in Veterinary Science* 6: 25. <https://doi.org/10.3389/fvets.2019.00025>
- Van Harn J and de Jong I** 2017 Validation of Meyn Footpad Inspection System. *Wageningen Livestock Research Report 1044 B*. <https://doi.org/10.18174/423304>
- van Uizen NR, Semin GR, Oudejans RR and Beek PJ** 2008 Affective stimulus properties influence size perception and the Ebbinghaus illusion. *Psychological Research* 72(3): 304-310. <https://doi.org/10.1007/s00426-007-0114-6>
- Weber Wyneken C, Sinclair A, Veldkamp T, Vinco LJ and Hocking PM** 2015 Footpad dermatitis and pain assessment in turkey poults using analgesia and objective gait analysis. *British Poultry Science* 56: 522-530. <https://doi.org/10.1080/00071668.2015.1077203>
- Wohlsein P, Baumgärtner W and Hewicker-Trautwein M** 2015 Haut. In: Baumgärtner W and Gruber AD (eds) *Spezielle Pathologie für die Tiermedizin* pp 342-349. Enke Verlag: Stuttgart, Germany. <https://doi.org/10.1055/b-003-125811>. [Title translation: Special pathology for veterinary medicine]
- Wyers M, Cherel Y and Plassiart G** 1991 Late clinical expression of lameness related to associated osteomyelitis and tibial dyschondroplasia in male breeding turkeys. *Avian Diseases* 35: 408-414. <https://doi.org/10.2307/1591199>
- Youden WJ** 1950 Index for rating diagnostic tests. *Cancer* 3(1): 32-35. [https://doi.org/10.1002/1097-0142\(1950\)3:1<32::AID-CNCR2820030106>3.0.CO;2-3](https://doi.org/10.1002/1097-0142(1950)3:1<32::AID-CNCR2820030106>3.0.CO;2-3)
- Youssef IM, Beineke A, Rohn K and Kamphues J** 2011 Effects of high dietary levels of soybean meal and its constituents (potassium, oligosaccharides) on foot pad dermatitis in growing turkeys housed on dry and wet litter. *Archives of Animal Nutrition* 65(2): 148-162. <https://doi.org/10.1080/1745039X.2010.533548>