

Topical tamoxifen in the therapy of cutaneous leishmaniasis

CRISTIANA T. TRINCONI, JULIANA Q. REIMÃO[†], VIVIAN I. BONANO,
CAROLINE R. ESPADA, DANILO C. MIGUEL[‡], JENICER
K. U. YOKOYAMA-YASUNAKA and SILVIA R. B. ULIANA*

Departamento de Parasitologia, Instituto de Ciências Biomédicas, Universidade de São Paulo, Av. Prof. Lineu Prestes 1374, 05508-000 São Paulo, Brazil

(Received 15 November 2016; revised 14 December 2016; accepted 3 January 2017; first published online 9 March 2017)

SUMMARY

The aims of the present work were to test the effect of tamoxifen administered topically and the therapeutic efficacy of tamoxifen and pentavalent antimonial combinations in an experimental model of cutaneous leishmaniasis. BALB/c mice infected with a luciferase expressing line of *Leishmania amazonensis* were treated with topical tamoxifen in two different formulations (ethanol or oil-free cream) as monotherapy or in co-administration with pentavalent antimonial. Treatment efficacy was evaluated by lesion size and parasite burden, quantified through luminescence, at the end of treatment and 4 weeks later. Topical tamoxifen, formulated in ethanol or as a cream, was shown to be effective. The interaction between tamoxifen and pentavalent antimonial was additive *in vitro*. Treatment with combined schemes containing tamoxifen and pentavalent antimonial was effective in reducing lesion size and parasite burden. Co-administration of tamoxifen and pentavalent antimonial was superior to monotherapy with antimonial.

Key words: Topical treatment, tamoxifen, *Leishmania amazonensis*, combination therapy, luciferase.

INTRODUCTION

Leishmaniasis is a neglected vector-borne tropical infection found in 98 countries in tropical and subtropical regions of the world. About 2 million new cases of leishmaniasis occur each year worldwide (Alvar *et al.* 2012). The disease is clinically complex with two major syndromes, visceral and cutaneous leishmaniasis (VL and CL). Additionally, other clinical presentations do occur, including the mucocutaneous, diffuse and disseminated forms of CL and post-kala-azar dermal leishmaniasis (Alvar *et al.* 2012).

There is a limited number of proven treatment options for CL. Pentavalent antimonials are still the first line drugs, although reported therapeutic efficacy of standard schemes (20 mg kg⁻¹ of antimony daily for 20 days) is now as low as 55% in some studies conducted in Brazil or 40% in Iran (Machado *et al.* 2010; Chrusciak-Talhari *et al.* 2011; Neves *et al.* 2011; Dastgheib *et al.* 2012).

Pentamidine and amphotericin B represent second line drugs, which are of limited use due to their toxicity and cost (Alvar *et al.* 2006). Oral miltefosine shows species-dependent efficacy against CL and

treatment failures have been reported (Soto *et al.* 2004; Yardley *et al.* 2005). Overall, chemotherapeutic agents available for leishmaniasis treatment are limited by problems such as toxicity, variable efficacy and cost but are still used due to the lack of other options. Therefore, the development of new therapeutic options for CL treatment remains essential.

Tamoxifen, an anticancer agent, has proven to be active *in vitro* against all Old and New World *Leishmania* species tested so far. Oral and parenteral tamoxifen are effective in experimental models of CL and VL (Miguel *et al.* 2008, 2009; Eissa *et al.* 2011). Tamoxifen has been shown to display additive interactions with amphotericin B (Trinconi *et al.* 2014) and miltefosine (Trinconi *et al.* 2016).

Topical therapy for CL has been recommended due to its theoretical local potentiation, low cost and ease of administration, without the requirements for a complex health system infrastructure (Modabber *et al.* 2007). On the other hand, adoption of drug combination schemes in leishmaniasis has been also recommended with the aim of increasing therapeutic efficacy and preventing resistance emergence. Ideally, the reduction in dose and time of treatment would also result in lower toxicity and greater patient's compliance (Modabber *et al.* 2007; Meheus *et al.* 2010).

With these elements in mind, we set out to investigate the effect of tamoxifen administered by the topical route and its effect in co-administration schemes with pentavalent antimonial *in vitro* and *in vivo*, using a model of infection with *Leishmania amazonensis*.

* Corresponding author: Departamento de Parasitologia, Instituto de Ciências Biomédicas, Universidade de São Paulo, Av. Prof. Lineu Prestes 1374, 05508-000, São Paulo, Brazil. E-mail: srbulian@icb.usp.br

[†] Present address: Departamento de Morfologia e Patologia Básica, Faculdade de Medicina de Jundiaí, Jundiaí, São Paulo, Brazil.

[‡] Present address: Departamento de Biologia Animal, Instituto de Biologia, Universidade Estadual de Campinas, Campinas, São Paulo, Brazil.

MATERIALS AND METHODS

Parasites and macrophages

Leishmania (Leishmania) amazonensis (La-WT) (MHOM/BR/1973/M2269) promastigotes were grown in M-199 medium supplemented with 10% heat inactivated-fetal calf serum (Gibco™, Invitrogen Corporation, NY, USA), 25 mM HEPES (pH 6.9), 12 mM NaHCO₃, 7.6 mM haemin, 50 U mL⁻¹ penicillin and 50 µg mL⁻¹ streptomycin at 25 °C. Promastigotes of a *L. amazonensis* transgenic line expressing luciferase (La-LUC) (Reimao *et al.* 2013) were grown in the same medium supplemented with 32 µg mL⁻¹ G418 (Geneticin™, Sigma-Aldrich, St. Louis, MO, USA). Bone marrow-derived macrophages (BMDM) were obtained from BALB/c mice as described (Reimao *et al.* 2013).

Drugs

Tamoxifen and tamoxifen citrate were purchased from Sigma-Aldrich (St. Louis, MO, USA). Stock solutions of tamoxifen (10 mM) were prepared in dimethyl sulfoxide (DMSO) and kept at -20 °C. Subsequent dilutions were done in culture media. For *in vivo* topical experiments, 1% tamoxifen was prepared in ethanol (w/v) or formulated as a cream with 0.1% tamoxifen citrate using an oil-free base (Drogaderma, São Paulo, Brazil).

Meglumine antimoniate (Glucantime™, 300 mg mL⁻¹, Aventis-Pharma, Brazil) was kindly donated by the Brazilian Ministry of Health. Glucantime™ solution contained 300 mg mL⁻¹ meglumine antimoniate corresponding to 81 mg mL⁻¹ pentavalent antimonial (Sb^V). Antimonial doses mentioned henceforth refer to the concentration of Sb^V. For *in vivo* experiments, stock solutions of Glucantime™ were prepared in sterile saline (0.9% NaCl).

Infection and treatment of mice

Animal experiments were performed in strict accordance with the recommendations and guidelines of the Sociedade Brasileira de Ciência de Animais de Laboratório (SBCAL) and of the Conselho Nacional de Controle da Experimentação Animal (CONCEA) and were approved by the Ethics Committee for Animal Experimentation (Protocol: 178/2012) of the Biomedical Sciences Institute, University of São Paulo.

Female BALB/c mice (60 days old) were inoculated with 10⁶ stationary-phase La-LUC promastigotes at the base of the tail. Treatment was initiated when lesions were apparent (3–8 weeks). Mice were assigned into experimental groups ($n = 4-8$), so that the average lesion size was equivalent in all groups.

For the topical administration, 44 µL of 1% tamoxifen in ethanol (0.44 µg or 20 mg kg⁻¹) were

applied over the lesion daily. The ethanolic solution was applied dropwise, slowly, until completely dried, once a day during 15 consecutive days. Control groups included untreated mice and a group treated with ethanol.

Treatment efficacy was evaluated by clinical parameters. Lesion size was recorded weekly as the mean of tail base diameters (in horizontal and vertical directions). Lesion growth was considered as the lesion size on the day of observation subtracted from the lesion size at day 0 (the day before starting the treatment) for the same animal. Measurements were taken with a calliper (Mitutoyo Corp., Japan).

In vivo evaluation of topical tamoxifen as a single drug or co-administered with parenteral meglumine antimoniate

Animal infection, distribution into experimental groups and topical treatment of tamoxifen in ethanol were performed as described in the previous section, except for the duration. Topical treatment performed with the 0.1% citrate tamoxifen cream was performed in animals kept individualized in cages covered with filter paper to avoid mechanical removal of the drug. Topical treatment with both drug formulations was applied daily for 30 consecutive days and compared with treated control groups receiving the same vehicle used to formulate tamoxifen.

Treatment with Sb^V 40 or 80 mg kg⁻¹ day⁻¹, corresponding to twice or four times the Sb^V dose recommended for human therapy, was given by the intraperitoneal route in 200 µL final volume during 20 consecutive days as monotherapy or in combination with topical tamoxifen.

Clinical evaluation of treated and untreated animals was obtained as described above. Parasite burden was determined at the end of treatment and 4 weeks after the end of treatment through luciferase detection by bioimaging as described (Reimao *et al.* 2013; Trinconi *et al.* 2014). In brief, the luminescence intensity of a fixed-size region of interest was determined 20 min after luciferin administration (75 mg kg⁻¹, i.p.) (VivoGlo™ Luciferin, Promega, Madison, WI, USA). Images were collected through high-resolution mode with 2 min of exposure time (IVIS Spectrum, Caliper Life Sciences, Inc. MA/USA). Results were quantified with Living Image software version 4.3.1 (Caliper Life Sciences, Inc. MA/USA) and expressed as the number of photons s⁻¹ cm⁻² sr⁻¹.

Assessment of tamoxifen and Sb^V interaction in intracellular amastigotes

BMDM were infected with La-LUC stationary phase promastigotes as described previously (Trinconi *et al.* 2014). Infected macrophages were treated with tamoxifen (0.19–12 µM) and Sb^V

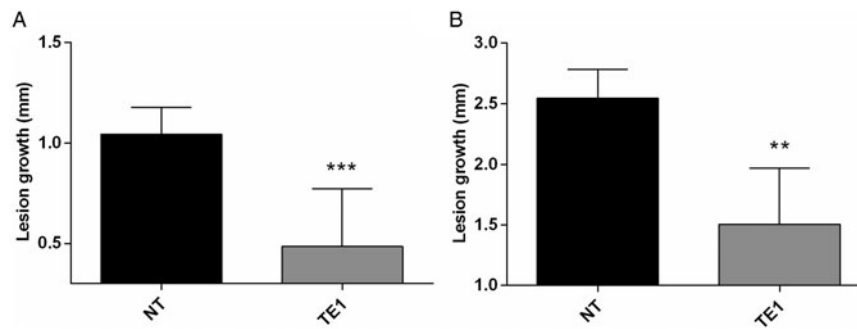


Fig. 1. Efficacy of topical tamoxifen in the treatment of *L. amazonensis*-infected mice. Mice were treated topically with 1% tamoxifen dissolved in ethanol. Treatment started 8 weeks post-infection and was given for 15 days. Data represent the mean size of lesions and standard deviation at the end of treatment (A) and 4 weeks after the end of treatment (B). NT, untreated group; TE1, treated with 1% tamoxifen. ** $P = 0.005$; *** $P = 0.0005$.

($18.75\text{--}1200\ \mu\text{g mL}^{-1}$) for 120 h. The viability of intracellular amastigotes was determined using the One Glo™ Luciferase Assay System (Promega Corporation, Madison, WI, USA), as previously described (Trinconi *et al.* 2014). Briefly, at the end of the experiment the medium was replaced with $100\ \mu\text{L}$ of PBS plus $20\ \mu\text{L}$ of OneGlo™ reagent at room temperature followed by homogenization. Luminescence was recorded in a microplate reader (Polarstar Omega, BMG Labtech, Ortenberg, Germany). The luminescence reading from treated wells was used to calculate sigmoidal regression curves using untreated infected macrophages as controls. Each point was tested in triplicate. In some experiments, the morphology of treated cells was evaluated through optical microscopy after panoptical staining, as described (Reimao *et al.* 2013).

The interactions between drugs were evaluated by a modified isobologram method (Fivelman *et al.* 2004; Seifert and Croft, 2006), as described (Trinconi *et al.* 2014). Briefly, the highest concentrations of drugs were prepared in ratios of 5:0, 4:1, 3:2, 2:3, 1:4 and 0:5 (tamoxifen: Sb^{V}) and a dose-response curve was constructed for each drug combination. The EC_{50} of tamoxifen and Sb^{V} were determined for each ratio. The fractional inhibitory concentration index (FICI), the sum of FICI ($\sum\text{FICI}$) and the mean sum of FICI ($x\sum\text{FICI}$) were determined as described (Fivelman *et al.* 2004; Seifert and Croft, 2006). Isobolograms were built plotting the FICI values for each drug ratio. The $\sum\text{FICI}$ was used to classify the drug interactions as follows: $x\sum\text{FICI} \leq 0.5$ indicates synergism, $0.5 > x\sum\text{FICI} \leq 4$ indicates indifferent/additive interaction and $x\sum\text{FICI} > 4$ indicates antagonism (Odds, 2003). Two independent experiments were performed in duplicate for each drug combination assay.

Statistical analysis

Data were analysed for statistical significance by the *t*-Student's test or one-way ANOVA, followed by

the Tukey post-test, using GraphPad Prism 5 software. P values ≤ 0.05 were considered statistically significant.

RESULTS

In vivo efficacy of topical tamoxifen

The efficacy of topically administered tamoxifen was investigated in *L. amazonensis* infected BALB/c mice. As an initial proof-of-concept, an experiment was performed applying 1% tamoxifen solutions prepared in ethanol onto the tail lesions of *L. amazonensis* infected mice, daily, for 15 days. The outcome in the vehicle control group treated with ethanol was indistinguishable from untreated animals (data not shown). At the end of treatment, lesion size was significantly reduced in animals treated with topical tamoxifen as compared with control animals, untreated and treated with vehicle (Fig. 1A and data not shown). This effect was sustained since a significant reduction in lesion size was observed 4 weeks after the interruption of treatment (Fig. 1B).

We then searched for a tamoxifen formulation of potential clinical relevance. A cream formulation of 0.1% citrate tamoxifen in oil-free cream was chosen given its previous use in the long-term therapy of cheloids (Macena *et al.* 2006; Pasquetti *et al.* 2010). Starting 3 weeks post-infection, mice were treated with 1% tamoxifen in ethanol or 0.1% tamoxifen citrate in oil-free cream for 30 days (Fig. 2). Control groups were left untreated or were treated with the oil-free cream vehicle. A reduction in lesion size at the end of the treatment was observed in the vehicle group, probably due the moisturizing effect of the cream. Mice treated with 0.1% tamoxifen cream displayed a discrete skin reaction at the lesion site with erythema and oedema at the end of treatment. The localized oedema disappeared with the interruption of treatment and was undetectable 1 week later (59th day post-infection). The follow-up of tamoxifen treated mice showed a sustained and significant reduction in lesion size,

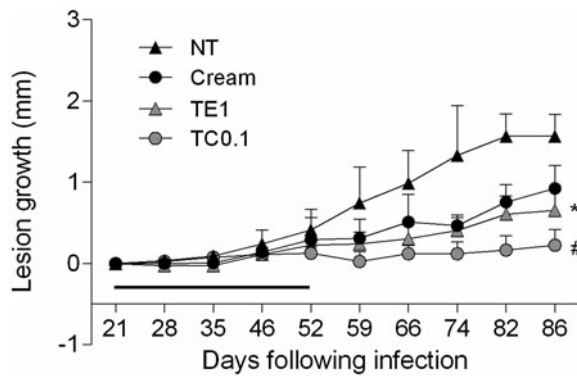


Fig. 2. Follow up of *L. amazonensis* infection in BALB/c mice treated with topical tamoxifen. Progression of lesion size (mean \pm s.d.) in *L. amazonensis*-infected mice untreated (NT) or treated with 1% tamoxifen diluted in ethanol (TE1), 0.1% citrate tamoxifen formulated as a cream (TC0.1) and the control vehicle without drug (Cream). The horizontal black bar indicates the period of topical treatment, which was initiated 3 weeks post-infection. * $P < 0.01$, # $P < 0.0001$.

when compared with the control groups (Fig. 2). Interestingly, 0.1% tamoxifen formulated as a cream was more effective than 1% tamoxifen applied as an ethanolic solution, although neither resulted in full lesion healing.

Efficacy of tamoxifen administered topically as single therapy or associated with systemic Sb^V

We were then interested in testing the efficacy of topical tamoxifen as part of a combination scheme with the first choice drug for CL treatment in Brazil, meglumine antimoniate.

In vitro interactions between tamoxifen and Sb^V were tested in *L. amazonensis* intracellular amastigotes. The analysis of EC_{50} determinations in various drug combinations indicated a sum of FICI of 1.05 (Table 1) indicating an additive interaction between the two drugs. This was confirmed by isobologram analysis (Supplementary Fig. 1), justifying the investigation of co-administration schemes of tamoxifen and Sb^V in an *in vivo* model.

Three weeks after infection, groups of mice were assigned to be treated with topical tamoxifen alone (1% diluted in ethanol or 0.1% formulated as a cream), Sb^V alone in two different doses (40 or 80 $mg\ kg^{-1}\ day^{-1}$) or with the combination of the two drugs. Topical tamoxifen was applied for 30 days and Sb^V was given for 20 days.

Figure 3 shows the clinical and parasitological evaluation at the end of treatment and 4 weeks after the interruption of treatment. At the end of treatment, all treated groups had significant reductions in lesion size compared with the untreated group, with the exception of 40 $mg\ Kg^{-1}\ day^{-1}$ Sb^V monotherapy (Fig. 3A). Co-administration of tamoxifen (1% in ethanol or 0.1% as a cream) and

Sb^V resulted in a more pronounced reduction in lesion size and parasite load than 40 or 80 $mg\ kg^{-1}\ day^{-1}$ Sb^V single therapy (Fig. 3A and B). There was no significant difference between groups treated with 0.1% tamoxifen alone or combined with antimonial. The parasite burden of representative animals from each group at the end of the treatment is shown in Fig. 4A.

Four weeks after the end of the treatment, significant reduction in lesion size and parasite burden was observed in animals treated with 0.1% tamoxifen as compared with the control animals (Figs 3C, D and 4B). Tamoxifen 0.1% formulated as a cream resulted in significant clinical and parasitological responses, when compared with Sb^V monotherapy schemes. Groups treated with the combination of topical tamoxifen and Sb^V had improved outcome, both clinical and parasitological, as compared with Sb^V monotherapy groups. On the other hand, the outcome of the combination was not significantly different from topical tamoxifen alone. Bioimaging of representative animals from each group at this late time point is shown in Fig. 4B.

DISCUSSION

Drug delivery through the skin as a tool for CL treatment may be advantageous if used cautiously: administration is easy, the risk of systemic side-effects is reduced and hepatic first-pass metabolism is avoided, resulting in reduction in the amount of drug to be administered (Paudel *et al.* 2010).

Here we investigated the leishmanicidal activity of tamoxifen when given by the topical route. Initial experiments were performed with ethanol as a dilutant since it has been widely used in pharmaceutical preparations and cosmetic products as a transdermal delivery system (Lachenmeier, 2008) and is capable of increasing drug partitioning into the stratum corneum. The efficacy of this formulation was evaluated in *L. amazonensis* infections, a very aggressive CL experimental model. The significant improvement of lesion size in treated animals compared to the control group at the end of the treatment and 4 weeks later demonstrated the activity and clinical efficacy of tamoxifen administered by the topical route.

Tamoxifen has been previously applied topically to the treatment and prevention of human hypertrophic scars and keloids (Hu *et al.* 1998; Gragnani *et al.* 2010; Mousavi *et al.* 2010). A formulation containing 0.1% tamoxifen citrate in oil-free cream applied twice a day for 4–12 months to post-burn keloid scars was reported to be effective, with minimal side-effects (Macena *et al.* 2006; Pasquetti *et al.* 2010). Topical treatment with 0.1% tamoxifen citrate cream formulation controlled the lesion growth in a sustained manner, as evaluated 4 weeks after the end of treatment. The parasite burden

Table 1. EC₅₀ and FICI of tamoxifen and Sb^V combinations against *L. amazonensis* intracellular amastigotes

Drug ratio (Tam:Sb ^V)	EC ₅₀ ± s.d. ^a		FICI ± s.d.			
	Tam (μM)	Sb ^V (μg mL ⁻¹)	Tam	Sb ^V	ΣFICI	ΣFICI
5:0	2.0 ± 0.1	–	–	–	–	1.05
4:1	1.9 ± 0.3	31.4 ± 13.9	0.9 ± 0.1	0.2 ± 0.1	1.1 ± 0.01	
3:2	1.5 ± 0.6	63.0 ± 8.2	0.7 ± 0.2	0.3 ± 0.1	1.0 ± 0.2	
2:3	1.3 ± 0.9	98.1 ± 0.4	0.6 ± 0.4	0.5 ± 0.1	1.1 ± 0.3	
1:4	0.6 ± 0.4	126.3 ± 15.1	0.3 ± 0.2	0.6 ± 0.02	0.9 ± 0.1	
0:5	–	196.6 ± 30.4	–	–	–	

^a 50% effective concentration ± standard deviation of two independent experiments. Values were determined against intracellular amastigotes in infected macrophages by luminescence.

Tam, tamoxifen; Sb^V: pentavalent antimonial; FICI, fractional inhibitory concentration ± s.d. of two independent experiments; ΣFICI, sum of FICIs; xΣFICI, mean sum of FICIs.

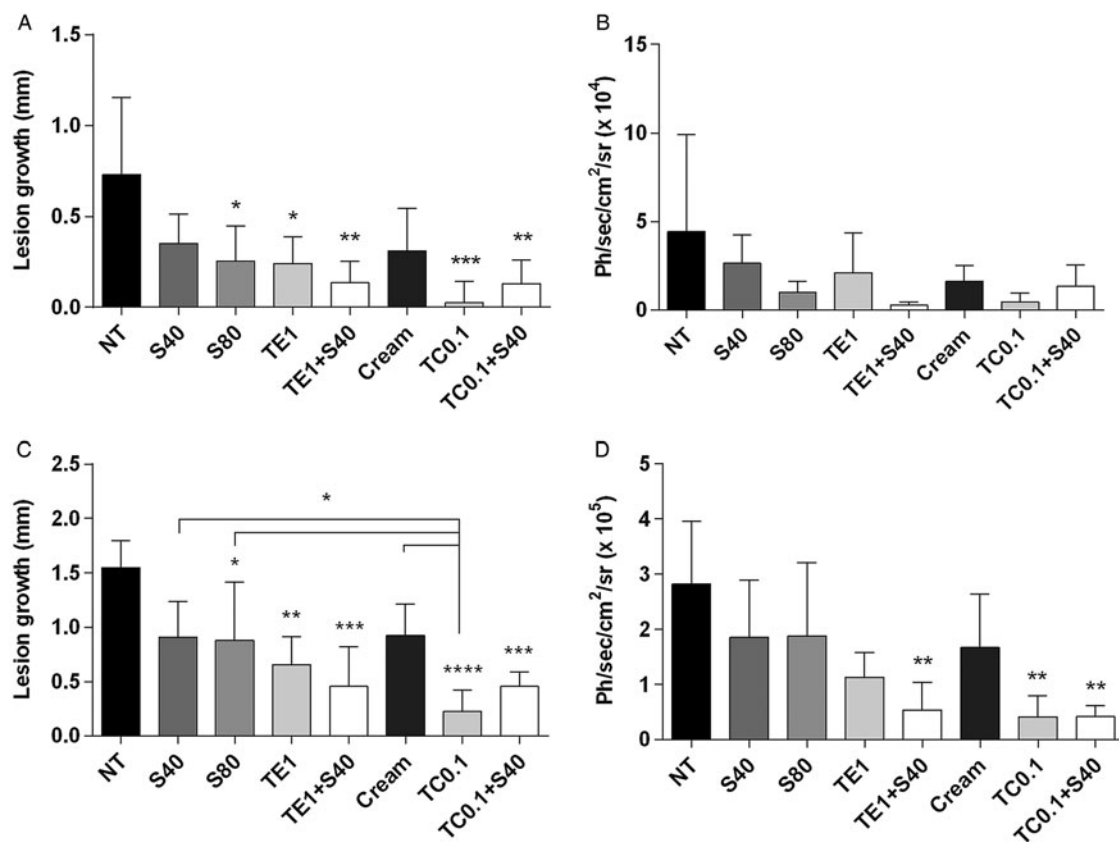


Fig. 3. Efficacy of topical tamoxifen alone or in combination with pentavalent antimonial in the treatment of *L. amazonensis*-infected mice. (A–D) Efficacy of topical tamoxifen as single therapy or in combination with Sb^V: evaluation of lesion size (A, C) and parasite burden (B, D) in mice at the end of treatment (A, B) and 4 weeks after the end of treatment (C, D). Mice were treated with topical tamoxifen for 30 days and/or Sb^V for 20 days. The mean ($n = 5$) and standard deviation of the data are indicated. NT, untreated; Cream, treated with oil-free cream (vehicle control group); S40, S80, treated with 40 or 80 mg kg⁻¹ day⁻¹ Sb^V i.p.; TE1, treated with 1% tamoxifen in ethanol; TC0.1, treated with 0.1% tamoxifen citrate in oil-free cream. * $P < 0.05$, ** $P < 0.01$, *** $P < 0.001$, **** $P < 0.0001$. Ph s⁻¹ cm⁻² sr⁻¹: photons per second per square centimetre per steradian.

was also significantly reduced when compared with untreated groups at this late time point. Interestingly, the 0.1% cream formulation was more effective than the 1% ethanolic solution, both clinically and parasitologically, probably due to a more adequate formulation.

Although topical treatment for CL may have various appealing advantages, in various instances it could be considered unsafe if applied as monotherapy. That would be the case in infections with *Leishmania braziliensis* or *Leishmania guyanensis*, where mucocutaneous or disseminated disease may

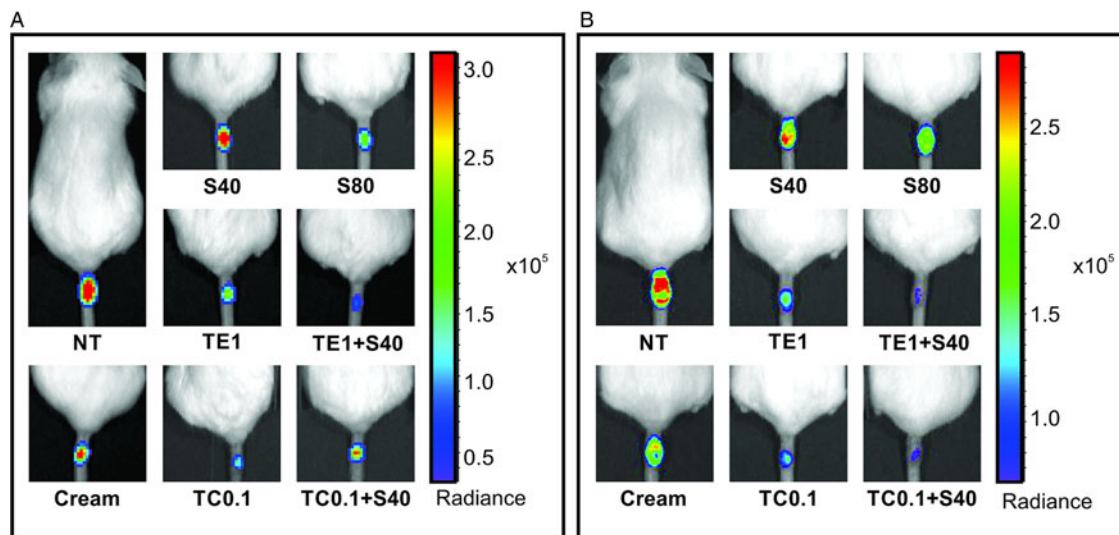


Fig. 4. Parasite burden in *L. amazonensis*-infected mice treated with tamoxifen topical formulations and/or pentavalent antimonial. Representative animals treated with single or combined tamoxifen topical formulations (1% ethanolic solution or 0.1% oil-free cream) and pentavalent antimonial (40 or 80 mg kg⁻¹ day⁻¹, i.p.) at the end of treatment (A) and 4 weeks later (B). NT, untreated; Cream, treated with oil-free cream (vehicle control group), TE1, treated with 1% tamoxifen in ethanolic solution; TC0.1, treated with 0.1% tamoxifen citrate oil-free cream, S40, S80, treated with 40 or 80 mg kg⁻¹ day⁻¹ Sb^V. Ph s⁻¹ cm⁻² sr⁻¹: photons per second per square centimetre per steradian. The bar on the right shows a pseudo-colour scale representing light intensities.

develop. The same considerations would apply to other New World species. In these circumstances, the use of a second, systemic drug may be instrumental. Considering that the treatment success of one course of meglumine antimoniate treatment in *L. braziliensis* and *L. guyanensis* infections may be as low as 53–55% (Machado *et al.* 2010; Chrusciak-Talhari *et al.* 2011; Neves *et al.* 2011), a new associated tool may prove of great value.

Based on these factors, topical efficacy of tamoxifen was also evaluated in combination with meglumine antimoniate, the main pentavalent antimonial used in Latin America for the treatment of leishmaniasis. *In vitro* studies with fixed-ratio dilutions and isobologram analysis demonstrated an additive interaction between tamoxifen and Sb^V against intracellular amastigotes with the absence of toxicity to the murine BMDM. The interaction between tamoxifen and Sb^V was tested *in vivo* using both topical formulations of tamoxifen (formulated in ethanol and cream) and Sb^V given by the parenteral route. The efficacy of the combination was superior to the response observed in groups treated with antimonial alone and equivalent to topical tamoxifen administered as a cream.

CL can cause extensive lesions and result in large scars mostly in exposed parts of the body, as hands and face. The impact of scarring may be extensive leading to social exclusion (Reithinger *et al.* 2005; Kassi *et al.* 2008). Collagen remodelling observed upon treatment of human keloids and hypertrophic scars with tamoxifen has clinical impact, measured as improved skin texture, reduced pruritus and

reduced scarred area (Macena *et al.* 2006; Gragnani *et al.* 2010; Pasquetti *et al.* 2010). These aspects are potentially beneficial for the treatment of CL as well.

In conclusion, topical use of tamoxifen is effective for the treatment of CL in this experimental model. The co-administration of topical tamoxifen with Sb^V resulted in improved and sustained efficacy in comparison with Sb^V monotherapy, even for groups treated with high doses of Sb^V, illustrating the advantages of combining the two drugs. The tamoxifen oil-free cream is a low-cost formulation, safe to humans and can be easily administered, representing an alternative to be tested for the treatment of human CL.

SUPPLEMENTARY MATERIAL

The supplementary material for this article can be found at <https://doi.org/10.1017/S0031182017000130>

ACKNOWLEDGEMENTS

The use of bioimaging equipment, provided by CEFAP-ICB was instrumental to this work.

FINANCIAL SUPPORT

This work was supported by the São Paulo Research Foundation (FAPESP) (grant numbers 2011/20484-7 and 2015/09080-2); Conselho Nacional de Desenvolvimento Científico e Tecnológico (CNPq) (grant number 473343/2012-6) and Coordenação de Aperfeiçoamento de Pessoal de Nível Superior (CAPES). DCM, CTT, JQR and CRE

were supported by FAPESP fellowships (grant numbers 2005/59881-0, 2011/18858-6, 2011/21970-2 and 2015/05130-5, respectively). JQR and VB received support from PNPd-CAPES and JKUYU was supported by a CNPq fellowship (grant number 473343/2012-6). SRBU is the recipient of a senior researcher scholarship from CNPq.

REFERENCES

- Alvar, J., Croft, S. and Olliaro, P. (2006). Chemotherapy in the treatment and control of leishmaniasis. *Advances in Parasitology* **61**, 223–274.
- Alvar, J., Velez, I. D., Bern, C., Herrero, M., Desjeux, P., Cano, J., Jannin, J. and den Boer, M. (2012). Leishmaniasis Worldwide and Global estimates of its incidence. *PLoS ONE* **7**, e35671.
- Chrusciak-Talhari, A., Dietze, R., Chrusciak Talhari, C., da Silva, R. M., Gadelha Yamashita, E. P., de Oliveira Penna, G., Lima Machado, P. R. and Talhari, S. (2011). Randomized controlled clinical trial to assess efficacy and safety of miltefosine in the treatment of cutaneous leishmaniasis caused by *Leishmania (Viannia) guyanensis* in Manaus, Brazil. *American Journal of Tropical Medicine and Hygiene* **84**, 255–260.
- Dastgheib, L., Naseri, M. and Mirashe, Z. (2012). Both combined oral azithromycin plus allopurinol and intramuscular Glucantime yield low efficacy in the treatment of Old World cutaneous leishmaniasis: a randomized controlled clinical trial. *International Journal of Dermatology* **51**, 1508–1511.
- Eissa, M. M., Amer, E. I. and El Sawy, S. M. (2011). *Leishmania major*: activity of tamoxifen against experimental cutaneous leishmaniasis. *Experimental Parasitology* **128**, 382–390.
- Fivelman, Q. L., Adagu, I. S. and Warhurst, D. C. (2004). Modified fixed-ratio isobologram method for studying in vitro interactions between atovaquone and proguanil or dihydroartemisinin against drug-resistant strains of *Plasmodium falciparum*. *Antimicrobial Agents and Chemotherapy* **48**, 4097–4102.
- Gragani, A., Warde, M., Furtado, F. and Ferreira, L. M. (2010). Topical tamoxifen therapy in hypertrophic scars or keloids in burns. *Archives for Dermatological Research. Archiv für Dermatologische Forschung* **302**, 1–4.
- Hu, D., Hughes, M. A. and Cherry, G. W. (1998). Topical tamoxifen—a potential therapeutic regime in treating excessive dermal scarring? *British Journal of Plastic Surgery* **51**, 462–469.
- Kassi, M., Kassi, M., Afghan, A. K., Rehman, R. and Kasi, P. M. (2008). Marring leishmaniasis: the stigmatization and the impact of cutaneous leishmaniasis in Pakistan and Afghanistan. *PLoS Neglected Tropical Diseases* **2**, e259.
- Lachenmeier, D. W. (2008). Safety evaluation of topical applications of ethanol on the skin and inside the oral cavity. *Journal of Occupational Medicine and Toxicology* **3**, 26.
- Macena, C., Ávila, D., Mattar, C., Daguier, E., Ruiz, R. and Filho, M. (2006). Uso do tamoxifeno no tratamento de quelóide. *Revista da Faculdade de Ciências Médicas Sorocaba* **8**, 18–24.
- Machado, P. R., Ampuero, J., Guimaraes, L. H., Villasboas, L., Rocha, A. T., Schriefer, A., Sousa, R. S., Talhari, A., Penna, G. and Carvalho, E. M. (2010). Miltefosine in the treatment of cutaneous leishmaniasis caused by *Leishmania braziliensis* in Brazil: a randomized and controlled trial. *PLoS Neglected Tropical Diseases* **4**, e912.
- Meheus, F., Balasegaram, M., Olliaro, P., Sundar, S., Rijal, S., Faiz, M. A. and Boelaert, M. (2010). Cost-effectiveness analysis of combination therapies for visceral leishmaniasis in the Indian subcontinent. *PLoS Neglected Tropical Diseases* **4**, e818.
- Miguel, D. C., Yokoyama-Yasunaka, J. K. and Uliana, S. R. (2008). Tamoxifen is effective in the treatment of *Leishmania amazonensis* infections in mice. *PLoS Neglected Tropical Diseases* **2**, e249.
- Miguel, D. C., Zauli-Nascimento, R. C., Yokoyama-Yasunaka, J. K., Katz, S., Barbieri, C. L. and Uliana, S. R. (2009). Tamoxifen as a potential antileishmanial agent: efficacy in the treatment of *Leishmania braziliensis* and *Leishmania chagasi* infections. *Journal of Antimicrobial Chemotherapy* **63**, 365–368.
- Modabber, F., Buffet, P. A., Torrelee, E., Milon, G. and Croft, S. L. (2007). Consultative meeting to develop a strategy for treatment of cutaneous leishmaniasis. Institute Pasteur, Paris. 13–15 June, 2006. *Kinetoplastid Biology and Disease* **6**, 3.
- Mousavi, S. R., Raaiszadeh, M., Aminseresht, M. and Behjoo, S. (2010). Evaluating tamoxifen effect in the prevention of hypertrophic scars following surgical incisions. *Dermatologic Surgery* **36**, 665–669.
- Neves, L. O., Talhari, A. C., Gadelha, E. P., Silva Junior, R. M., Guerra, J. A., Ferreira, L. C. and Talhari, S. (2011). A randomized clinical trial comparing meglumine antimoniate, pentamidine and amphotericin B for the treatment of cutaneous leishmaniasis by *Leishmania guyanensis*. *Anais Brasileiros de Dermatologia* **86**, 1092–1101.
- Odds, F. C. (2003). Synergy, antagonism, and what the checkerboard puts between them. *Journal of Antimicrobial Chemotherapy* **52**, 1.
- Pasquetti, A., Mota, W., Santos, M. and Brito, H. (2010). Uso do tamoxifeno no tratamento de quelóides e cicatrizes hipertróficas. Tamoxifen as treatment to keloids and hypertrophic scars. *Revista Brasileira de Cirurgia Plástica* **25**, 372–378.
- Paudel, K. S., Milewski, M., Swadley, C. L., Brogden, N. K., Ghosh, P. and Stinchcomb, A. L. (2010). Challenges and opportunities in dermal/transdermal delivery. *Therapeutic Delivery* **1**, 109–131.
- Reimao, J. Q., Trinconi, C. T., Yokoyama-Yasunaka, J. K., Miguel, D. C., Kalil, S. P. and Uliana, S. R. (2013). Parasite burden in *Leishmania (Leishmania) amazonensis*-infected mice: validation of luciferase as a quantitative tool. *Journal of Microbiological Methods* **93**, 95–101.
- Reithinger, R., Aadil, K., Kolaczinski, J., Mohsen, M. and Hami, S. (2005). Social impact of leishmaniasis, Afghanistan. *Emerging Infectious Diseases* **11**, 634–636.
- Seifert, K. and Croft, S. L. (2006). In vitro and in vivo interactions between miltefosine and other antileishmanial drugs. *Antimicrobial Agents and Chemotherapy* **50**, 73–79.
- Soto, J., Arana, B. A., Toledo, J., Rizzo, N., Vega, J. C., Diaz, A., Luz, M., Gutierrez, P., Arboleda, M., Berman, J. D., Junge, K., Engel, J. and Sindermann, H. (2004). Miltefosine for new world cutaneous leishmaniasis. *Clinical Infectious Diseases* **38**, 1266–1272.
- Trinconi, C. T., Reimao, J. Q., Coelho, A. C. and Uliana, S. R. (2016). Efficacy of tamoxifen and miltefosine combined therapy for cutaneous leishmaniasis in the murine model of infection with *Leishmania amazonensis*. *Journal of Antimicrobial Chemotherapy* **71**, 1314–1322.
- Trinconi, C. T., Reimao, J. Q., Yokoyama-Yasunaka, J. K., Miguel, D. C. and Uliana, S. R. (2014). Combination therapy with tamoxifen and amphotericin B in experimental cutaneous leishmaniasis. *Antimicrobial Agents and Chemotherapy* **58**, 2608–2613.
- Yardley, V., Croft, S. L., De Doncker, S., Dujardin, J. C., Koirala, S., Rijal, S., Miranda, C., Llanos-Cuentas, A. and Chappuis, F. (2005). The sensitivity of clinical isolates of *Leishmania* from Peru and Nepal to miltefosine. *American Journal of Tropical Medicine and Hygiene* **73**, 272–275.