

Neuropathology in the HIV-Transgenic Rat (HIV-1 TG rat)

F. J. Denaro*** and J. Bryant**

*Dept. of Biology, Morgan State Univ., 1700 Cold Spring Ln., Baltimore, MD 21251

**Institute of Human Virology, 725 W. Lombard St. Baltimore, MD 21201

There remains a critical need for the development and optimization of animal models for Neuro-AIDS research. Understanding the pathogenesis of AIDS has been hampered by the lack of a manageable, relatively inexpensive, small animal model that accurately reproduces the symptoms of AIDS. This is particularly true for the unique aspects of AIDS neurological dysfunction. For example, there is strong evidence that supports the belief that HIV does not infect neurons. HIV associated neural cell death must then be the result of indirect mechanisms that involve other cell types (for example; monocytes, T-cells, or endothelial cells). Consequently, identifying the events that result in neural death are more likely to be deduced from the study of intact nervous systems.

Behavior analysis can be a useful parameter for the study of HIV-nervous system disease. Neuropsychological testing is considered the “Gold Standard” in clinical trials seeking to assess the efficacy of neuro-protective medications. Such an approach would require the appropriate animal models. To address these problems we have developed the first HIV-1 Transgenic Rat model for studying the pathophysiology of AIDS [1,2,3,4]. This model has unique characteristics compared to existing models and is particularly suited for the study of both central and peripheral neuropathology.

When the HIV-1 TG rat was produced and studied, we found important neurological changes similar to AIDS patients. Patients with AIDS develop problems with skeletal muscle and the peripheral nerves. The symptoms identified in the HIV-1 TgR include weakness, paralysis and muscular wasting. Increased sensitivity to tactile stimulation was identified and, problems with gait were observed.

Neuropathology in the HIV-1 TGR has been confirmed by microscopic analysis of brain, spinal cord and peripheral nerve and muscle. The brain and peripheral nerve showed inflammatory changes, cell death due to apoptosis and necrosis. Special silver stains demonstrated neuronal degeneration in the brain. Immunocytochemistry to HIV transgene products revealed that nervous tissues itself was not positive for the HIV transgene products but infiltrating lymphocytes displayed marked immunostaining. Increased permeability of the Blood Brain Barrier was confirmed.

References

- [1]. W. Reid. M. Sadowska., F. Denaro, et al., P. N. A. S. 2001, **98** (16): 9271-9276.
- [2]. F. Denaro, et al., Scientific World Journal, Jan 1; 1 (1Suppl 3): 50
- [3]. P. E. Ray, et al., *Kidney International* 2003, **63** (6): 2242-2256.
- [4]. R. Mazzucchelli, M. Amadio, S. Curreli, F. Denaro, et al., *Mol. Imm.* 2004, **41**, 10: 979-984.
- [5]. Grants: RCM1 12 RR017581, NS31857, MS29494, MARC and the Neuropathy Association

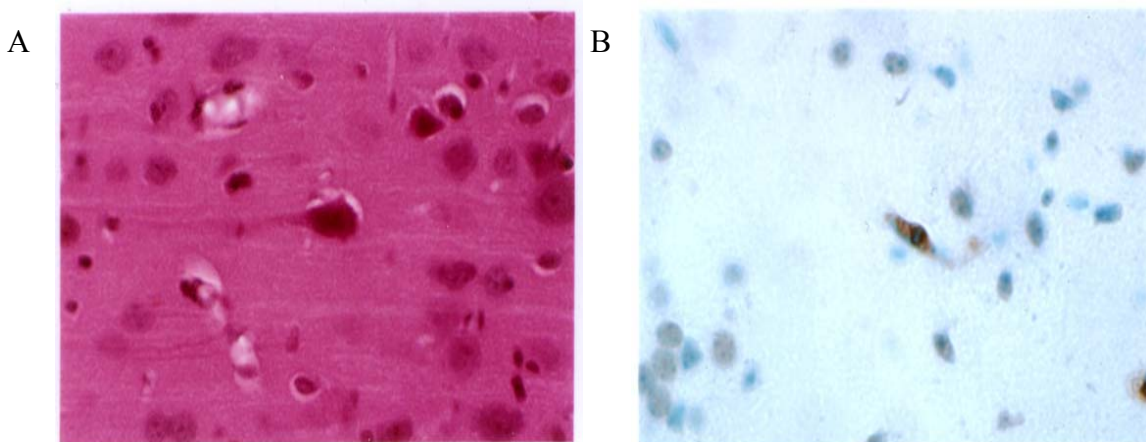


Figure 1: Several examples cellular lesions found in the of HIV-1 Tg Rat brain.
 A. H&E staining of the HIV-1 Transgenic rat brain. This is an example of the “dead and red” neuron. Original mag 40x. Such a stain does not reveal the nature of cell death. Other stains were used to identify possible mechanism. B. The use of Apo-tag to demonstrate Apoptotic cell death, demonstrated that several cell types including neurons were undergoing apoptosis. The brown label is in an endothelial like cell with the Apo-tag marker.

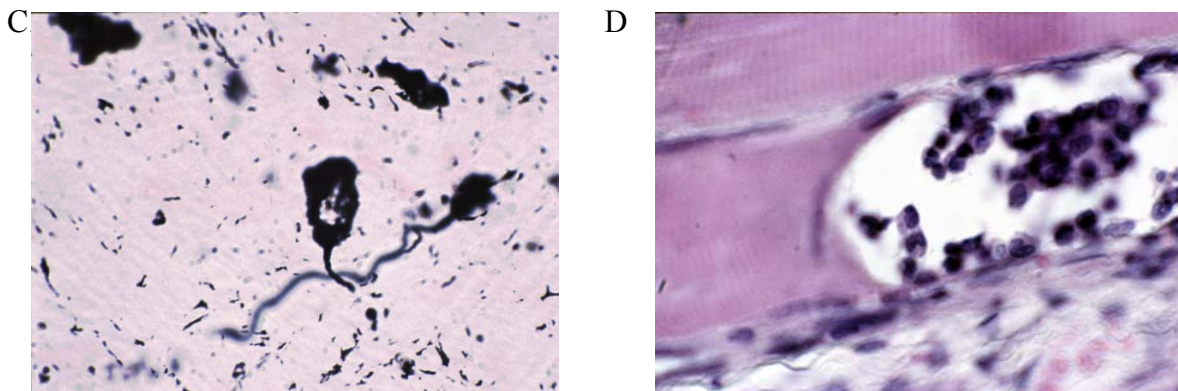


Figure 2: Neuronal death and abnormalities to skeletal muscle were also identified.
 C. The use of Sliver Cupric stain revealed degenerating neurons at all levels of the CNS. The black-labeled cell is a dead neuron. D. Muscle demonstrating marked inflammation. Monocytes and other lymphocytes were found invading some muscle.