

THE EFFECTS OF THE INHALATION OF COAL AND STONE DUSTS ON THE LUNGS OF PIT PONIES.

BY F. HAYNES.

(*From the Department of Physiology, University of Oxford.*)

(With Plate VI and 4 Text-figures.)

THIS work was undertaken at the request of the Medical Advisory Committee of the Safety in Mines Board, and with the aid of financial assistance from the Miners' Welfare Fund. The specimens were obtained through the Mining Association at the request of the Mines Department. The primary object of the investigation was to ascertain whether or no the various stone dusts used to minimise the risk of explosion in coal mines have any ill effect upon the lung.

The writer is desirous of expressing his gratitude to Dr J. S. Haldane, F.R.S., for his constant interest, to Dr H. M. Carleton for his ready and unfailing kindness and assistance throughout the work, to the management and veterinary staffs of numerous collieries throughout the kingdom for obtaining and forwarding samples of pit ponies' lungs and the particulars concerning them, to Sir John M'Fadyean for supplying the control specimens of lung, and to Dr A. G. Gibson for giving the benefit of his experience in the elucidation of difficult points in some of the specimens.

To Prof. Sir Charles Sherrington, O.M., F.R.S., are tendered the writer's thanks for the use of the facilities of the University Laboratory of Physiology.

INTRODUCTION.

It has long been known that coal dust is one of the least harmful of all the dusts inhaled industrially. Since the practice of laying down stone dust in coal mines was adopted, however, a certain degree of uneasiness has been felt as to the possible effect of the stone dust on the collier's lung.

The dusts used for stone-dusting are usually ground from some type of shale. Shale has been shown (Beattie, Mavrogordato, Carleton) to cause no permanent lesions when experimentally inhaled, though the rate of elimination of the dust is slower than that of coal. It has also been shown (Mavrogordato, Carleton) that when guinea-pigs are exposed to a mixture of coal and even such a deadly dust as flint, the coal stimulates the phagocytosis and consequent elimination of the flint, providing that the amount of flint be small compared with that of coal.

It was therefore felt that a so-called "harmless" dust such as shale would be rapidly eliminated if inhaled along with coal, even if a comparatively large proportion of shale were inhaled. Still, there were no authoritative data.

The guinea-pigs in the experiments of Mavrogordato and of Carleton were exposed for a total period of 24 hours, spread over 14 days, to a dense cloud of dust. Industrially, the concentration of the dust or dusts is much less, but the length of exposure is very considerably greater. It was felt, therefore, that the examination of the lungs of ponies which had been exposed, in the course of their work, to the dusts as breathed by miners would furnish data admitting of much closer application to the condition of the miner's lung than would the examination of the lungs of animals exposed to the same dusts under markedly artificial conditions.

The author was consequently requested to examine the lungs of pit ponies which had died, or been destroyed, after working for some time underground, with special reference to the possibility of lesions referable to the stone dusts in use.

The specimens were despatched from the collieries in 10 per cent. formalin (= 4 per cent. formaldehyde), and on receipt at the laboratory were examined by the naked eye, a piece of the specimen excised and transferred for post-fixation to mercuric chloride—formaldehyde solution—for twenty-four hours, this being done principally for the sake of the improved staining reaction obtained. The remainder of the specimen was then labelled and preserved in 4 per cent. formaldehyde in tap water. As a rule the specimens were from 30 to 100 grammes (one to three ounces) in weight, and the portion excised for microscopical examination was always taken at right angles to the pleura when the specimen included pleura. Large sections were examined. Unfortunately, in no case did the accompanying letter state from which part of the lung the specimen was taken.

The specimens were dehydrated and cleared in the usual manner, and freed from air in the vacuum thermostat. It was found that the pressure could be reduced almost to the limits of a water-pump, providing the reduction were effected slowly—*i.e.* occupying 15 minutes. After an hour in the thermostat the paraffin—M. P. 54° C.—was changed and the exhaustion continued until no more air escaped from the tissues.

All the observations were made on sections 8 μ in thickness.

As routine stains, Delafield's haematoxylin and eosin, and Heidenhain's iron haematoxylin followed by Curtis' Ponceau modification of van Gieson's stain, were used, while Ziehl-Neelsen, Claudius, bleu Borrel and others were used as bacterial stains.

Many of the specimens showed a greater or lesser degree of *post mortem* change, varying from the presence of the fine general pigment granules formed by the combination of formaldehyde with some product of autolysis to a degree of autolysis in which the tissue was unrecognisable. The formaldehyde precipitate, when present, was removed by treating the sections with a 1 per cent. solution of potassium hydroxide in 80 per cent. alcohol for 10–15 minutes, the sections being subsequently stained in Delafield's haematoxylin and orange G.

THE HISTOLOGY OF THE NORMAL HORSE'S LUNG.

Thanks to the kindness of Sir John M'Fadyean, of the Royal Veterinary College, the writer was able to obtain specimens of lung from six normal horses, killed in London. They were received in formaldehyde in sodium chloride solution, and, after macroscopic inspection, pieces were excised, after-fixed in mercuric chloride-formaldehyde solution, and then embedded in precisely the same manner as the pit pony specimens.

The controls were stained in Delafield's haematoxylin and eosin and in Heidenhain's iron haematoxylin and Curtis substitute for van Gieson, one specimen being also stained in Delafield's haematoxylin and van Gieson and then cleared in phenol-xylol as advocated by Schmorl for the purpose of demonstrating the finer collagen fibres. Specimens were also stained in Weigert's elastin stain, followed by Curtis' van Gieson.

In none of the controls could any dust be seen macroscopically, either in the lung substance or beneath the pleura. There was in all the control specimens some degree of congestion, probably agonal, this being very marked in C.H. 1. Fibrous tissue is markedly developed in the lung of the horse, well-defined collagen fibres being present in the alveolar walls. All save the most delicate collagen fibres are accompanied by elastic fibres.

The pleura is thick, with a well-marked coat of robust collagen fibres intermingled with stout elastic fibres. There is a distinct elastic layer, and elastic fibres accompany the collagen fibres which ramify in the muscular coat.

There are fair numbers of dust-containing phagocytes in the walls of the alveoli, but no free dust particles can be observed. The intracellular dust particles are usually very small. There is in most of the specimens a slight patchy thickening of the epithelium. The bronchi are occasionally catarrhal, and frequently contain dust-laden phagocytes. In only one of the controls was there any tendency towards the aggregation of dust around the blood vessels and bronchi, where there was a small amount, while there was a very slight deposit in the deeper layers of the pleura.

Mechanical collapse is present in all the control, and also in the great majority of the pit pony, specimens.

THE EXAMINATION OF THE PIT PONY SPECIMENS.

Of the fifty-seven specimens received, none was taken from an animal which had worked less than two years underground, so that all had had a considerable exposure to the dusts.

In thirty-three instances only was the cause of death stated. Ten were cases of natural death, sixteen animals were destroyed, six of them on account of injury and ten because of old age or infirmity, while the remaining seven animals were accidentally killed.

Only a few of the specimens are here described. They are typical of the whole, and the features presented by them are indicative of the microscopical

condition of the remainder, the symptoms varying largely only in degree, much less so in kind.

For purposes of comparison of the amounts of dust in the different specimens, the system of giving a numerical value to the amount of dust present was adopted, the specimen containing the most dust being given the number 10, that containing the least number 1, and the remainder of the specimens being graded by these. This "dust value" is an absolute, though arbitrary, factor, while a relative value—the "work-dust factor"—is arrived at by dividing the dust value by the number of years of service of the animal underground.

The macroscopic appearance of the specimens varied considerably. Some were of a grey colour, with distinct punctiform areas of pigmentation in the lung substance and a varying degree of pigmentation in the form of a more or less complete layer in the deeper layers of the pleura and in the lung substance immediately adjacent to it. In such specimens there was very seldom more than a slight degree of congestion, and the pleura was almost invariably wrinkled on account of collapse. On the other hand, in many of the specimens the pleura was smooth and apparently stretched, while the lung was so congested that it appeared dark brown. In such cases pigment was often invisible to the unaided eye.

The poor state of preservation of many of the specimens was undoubtedly due to the fact that they were despatched from the colliery in far too small a bulk of fixative, such liquid as was present on arrival at the laboratory being in one or two cases little more than a dilute solution of formaldehyde in the autolysis products of the tissues.

In other instances the tissue was taken from the animals some time after death, as was shown by the presence within the blood vessels of bacteria, which had probably arrived in the lung by development of a *post mortem* vascular infection from the gut.

P.P. 1. Nineteen years old. Cause of death not stated. Worked eleven and a half years underground. Dust used: ordinary pit shale.

Macroscopically: Scattered black pigment throughout lung substance. Pigment areas small and discrete.

Microscopically: Some congestion. Slight haemorrhage into alveoli; slight oedema. Some patchy thickening of alveolar epithelium. Nodules of lymphoid tissue, generally perivascular and peribronchial, contain dense aggregations of dust. Dust cells in fair numbers in alveolar walls, and occasionally free within alveoli. No fibrosis.

Dust value 3. Work-dust factor 0.261.

P.P. 10. Age and cause of death not stated. Worked six years underground. Dust used: fireclay.

Macroscopically: A small specimen, very shrunken. Subpleural pigmentation; very fine general pigmentation of lung substance.

Microscopically: Mild bronchitis; patchy bronchial catarrh. Bronchial epithelium contains some dust. Dust cells free within most bronchi—some bronchi literally plugged with them. Alveolar epithelium swollen, but no desquamation. No congestion. Dust cells

in large numbers in alveolar epithelium; some free in alveoli. There is a large amount of perivascular and peribronchial dust; fair amount subpleurally. No fibrosis.

Dust value 5. Work-dust factor 0.834.

P.P. 12 a. Age not stated. Destroyed on account of old age and consequent inability to do a day's work. About nine years exposed to roof bind dust.

Macroscopically: Fair amount of general pigment.

Microscopically: Marked congestion. Some broncho-pneumonia. Considerable amount of dust perivascularly and peribronchially; slight amount subpleurally. Much intracellular dust in alveolar walls. Dust cells free in alveoli and occasionally in bronchi. Formol precipitate present. No fibrosis.

Dust value 6. Work-dust factor 0.667.

P.P. 12 b. Age not stated. Destroyed on account of old age. About nine years exposed to roof bind dust.

Macroscopically: Very little pigment visible.

Microscopically: Patchy congestion. Some perivascular, peribronchial and subpleural aggregations of dust. Only a few dust cells in alveolar walls; a few free within bronchi. Formol precipitate present. No fibrosis.

Dust value 3. Work-dust factor 0.334.

P.P. 12 c. Age not stated. Destroyed on account of old age. About nine years exposed to roof bind dust.

Macroscopically: No pigment visible.

Microscopically: Lung substance approximately normal. Very little dust; a few small aggregations peribronchially; a few dust cells in alveolar epithelium. No fibrosis.

Dust value 2. Work-dust factor 0.223.

P.P. 12 d. Age not stated. Destroyed on account of old age. About nine years exposed to roof bind dust.

Macroscopically: Very slight general pigmentation.

Microscopically: Slight patchy early broncho-pneumonia with congestion. Slight amount of perivascular, peribronchial and subpleural dust. Dust cells in alveolar walls and free within bronchi. No fibrosis. Formol precipitate present.

Dust value 3. Work-dust factor 0.334.

P.P. 13 b. Age not stated. Killed at work. Two and a half years exposed to inert ground shale.

Macroscopically: Lung grey-pink. No subpleural pigmentation. Very faint pigmentation of lung substance.

Microscopically: Lung substance approximately normal save for some collapse. Dust cells in alveolar epithelium. Some perivascular and peribronchial, less subpleural dust. Occasional dust cells in bronchi. No fibrosis.

Dust value 2. Work-dust factor 0.8.

P.P. 16. Age not stated. Destroyed on account of a broken back. Twelve years exposed to ground fireclay.

Macroscopically: A very shrunken specimen, very faintly pigmented. Somewhat congested.

Microscopically: Marked congestion; bronchitis. Slight amount of normal tissue. Much dust, scattered, perivascular and peribronchial, with fair amount subpleurally. Considerable degree of *post mortem* change. One small area at periphery of section contains some Gram-negative diplococci. These few probably adventitious (from the adhesive solution used). No fibrosis.

Dust value 6. Work-dust factor 0.5.

P.P. 18. Age not stated. Killed. Worked twelve years underground. Dust used: inert ground shale.

Macroscopically: Fine subpleural pigmentation. Abundant pigmentation in lung substance. Part of specimen shows an area of pneumonia, markedly consolidated.

Microscopically: Patchy congestion; haemorrhage into alveoli in places. Much perivascular, peribronchial and subpleural dust. *Post mortem* change. No fibrosis.

Dust value 7. Work-dust factor 0.583.

P.P. 23 *a.* Sixteen years old. Natural death. Twelve years underground. Dust used: pit stone.

Macroscopically: No subpleural dust, but streaky pigmentation of lung substance.

Microscopically: Patchy thickening of alveolar epithelium; congestion in these areas. Perivascular and peribronchial dust, with some subpleurally. Fair numbers of dust cells in alveolar epithelium; some free in alveoli; fair number in bronchial lumina. No fibrosis. *Post mortem* change.

Dust value 3. Work-dust factor 0.25.

P.P. 25. Age not stated. Destroyed, since worn out. Fifteen years exposed to dust ground from shale.

Macroscopically: A good deal of subpleural pigmentation. Lung substance heavily charged.

Microscopically: Some patchy broncho-pneumonia; good deal of subpleural collapse; pleura very wrinkled. Large amounts of perivascular and peribronchial dust; less subpleurally. Good deal of dust in alveolar epithelium. A few dust cells free in bronchi. *Post mortem* change. No fibrosis.

Dust value 8. Work-dust factor 0.534.

P.P. 30. Thirteen years old. Natural death. Worked eight to nine years exposed to grey bind dust.

Macroscopically: Very slight subpleural pigmentation, also some pigment in lung substance.

Microscopically: Intense congestion; bronchitis and broncho-pneumonia, with oedema and haemorrhage into alveoli. In many cases alveoli bounded by naked beaded capillaries. Very little dust indeed seen, and that only in dust cells. No fibrosis.

Dust value 1. Work-dust factor 0.077.

P.P. 32. Twenty-one years old. Destroyed. Seventeen years exposed to ground shale.

Macroscopically: Hardly any pigmentation, either subpleurally or in lung substance.

Microscopically: Bronchitis; congestion; oedema. Some dust aggregations, but they were very few and small. Dust cells in alveolar epithelium and free in alveoli and bronchi. Early *post mortem* change (desquamation of bronchial epithelium). No fibrosis.

Dust value 2. Work-dust factor 0.117.

P.P. 44. Ten and a quarter years exposed to white shale dust. No other particulars.

Macroscopically: Lung substance very slightly pigmented. Streaks of pigment under pleura.

Microscopically: Some collapse at periphery of specimen. Small area of early broncho-pneumonia. Fair amount of perivascular, peribronchial and subpleural dust. Dust in interalveolar septa and in alveolar walls. Lung otherwise normal. No fibrosis.

Dust value 4. Work-dust factor 0.395.

P.P. 47. Eleven years exposed to ground roof bind. No other particulars.

Macroscopically: Very little pigment visible. Lung red-brown.

Microscopically: Fair degree of congestion. Small amount of dust present—mostly intracellular. Numerous dust cells free and attached. Some small perivascular and peri-

bronchial dust nodules just below pleura; a few very small aggregations subpleurally. Many of the dust cells have numerous small vacuoles in the (generally) large cytoplasm. Occasional collections of red blood corpuscles in alveoli and bronchi. They are probably artefacts, since in many cases they lie on the tissues. No fibrosis.

Dust value 2. Work-dust factor 0.182.

STATISTICAL.

Of the fifty-seven specimens received, no account is taken of No. 9 *a*, since no particulars of the animal were received, or of No. 29, since the specimen was in such an advanced state of decomposition that microscopic examination was obviously useless.

In the specimens considered statistically below, the following animals were also omitted: P.P. 8, since the animal worked underground for sixteen years, out of which period it was exposed to stone dust (ground fireclay) for only nine years; P.P. 11, since it worked underground for ten years, being exposed to stone dust (blue stone) for only two years; P.P. 15, since during its work period it was exposed to two dusts—shale (two years eleven months) and CaCO₃ (three months); and P.P. 27, since it was exposed to dust (CaCO₃) for four and a half years, but had previously worked an unknown period in another pit, where, presumably, it was exposed to stone dust, which may or may not have been CaCO₃.

The fifty-one specimens analysed statistically give the following data:

Average dust value for fifty-one animals	3.55
Average dust value in animals exposed to dusts whose nature is stated (forty-seven animals)	3.62
Average dust value in animals exposed to dusts whose nature is not stated (P.P.'s 4, 6, 33 and 40)	2.75
Average dust value for animals exposed to shale and pit stone, excluding those exposed to extra amounts of ground fireclay, Bute clod and shale dust	3.2
Average dust value for animals exposed to extra quantities of ground fireclay, Bute clod and shale dust (P.P.'s 10, 16, 25, 35, 36)	7.2

Since the dust value is a factor varying directly only with the amount of dust present, it is of comparatively little value for purposes of comparison. The work-dust factor, on the other hand, is a relative factor, and takes into consideration the work period, and enables one to study the rate of deposition of dust in the lung. If coal and stone dust accumulated in the lung progressively, the work-dust factor would tend to remain a constant or would only slightly decrease. It will be seen that there is a marked tendency towards a mathematical decrease, especially up to a work period of ten years. Had more specimens with a work period of ten years and over been received, it is likely that the tendency would have been extended.

The average work-dust factor table shows quite clearly that there is but slight tendency to progressive deposition of dust in the horse's lung.

Average Work-Dust Factor for various Work Periods.

Years	No. of animals	Factor	Years	No. of animals	Factor
2-3	8	1.309	9-10	5	0.511† (0.389)
3-4	5	0.796	10-11	2	0.450
4-5	4	0.765	11-12	3	0.300
5-6	5	0.706	12-13	4	0.366* (0.340)
6-7	2	0.670* (0.5)	15	1	0.533‡
7-8	5	0.428	17	1	0.118
8-9	6	0.408† (0.295)			

* Including one animal heavily exposed to ground fireclay.

† Including one animal heavily exposed to Bute clod.

‡ This animal was heavily exposed to shale dust.

The pits from which these animals were taken had been much more heavily stone-dusted than usual. The values in brackets are those arrived at by omitting these animals from the calculations.

Average work-dust factor for fifty-one animals	0.513
Average work-dust factor for animals exposed to dusts whose nature is stated (forty-seven)	0.504
Average work-dust factor for animals exposed to unknown dusts	0.688
Average work-dust factor for animals exposed to shale and pit stone	0.478
Average work-dust factor for animals exposed to extra amounts of ground fireclay, Bute clod and shale dust	0.720
Average work-dust factor for animals exposed to shale and pit stone over the same period as those exposed to the extra amounts of ground fireclay, Bute clod and shale dust (i.e. six years upwards)—twenty-four animals	0.335

It is of course explicit that the figures are based primarily upon a value—the dust value—which is arbitrary. But the writer would make clear that the gradation of the values is as accurate as a purely observational estimation can be, and expresses the differences in the amounts of dust in the various specimens with ample accuracy for purposes of comparison, which is the only purpose the writer had in view.

The dust values were checked by making a second series of estimations, *at one sitting* (in order to reduce to the minimum any variation of the personal equation), on preparations in which all distinguishing marks were hidden.

DISCUSSION.

The degree of danger to health of an inhaled insoluble dust may be broadly stated to be a function of the readiness with which the dust is eliminated. It is abundantly clear from the examination of these specimens that there is but slight tendency to progressive accumulation of dust in the lungs of pit ponies exposed to coal and stone dust.

In the first two years' work underground the dust accumulates in the lung until there is a dust value of about 3. At the end of this period the mechanism of elimination of the dust is apparently able to cope with the dust in such a manner that the amount excreted is approximately equal to the amount inhaled, so that there is only a slight increase, if any, in the amount of residual dust in the lung.

It is not suggested that the dust accumulating in the lung in the first two years of exposure remains permanently *in situ*, but rather that it is pro-

gressively eliminated and replaced by dust freshly inhaled. It is probable that, if a dusted animal were employed in a dust-free atmosphere for some time, a large amount of the dust in its lungs would be eliminated. The writer had occasion, in May, 1919, to examine the sputum of a bronchitic man, in civilian life a collier, who had joined the Army in February, 1915, and who since enlistment had not worked in a dusty atmosphere. Macroscopically, the sputum contained black streaks, and the microscope showed large numbers of dust-containing phagocytes. The morning sputum presented the same picture at several successive examinations. It would seem, then, that dust was being excreted which had been inhaled at least four years previously.

Since phagocytosis of coal and stone dust is brisk in the lung of the pit pony, it is indicated that there is little danger of permanent damage to the lung, and this is confirmed by the microscopical examination: in none of the specimens examined is there any sign of permanent lesions attributable to the dust.

In only two specimens was there any evidence of serious affection of the lung, and in neither case could the lesions be ascribed to the effects of the dust. Specimen No. 20 contained a healing infarct: unfortunately the specimen was a tiny one from the edge of the lung, and was too small for the infarct to be traced back to its point of origin. Specimen No. 46 had a massive pneumonia. The veterinary surgeon's report stated that the animal died from lockjaw. Although only a small amount of lung was received, the severity of the lesions was such that the pneumonia was probably the immediate cause of death.


The stone dusts used for dusting were, in all cases save two, ground from pit stone, *i.e.*, stone in which the coal strata lie. The two exceptions were P.P. 15 and P.P. 27. In the former case the dust used was shale for two years eleven months, and "Electric dust" (CaCO_3) for three months. The specimen had a dust value of 4, which gives it a high work-dust factor for its work period, *i.e.* 1.38. It was unfortunate that the lung was so autolysed that it was useless save for the mere estimation of the amount of dust present. All that can be said is that there was no apparent fibrotic response.

P.P. 27 was exposed to calcium carbonate—origin not stated—for four and a half years, but had previously worked for an unknown period in another pit. In this case, the dust value was only 3, and the lung showed no sign of damage greater than that present in specimens exposed to shale dust, while the amount of dust present is less than that usually found in animals exposed to shale for even four and a half years. It may be taken, then, that the high work-dust factor in P.P. 15 was not due to the inhalation of calcium carbonate for three months, since this dust, inhaled over a much longer period is, on the rather unsafe analogy presented by one case, even less harmful than shale.

P.P.'s 8, 10 and 16 were exposed to dust ground from fireclay.

P.P. 8 (destroyed on account of injury) shows a very heavy amount of dust—the most met with in the investigation. The animal was exposed to stone dust for only nine of its sixteen years' service underground. Little, unfortunately, can be said as to the cellular response of the lung to the dust, on account of pronounced *post mortem* change.

P.P. 10 (cause of death not stated) was exposed to the dust for six years; the specimen is in a very fair state of preservation. It has a dust value of 5, and a work-dust factor of 0.834—much above the average for that work-period. There are large deposits of dust around the bronchi and blood vessels, with less subpleurally. Numerous dust cells are to be found in the alveolar walls, and in many cases plugs of dust cells free in the bronchi (see Fig. 5, Pl. VI, and Text-fig. 1).



Text-fig. 1. Camera lucida drawing. About 1200 diameters magnification.

P.P. 10. Dust value 5, work-dust factor 0.834. Dust used: fireclay. Cause of death not stated.

Group of large, somewhat degenerate cells, loaded with dust, lying free within a small bronchus. Compare with Pl. VI, fig. 5.

P.P. 16 (destroyed on account of injury), exposed to the dust for twelve years, has a dust value of 6, and a work dust factor of 0.5—again above the average—but *post mortem* change, as in P.P. 8, renders high-power observation impossible.

P.P. 25 (destroyed on account of old age) was stated to have been exposed to extra heavily applied shale dust for fifteen years. The specimen has a dust value of 8, and a work-dust factor of 0.534.

P.P. 35, eight years exposed to extra heavily applied Bute clod (a soft pit stone), has a dust value of 8, and a work-dust factor of 1.00, while P.P. 36,

exposed to the same dust to a similar extent for nine years, has a dust value of 9, and a work-dust factor of 1.00.

The six animals mentioned above have work-dust factors so much above the average for their respective work periods that the writer made enquiry as to the nature of the dusts used. He was informed that these dusts are ordinary pit stones, but that the pits in which these animals had worked were extra heavily stone-dusted. It is obvious from the examination of the specimens in question that excessive stone-dusting leads to extra accumulation of dust within the lung. While it can be fairly definitely said that this causes no permanent lesion in the lung—since these animals had long work periods, and yet showed no fibrotic change—it would seem possible that a certain degree of mechanical interference with the normal functioning of the lung would be caused by such heavy deposits of dust. Hence it does not seem desirable to apply more stone dust than is necessary.

According to this investigation, all the forms of pit stone used for dusting are equally harmless, if not present in excessive amounts. Even under the latter conditions, no permanent damage to the lung substance occurs in animals exposed over long periods.

Although bacteria were present in many of the specimens, the infection was in all cases *post mortem*, and was only found in those specimens showing a greater or lesser degree of *post mortem* change.

Since the earliest manifestation of *post mortem* change in the specimens was the presence of the precipitate formed by formaldehyde with some decomposition product of blood, care was necessary to avoid confusion of this precipitate with dust. The two are distinguishable by the fact that the precipitate is in the form of minute spherical granules (enlarging with progressive decomposition), as opposed to the generally irregular particles of dust, and by the fact that the precipitate is always found in the blood vessels, tending to aggregate around the leucocytes. On cursory examination, such leucocyte-aggregations simulate dust cells.

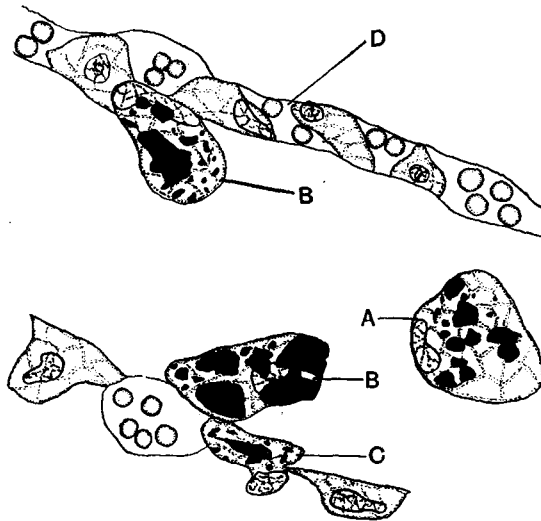
The variation of the individual response to the dust is illustrated by specimens 12 *a*, 12 *b*, 12 *c*, and 12 *d*. These four animals worked for nine years in the same pit, and were destroyed on account of old age. Although all the animals were subjected to the same conditions, one had a dust value of 6 and the others of 3, 2 and 3 respectively. This individual variation must be borne in mind when examining the condition of single specimens: in the statistics as a general rule the number of animals is sufficient to neutralise it.

DISTRIBUTION OF THE DUST.

As is to be expected, there is always a certain amount of dust in cells lying on, or in, the alveolar epithelium. Frequently these phagocytes are found free in the lumina of the bronchi, and, rarely, in the alveoli. Occasionally recently inhaled particles are found closely applied to the walls of the alveoli, but not yet ingested by phagocytes.

The massive deposits of dust are found in association with the perivascular, peribronchial and subpleural lymph plexuses. The heaviest deposits are nearly always perivascular, while large aggregations of dust are seldom found in the lower layers of the pleura unless there is a considerable amount of dust in the lung—*i.e.* the dust is deposited primarily in the loose connective tissue around the blood vessels, next around the bronchi, and finally beneath the pleura. The dust deposits are almost invariably more heavy around the smaller blood vessels and bronchi than around the larger ones.

There would seem, however, to be a “drift” of the dust towards the pleura, since in all cases where aggregations of dust (as opposed to dispersed, *i.e.* intracellular, dust) exist, they are found in much smaller number near the pleura than deep in the lung substance.



Text-fig. 2. Camera lucida drawing. About 1200 diameters magnification.

P.P. 10. Part of alveolus, showing, at *A*, a dust cell free within the alveolus. *B*, two dust cells in different stages of detachment. *C*, dust cell in alveolar wall. *D*, undulating capillary cut approximately longitudinally.

Undoubtedly a certain amount of the dust in this situation is migratory, in the sense that it is being carried in the lymphatics from deeper in the lung to the subpleural lymph plexus, but it is suggested that the almost invariable presence of a greater amount of dispersed dust in that part of the lung nearest the pleura is due to the greater difficulty of elimination of dust cells *via* the bronchi from that region than from the more central parts of the lung. The subpleural dust is probably largely eliminated *via* the lymphatics, which process is slower than that of bronchial elimination, and consequently creates a tendency to accumulation.

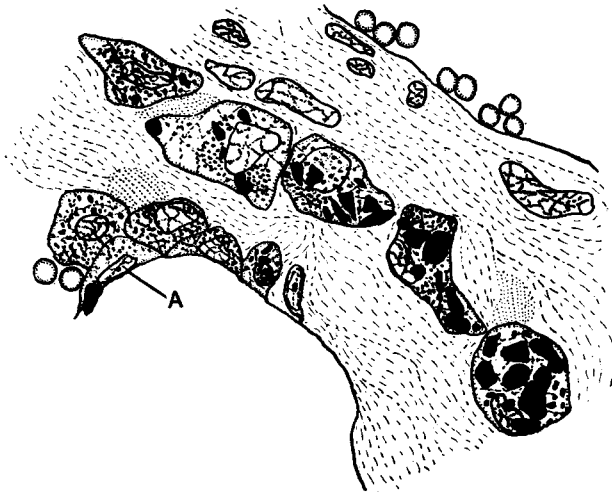
In animals with a high dust value, the course of the lymphatics, even in the interalveolar septa, is everywhere marked by the presence of dust.

Scattered lymph nodules are comparatively rare in the horse's lung, but

are sometimes found at the bifurcation of small bronchi. When present in animals having a dust value of 4 or more, they are always loaded with dust, sometimes so much so that the lymphocytes are almost completely hidden.

In specimens with a high dust value it is generally very difficult to demonstrate cell outlines around the dust in the massive deposits. In Text-fig. 3, however, is shown dust in the wall of a branch of the pulmonary vein. This specimen has only a low dust value, and the perivascular and peribronchial aggregations are comparatively small, so that the dust does not obscure the cells as is almost invariably the case in the more heavy deposits.

The writer has to thank Captain F. J. Moon, M.R.C.V.S., for the opportunity of examining specimens of nasal mucosa, spleen, bronchial and ab-



Text-fig. 3. Camera lucida drawing. About 1200 diameters magnification.

P.P. 47. Eleven years exposed to roof bind dust. Dust value 2, work-dust factor 0.182.

Section through the wall of a branch of the pulmonary vein, showing intracellular dust lying in the perivascular connective tissue.

In the wall of an adjoining alveolus, at *A*, is a cell which is in process of ingesting a large dust particle. The neighbouring cells contain very fine dust particles, and are characteristic of cells, very commonly seen, whose phagocytic power is apparently not yet exhausted. Cells in this condition are much less often seen free than those containing large particles.

dominal lymph glands, which were taken from P.P. 18, having a dust value of 7.

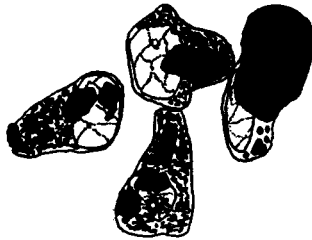The nasal mucosa was absolutely free from dust, both macro- and microscopically.

The spleen contained a large amount of dust, but, save for the fact that the Malpighian corpuscles were dust-free, little could be seen on account of marked autolysis.

The two lymph glands were not distinguished from each other by labels, but one contained more dust than the other, and was, presumably, a bronchial gland. Apart from the relative amounts of dust in the two glands, there is

little difference between them. They are both packed with dust, which is uniformly spread over the glands, with the exception of the lymph nodules, which are practically dust-free. There are some aggregations of dust around the blood vessels of the capsule.

The dust in the lymph glands is intracellular. The dust cells are large palely staining cells having large, pale, somewhat degenerate-looking nuclei. The accumulation of dust by such a cell often proceeds to a degree where the cell is enormously enlarged and every vestige of structure hidden by the mass of dust within the cell. Many of the dust particles, not only in the lymph glands, but in the massive aggregations of dust in the lung, are of considerable



Text-fig. 4. Camera lucida drawing. About 1200 diameters magnification.

P.P. 18. Twelve years exposed to shale dust. Dust value 7, work-dust factor 0.583.

Four cells from the medulla of a lymph gland. The majority of the cells contain much more dust than these—so much so that very little cell structure can be seen. Much of the dust is in the form of aggregations of very small, rather than large, single, particles.

size—often from two to four micra in length. The majority of the dust in the lymph glands, however, appears in the form of apparently spherical dust particles within the cells, and give the impression that they have been formed by the coalescence of several of the very small particles such as are characteristic of the dust content of those phagocytes in the lung which are still attached to the alveolar wall (see Text-fig. 4).

The phagocytes found free within the alveoli and bronchi differ from those remaining attached in that the former almost invariably contain more dust, and that in larger particles, than the latter (see Text-figs. 2 and 3).

SUMMARY.

The inhalation of coal and stone dust, as used in collieries, by pit ponies produces no permanent lesions of the lungs.

The dusts accumulated in the lung continue to increase during the first two years of exposure (approximately), but the rate of elimination then becomes equal to that of absorption.

The dusts accumulate, probably in the lymphatics, firstly around the blood vessels, secondly around the bronchi, and thirdly in the deep layers of the pleura.

The dusts accumulate in greater amount around the smaller blood vessels and bronchi than around the larger ones.

There is a greater deposition of dust near the pleura than deeper in the lung substance.

The dust is eliminated *via* the bronchi and the lymphatics.

Dust accumulates in the lymph glands and spleen. In the former, at least, it is largely intracellular.

Excessive stone-dusting causes extra accumulation of dust within the lung: this, however, causes no fibrosis.

All forms of the soft pit stone used were equally harmless.

The normal horse's lung contains very little dust.

REFERENCES.

- BEATTIE (1912). A Comparative Study by Experiment of the Effect produced on the Lungs by the Inhalation of Coal Dust, etc. Appendix to *Parl. Papers: Explosions in Mines Committee Reports*, I-VI. 12.
- CARLETON (1924). The Pulmonary Lesions Produced by the Inhalation of Dust in Guinea-Pigs. *Journ. of Hygiene*, XXII. 438-472.
- MAVROGORDATO (1918). Experiments on the Effects of Dust Inhalation. *Ibid.* XVII. 439.

EXPLANATION OF PLATE VI.

All the microphotographs were taken with a Leitz "Micca" microphotographic attachment and Zeiss achromatic objectives.

All the microphotographs are untouched.

- Fig. 1. P.P. 36. Dust value 9. View of much autolysed lung after removal of formol precipitate, showing massive deposits of dust near the pleura. $\times 36$.
- Fig. 2. P.P. 10. Dust value 5. View of lung near pleura, showing distribution of dust around a blood vessel cut approximately longitudinally. Some subpleural, peri- and intra-bronchial dust. Subpleural collapse to the degree present in the figure was general in the specimens. $\times 36$.
- Fig. 3. Control horse No. 6. Small deposits of perivascular and peribronchial dust at \times . Some dust cells within bronchi. No dust deposits larger than these were found in any of the controls. $\times 36$.
- Fig. 4. P.P. 50. Dust value 3. View of pleura, showing distribution of dust in its lower layers, at \times . $\times 157$.
- Fig. 5. P.P. 10. Dust value 5. Plug of dust, largely intracellular, within bronchus. Peribronchial dust deposits. $\times 157$.
- Fig. 6. P.P. 18. Intracellular dust in medulla of lymph gland. $\times 157$.

(MS. received for publication 30 XI. 1925.—ED.)

