

## Research Note

# Natural infection of the gerbil *Meriones lybicus* with the metacestode of *Taenia endotheracicus* in Arak, central Iran

G.R. Mowlavi\*, E.B. Kia and I. Mobedi

Department of Medical Parasitology and Mycology, School of Public Health and Institute of Public Health Research, Tehran University of Medical Sciences, PO Box 6446-14155, Tehran, Iran

### Abstract

Polycephalic larvae of *Taenia endotheracicus* were found from naturally infected gerbils *Meriones lybicus* in a rural area of Arak, central Iran. A large cyst containing 19 protoscolices was located in the peritoneum, attached to the large omentum. The characteristics of the protoscolices and rostellar hooks confirmed the identification of these larvae as *T. endotheracicus*.

The red fox (*Vulpes vulpes*) is the definitive host for *Taenia endotheracicus* (Kirschenblatt, 1948) and rodents, including *Meriones* spp., *Rhombomys opimus* and *Gerbillus pyramidus hirtipes* act as intermediate hosts (Abuladse, 1964). Adult worms of *T. endotheracicus* have previously been isolated from *V. vulpes* in Dashte-moghan, Ardabil province, Iran (I. Mobedi, unpublished data). The natural occurrence of larval stages of this cestode in a new intermediate host species, *Meriones lybicus* is recorded in this paper, from a rural part of Davood-Abad, countryside of Arak, central Iran.

In the winter of 2002, during an investigation on helminth parasites of wild reservoirs of central Iran, one pregnant female of *M. lybicus* was captured alive after setting traps near the entrance burrows of this rodent population. The identification of *M. lybicus* was confirmed after Etemad (1978). Davood-Abad is an area about 5 km<sup>2</sup>, having a semi-desert climate with small hills, covered by desert plants such as alhagi. This area has favoured the presence of predator–prey relationships between carnivores, mainly *V. vulpes*, the jackal *Canis aureus* and birds of prey, all of which feed upon small mammals such as *M. lybicus*.

Macroscopical examination of *M. lybicus*, after autopsy, revealed the presence of a large white and web-shaped

cyst (measuring 35 mm in diameter) in the peritoneum, attached to the lower curve of the omentum. When removed and excised, the fully developed cyst was found to contain fluid and 19 invaginated scolices, attached to the cyst wall (fig. 1). Three protoscolices were stained by acetocarmine, squashed between glass slides and cover-slips and their morphological characters studied under a light microscope. Each protoscolex had a scolex of 1.7 to

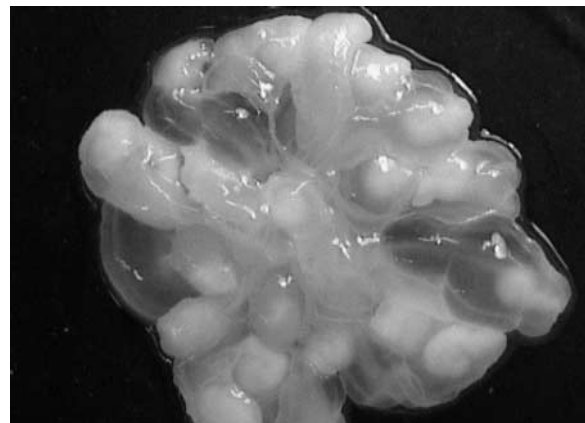


Fig. 1. Fully developed cyst of *Taenia endotheracicus* from the thoracic cavity of *Meriones lybicus*. Scale bar = 10 mm.

\*Fax: (0098 21) 6462267  
E-mail: molavig@yahoo.com




Fig. 2. Rostellar hooks of *Taenia endotheracicus* larvae. Scale bar = 200  $\mu\text{m}$ .

1.9 mm in diameter, and four suckers of 350 to 400  $\mu\text{m}$  in diameter. The rostellum had a row of large hooks and a row of small hooks, which were 325–330  $\mu\text{m}$  and 185–188  $\mu\text{m}$  in length, respectively (fig. 2).

This is the first report of *T. endotheracicus* larvae in *M. lybicus*. The only previous finding of *T. endotheracicus* larvae in Iran was the larval stage from a naturally infected *M. blackleri* from Ghazvin, Iran which was used by Verster (1969) as type material for the description of the rostellar hooks.

The results of the present study and that of Ganzorig *et al.* (1998), who found *T. endotheracicus* in *M. meridianus* and *M. unguiculatus* in Mongolia, suggest that different species of *Meriones* are naturally susceptible to *T. endotheracicus*.

### Acknowledgements

The authors would like to thank Mrs F. Zahabiun and Mr A. Rahimi for their kind cooperation. This study was financially supported by the Institute of Public Health Research, Tehran University of Medical Sciences.

### References

- Abuladse, K.I.** (1964) Taeniidae – cestodes of animals and man and the diseases they provoke in Skrjabin, K.I. (Ed.) *Principles of cestodology*. Vol. IV. Moscow, Acad. Nauk USSR (in Russian).
- Etemad, E.** (1978) *Mammals of Iran. Vol. I: Rodents and key to their identification*. National Society of Natural Sources and Human Environment Protection Publications (in Persian).
- Ganzorig, S., Sumiya, D., Batsaikhan, N., Schuster, R., Oku, Y. & Kamiya, M.** (1998) New findings of metacestodes and a pentastomid from rodent in Mongolia. *Journal of the Helminthological Society of Washington* **65**, 74–81.
- Verster, A.** (1969) A taxonomic revision of the genus *Taenia* Linnaeus, 1758 s. str., *Onderstepport Journal of Veterinary Research* **36**, 3–58.

(Accepted 7 November 2003)

© CAB International, 2004