


Aortic valve replacement using On-X valve in a child postorthotopic heart transplantation

Adam James¹, Ross Foley¹, Helene Murchan¹, Asif Hasan³, Fabrizio DeRita³, Zdenka Reinhardt² and Colin J. McMahon^{1,4,5} 

Brief Report

Cite this article: James A, Foley R, Murchan H, Hasan A, DeRita F, Reinhardt Z, and McMahon CJ (2023) Aortic valve replacement using On-X valve in a child postorthotopic heart transplantation. *Cardiology in the Young* **33**: 485–486. doi: [10.1017/S1047951122002001](https://doi.org/10.1017/S1047951122002001)

Received: 6 May 2022

Revised: 7 June 2022

Accepted: 7 June 2022

First published online: 30 June 2022

Keywords:

Aortic valve replacement; cardiac transplantation

Author for correspondence:

Professor Colin McMahon, Department of Paediatric Cardiology, Children's Health Ireland, Crumlin, Dublin 12, Ireland.
Tel: 01-4096160; Fax: 01-4096181.
E-mail: cmcmahon992004@yahoo.com

¹Department of Paediatric Cardiology, CHI Crumlin, Dublin 12, Ireland; ²Department of Cardiac Transplantation, Freeman Hospital, Newcastle, England, United Kingdom; ³Department of Cardiothoracic Surgery, Freeman Hospital, Newcastle, England, United Kingdom; ⁴School of Medicine, University College Dublin, Belfield, Dublin 4, Ireland and ⁵School of Health Professions Education, Maastricht University, Maastricht, Netherlands

Abstract

A 20-month-old girl presented with severe dilated cardiomyopathy and decompensated congestive cardiac failure. Despite escalating inotropic and mechanical ventilation support, she required placement on extracorporeal membrane oxygenation and transfer to the transplant centre in Newcastle, England. She was placed on biventricular assist device and then Berlin Heart but failed to show any recovery of ventricular function. She underwent orthotopic heart transplantation at 2 years of age. She developed bacterial endocarditis with *Enterococcus faecalis* resulting in severe aortic valve regurgitation requiring aortic valve replacement with a 19 mm On-X valve (Airtivion) 11 days after her transplant. Given the size of the donor heart, it was possible to implant a 19-mm valve in this 12 kg child with minimal risk of patient prosthesis mismatch. She was anticoagulated with warfarin (On-X valve INR 2-3 for first 3 months; INR 1.5-2.0 thereafter). Although she suffered several other post-operative complications, including malabsorption, nasojejunal feeding, liver dysfunction, vertebral fractures, renal impairment and renal calcification, and need for repeat opening of her tracheostomy site following her initial decannulation, her aortic valve function has remained stable.

A 3-year-old girl presented at 20 months-of-age with respiratory distress and low cardiac output. Her cardiac examination and echocardiogram confirmed severe dilated cardiomyopathy and decompensated congestive cardiac failure. She was intubated ventilated and started on intravenous inotropes. After transfer to the national paediatric cardiology unit, her echocardiogram confirmed severe dilated cardiomyopathy/myocarditis with severe LV dilatation and reduced LV systolic function (LV fractional shortening 10–15%). Initial nasopharyngeal aspirate was positive for adenovirus and rhinovirus.

Despite escalating inotropic and mechanical ventilation support, she required placement on extracorporeal membrane oxygenation due to persistent decompensated cardiac failure despite maximal ventilatory and inotropic support. Cardiomyopathy and myocarditis work-up failed to identify an underlying aetiology. Given her need for ventricular assist device support and listing for orthotopic heart transplant, she was transferred by air ambulance to the transplant centre in

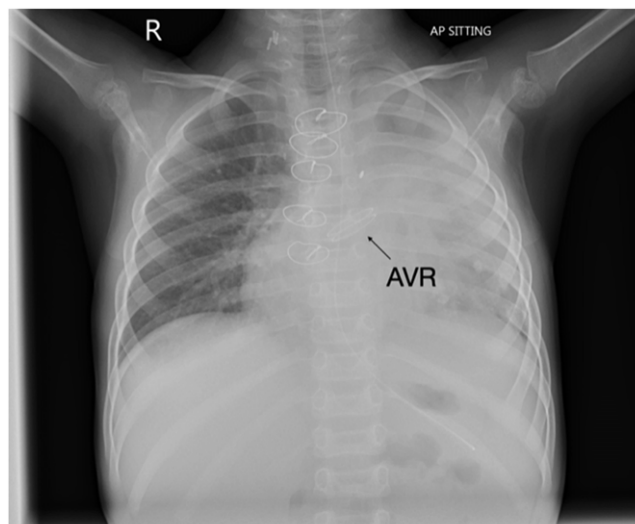


Figure 1. Chest radiograph demonstrating bileaflet On-X aortic valve.

© The Author(s), 2022. Published by Cambridge University Press. This is an Open Access article, distributed under the terms of the Creative Commons Attribution licence (<http://creativecommons.org/licenses/by/4.0/>), which permits unrestricted re-use, distribution and reproduction, provided the original article is properly cited.

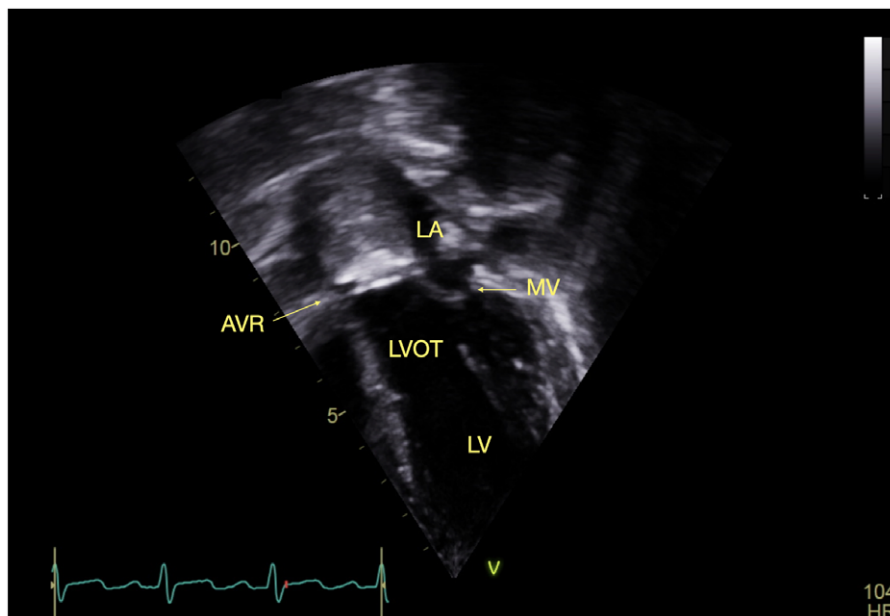


Figure 2. Transthoracic echocardiogram four chamber view demonstrating On-X valve in situ.

Newcastle, England. Two days after arrival in the transplant centre she was placed on biventricular assist device but failed to show any recovery of ventricular function. She had a Berlin heart inserted 2 days after she was placed on biventricular assist device. She underwent orthotopic heart transplantation 3 months after transfer to transplant centre. She was initially treated with intravenous cyclosporin before transitioning to tacrolimus. Subsequently, she developed *Enterococcus faecalis* bacterial endocarditis resulting in severe aortic regurgitation. This was not amenable to valve repair and required aortic valve replacement (AVR) with a 19 mm On-X valve 11 days after her transplant.

She had a difficult post-transplant course and suffered several complications including malabsorption requiring nasogastric and then nasojejunal feeding, liver dysfunction, thoracolumbar osteoporotic wedging and compression fractures (treated with vitamin D), renal impairment with echogenic kidneys and adrenocortical insufficiency. She also developed several episodes of sepsis including Epstein–Barr viraemia, *Burkholderia cepacia*, *Stenotrophomonas maltophilia*, *Klebsiella oxytoca* and *Pseudomonas aureginosa* sepsis requiring several antibiotics including ceftolazone-tazobactam, micafungin and aztreonam with taurolidine nebulizers. She developed a pulmonary haemorrhage soon after her transplant and needed tracheostomy for left main stem bronchomalacia. Although she was decannulated she developed respiratory distress with repeated respiratory infections and subsequently needed her tracheostomy site reopened. Her most recent echocardiogram demonstrated good aortic valve function. She was anticoagulated with warfarin (On-X valve INR 2-3 for first 3 months; INR 1.5-2.0 thereafter).

This is the first reported aortic valve replacement in a child after cardiac transplantation using an On-X valve. Although attempted repair was contemplated, the valve destruction was too severe warranting replacement. Given the size of the donor heart, it was

possible to implant 19 mm valve in this 12 kg child with minimal risk of patient prosthesis mismatch. Her most recent echocardiogram demonstrated excellent prosthetic valve function with mild para-valve regurgitation, mild LV dilatation, global longitudinal strain -19% and left ventricular ejection fraction 60% (Simpson's biplane). Benefits of the On-X valve include its unique material and design characteristics compared with earlier generations of mechanical valve. The valve also can be used safely with less anticoagulation (INR 2-3 for first 3 months; INR 1.5-2 thereafter). (1). In a prospective randomized trial, patients using lower dose anticoagulation had at least 60% fewer bleeding events without any increase in their stroke risk (2). Furthermore, the valve has a much lower reoperation risk compared to bioprosthetic tissue valves. This report highlights the potential for successful outcome of AVR using the On-X valve post orthotopic heart transplant despite significant co-morbidities in this patient.

Acknowledgements. We would like to express our gratitude to Mr. John Russell, ENT surgeon and Ms. Marie Lavelle, Department of Paediatric Cardiology and Cardiac Transplantation, Children's Health Ireland. Mr Andrew Pendred kindly generated the images.

Financial support. This research received no specific grant from any funding agency, commercial, or not-for-profit sectors.

Conflicts of interest. None

References

1. Karkar AM, Castresana MR, Odo N, Agarwal S. Anticoagulation dilemma in a high-risk patient with On-X valves. *Ann Card Anaesth* 2015 Apr-Jun; 18: 257-260. DOI [10.4103/0971-9784.154496](https://doi.org/10.4103/0971-9784.154496).
2. Puskas JD, Gerdisch M, Nichols D, et al. Anticoagulation and antiplatelet strategies after On-X mechanical aortic valve replacement. *J Am Coll Cardiol* 2018 Jun 19; 71: 2717-2726. DOI [10.1016/j.jacc.2018.03.535](https://doi.org/10.1016/j.jacc.2018.03.535).