

Discordant Prenatal Phenotype and Karyotype of Monozygotic Twins Characterized by the Unequal Distribution of Two Cell Lines Investigated by Different Methods: A Review

Barbara Gentilin,¹ Silvana Gueneri,² Vera Bianchi,¹ Federica Natacci,¹ Augusto Colombo,³ Roberto Fogliani,³ Renato Fortuna,² Domenico A. Coviello,² Cristina Curcio,² and Faustina Lalatta¹

¹ *Clinical Genetic Unit, Dipartimento Salute della Donna, del Bambino e del Neonato, Fondazione Ospedale Maggiore Policlinico, Mangiagalli e Regina Elena, Milan, Italy*

² *Medical Genetic Laboratory, Dipartimento dei Servizi, Fondazione Ospedale Maggiore Policlinico, Mangiagalli e Regina Elena, Milan, Italy*

³ *II^A Obstetrics and Gynecology Unit, Dipartimento Salute della Donna, del Bambino e del Neonato, Fondazione Ospedale Maggiore Policlinico, Mangiagalli e Regina Elena, Milan, Italy*

We present the case of a monozygotic twin pregnancy discordant for phenotype and karyotype. A chorionic villus sample was performed at the 11th week of gestation in a primigravida because of cystic hygroma detected by ultrasound in one twin of a monochorionic, diamniotic pregnancy. Rapid testing by means of quantitative fluorescence polymerase chain reaction and conventional karyotyping, obtained by both short- and long-term culture, revealed a homogeneous monosomy X (45,X). Amniocentesis was performed separately for both twins before termination and showed an homogeneous monosomy X in one sample and a 46,X,del(X)(p11.1) karyotype in the other one. Postmortem fetal tissues culture confirmed the discordant karyotype between the two embryos. Placental samples obtained after termination revealed the cell line which was not detected at chorionic villus sampling. Based on this and previous reports, we suggest that in cases of a phenotypic discordance detected at ultrasound in the first trimester, it is advisable to perform a karyotype analysis on amniocytes because it better reflects fetal constitution rather than chorionic villi or lymphocytes in case of heterokaryotypic monosomy X monochorionic twins.

Monozygotic twins (MZ) are considered natural clones, but they are not necessarily phenotypically or genetically identical and a certain degree of discordance has been reported within MZ twin pairs. This phenomenon is most often due, but is not limited to, a postzygotic nondisjunction event leading to chromosomal mosaicism (Gilbert et al., 2002; Hall, 1996, 2003). Possible causes for genotypic differences also include an imbalance such as uniparental disomy, defects of imprinting or even twin-to-twin transfusion due to placental factors. Rohrer et al. (2004) have estimated that descriptions of two dozen cases of het-

erokaryotypic monochorionic twins discordant for Turner Syndrome had appeared in the literature so far, while Lewi et al. (2003) and Lewi et al. (2006) reported several cases of MZ twins with a discordant phenotype and a complete or partially discordant karyotype on different fetal tissues.

Since the advent of chorionic villus sampling (CVS) in the 1980's (Brambati et al., 1984; Simoni et al., 1983) the advantage of a rapid definition of the chromosomal constitution of the placenta has been stressed to allow the patient to obtain a relatively early diagnosis of chromosome aneuploidies.

One drawback of CVS is the well-known chance of confined placenta mosaicism, which is detected in about 1% to 2% of samples. In these cases chorionic villus sampling results can be a potentially misleading (Grati et al., 2006).

More recently, the introduction of quantitative fluorescence PCR (QF-PCR) seemed to be a step forward in the early diagnosis of major trisomies or monosomies. However, both CVS and QF-PCR have drawbacks which must be accounted for when dealing with monochorionic twins with a discordant phenotype (Cirigliano et al., 2001; Crane & Cheung., 1988; Hahneman & Vejerslev, 1997; Nicolini et al., 2004).

We report the case of a monochorionic diamniotic pregnancy in which first trimester nuchal translucency screening showed a major discordance between the fetuses and in which the QF-PCR and cytogenetic

Received 22 January, 2008; accepted 18 March, 2008.

Address for correspondence: Dr Faustina Lalatta, Clinical Genetic Unit, Dipartimento Salute della Donna, del Bambino e del Neonato, Fondazione Ospedale Maggiore Policlinico, Mangiagalli e Regina Elena, Via Commenda 12, 20122 Milano, Italy. E-mail: f.lalatta@policlinico.mi.it

studies of CV seemed concordant but, in contrast, revealed different results when other tissues were analyzed. These latter studies led to the more accurate diagnosis of a mosaicism whose cell lines were unequally distributed between the twins.

Clinical Data, Material and Methods

A 32-year-old primigravida underwent transabdominal chorionic villus sampling (CVS) at 11+2 weeks of gestation owing to a cystic hygroma detected by ultrasound examination in one twin (Twin 1) of a monozygotic, diamniotic pregnancy (see Figure 1A — Twin 1, and Figure 1B — Twin 2). A single sample of CV was taken for cytogenetic analysis.

Parents were aged 32 and 35 years respectively, healthy and not consanguineous. Both family histories were unremarkable and the pregnancy was spontaneous, no ovarian stimulation or in vitro fertilization (IVF) was performed.

The pregnancy was terminated at 15 weeks gestation following a rapid worsening of the ultrasound picture of the affected twin (Twin 1). No abnormali-

ties were noted in the other twin (Twin 2). At that time the patient was offered an amniocentesis (AF) from each sac because of the discordant phenotype of the two fetuses.

Chorionic villus tissue was isolated by removing maternal decidua. Rapid QF-PCR (quantitative fluorescence polymerase chain reaction) testing for aneuploidy was performed on DNA extracted using Instagene Gene Matrix (Biorad). Two multiplex PCR assays were performed. The first was for the analysis of markers on chromosomes 13, 18 and 21, co-amplified with the sex chromosome markers AMXY, HPRT and X22 (Figure 2A). A second assay included markers DX6803 and DX6809 (Figure 2B). The markers at polymorphic sites for the detection of X chromosome are listed in Table 1.

Both short-term preparations and long-term cultures from CVS were obtained by conventional methods (Simoni et al., 1983).

Fetal tissues and further placental samples were obtained after termination. Because of poor cellular growth and banding, FISH analysis was applied to

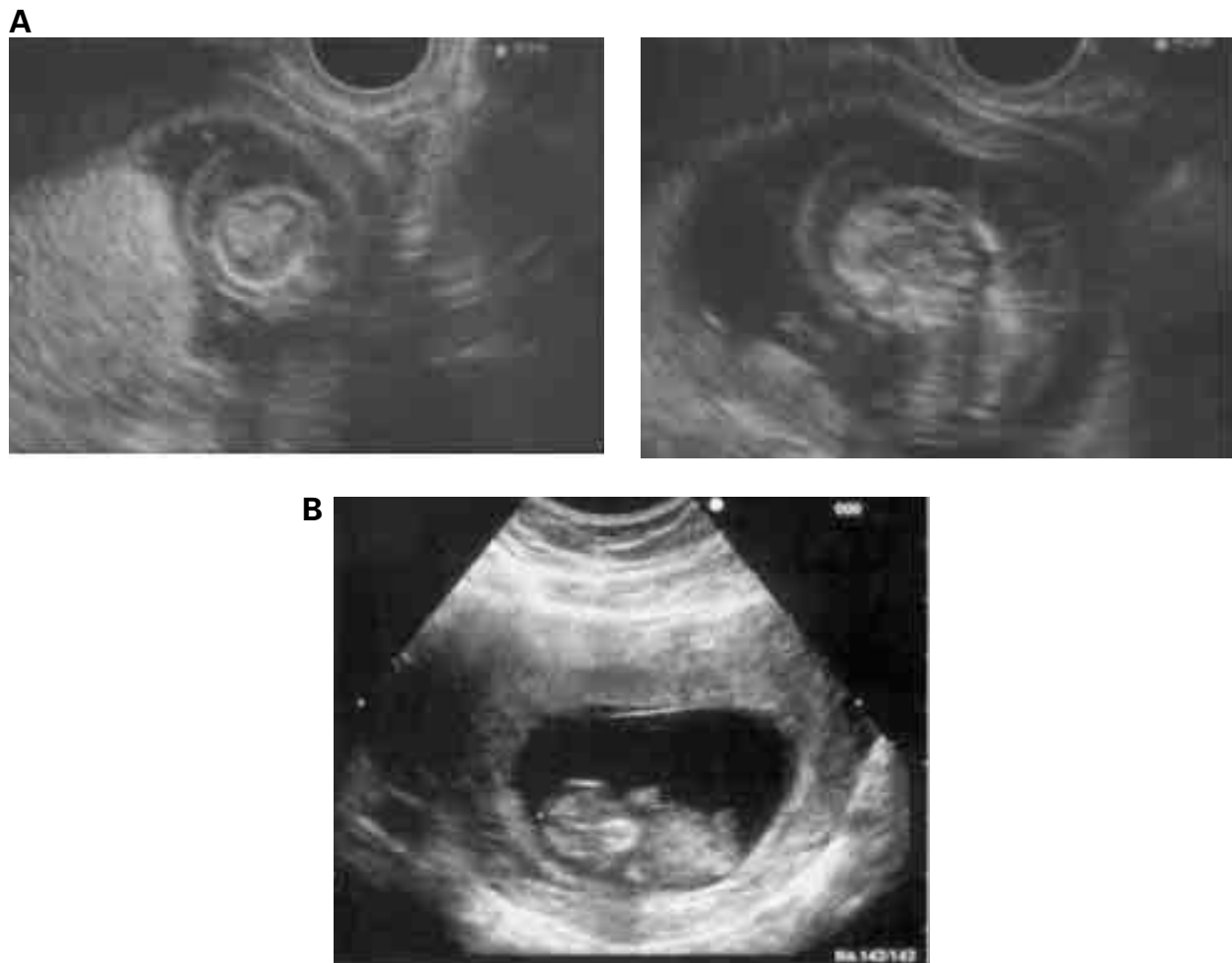


Figure 1

A: Section through the cystic hygroma of the abnormal twin (Twin 1). B: Sonogram of Twin 2.

Table 1

Markers at Polymorphic Sites for Detection of the X Chromosome

Marker	Length of amplicon (bp)	Chromosome location
AMXY	X, 104 and Y, 110	Xp 22.3, Yp 11.2
X22	189-242	Xq, Yq (PAR2)
HPRT	268-296	Xq 26.1
DXS6803	106-124	Xp ter – qter
DXS6809	242-279	Xp ter – qter

Note: Amplicon — PCR product fragment; bp — base pair

both metaphase and interphase nuclei using probes DXZ1 (centromeric sequences) and KAL (region p21.3 of chromosome X), was performed on placental tissue and fibroblast of Twin 2.

Results

CVS QF-PCR showed a normal result with chromosomes 13, 18 and 21 and detected only a single X chromosome (Figure 2A and 2B).

The karyotype obtained by application of the direct method to 50 metaphase cells from the same

sample showed a 45,X pattern. This result was confirmed by long-term preparations on 38 cell growth areas from two different cultures.

Cytogenetic analysis of the two samples of amniotic fluid revealed two different karyotypes: one 45,X and the other showing 46 chromosomes with a deletion of the entire short arm of one X chromosome. The analysis was performed on nine and ten clones from each sample.

After termination, karyotypes obtained from fetal skin fibroblasts of both fetuses confirmed the amniotic fluid analysis. FISH analysis, performed on Twin 2 because of the unsatisfactory quality of the preparations, confirmed the amniotic fluid karyotype whereas analysis of the placenta showed both cell lines. Probes DXZ1 (centromeric sequences) and KAL (region p21.3 of chromosome X) were used. The results are summarized in Table 2.

Discussion

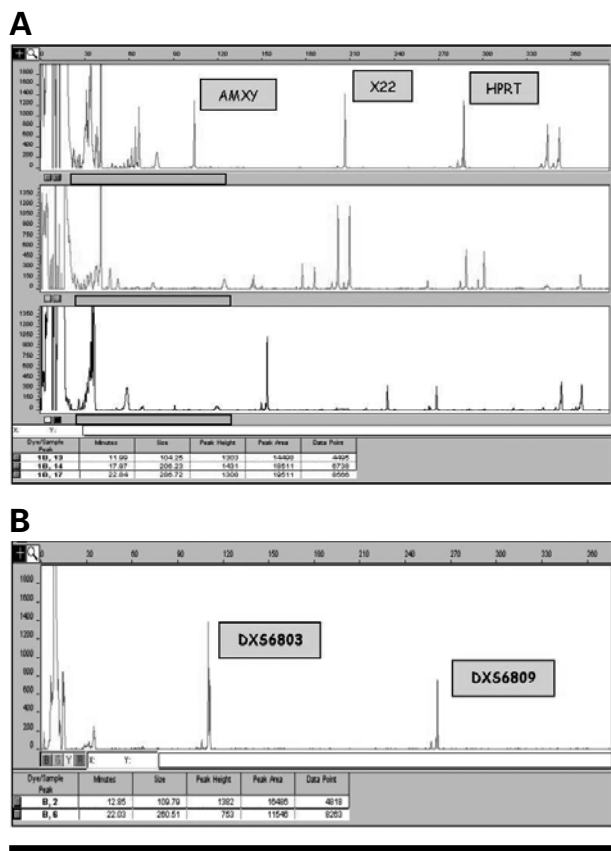
Heterokaryotypic twinning appears to be a rare event. A likely hypothesis to explain the pathogenesis may be that of a postzygotic event in the very early embryonic period (Cheng et al., 2006) or as a postzygotic nondisjunction event leading to chromosomal mosaicism. Furthermore, heterokaryotypic monozygous twins could be the consequences of a splitting of the conceptus after a mitotic nondisjunction.

Any diagnostic failure to uncover a discrepant karyotype between embryos that demonstrate a discordant phenotype might well have serious consequences in terms of counselling and management. In practice, most clinicians usually analyze only a single sample to obtain the fetal karyotype in monochorionic twins, whereas a dual sampling of both fetuses is carried out in dichorionic twins. In this way many cases of discordant chromosomal anomalies may have been missed.

Previously reported cases of discordant phenotype and karyotype may be grouped into three categories: discordance of sexual phenotype with mosaicism 46,XY/45,X or 45,X/46,XX (Chen et al., 2003; Schmid et al., 2000; Wachtel et al., 2000); discordance of autosomal trisomies or monosomies (Cheng et al., 2006; Lewi et al., 2003; Lewi et al., 2006; Nieuwint et al., 1999; Rogers et al., 1982); and, very rarely, unusual structural anomalies (Bourthoumieu et al., 2005).

In 2003, Chen et al. reported the case of a primigravida referred at the 14th week of gestation because of a twin pregnancy with a structurally abnormal co-twin who presented with a large cystic hygroma. Cytogenetic analysis of amniotic fluid revealed a 46,XX karyotype in the normal twin and a 45,X karyotype in the abnormal one while molecular studies revealed a monozygotic pregnancy.

After termination, skin fibroblasts from both twins were grown and the results of the cytogenetic analysis correlated well with that of the amniotic fluid.

**Figure 2**

A: Electropherogram of polymorphic sites AMXY, X22, HPRT. The presence of a single peak can be associated with two different events; the first might be the result of homozygosity of the marker leading to a noninformative test, while the second could be a real monosomy of the X chromosome. B: Electropherogram of the second panel for the additional polymorphic sites for X chromosome: DXS6803 and DXS6809.

Table 2

Analytical Methods Employed and Cytogenetic Results

Sample	Method	Result
Chorionic Villi (single sample – monochorionic pregnancy)	Short-term culture: 50 metaphases	45,X
	Long-term cultures: 38 cell growth areas from 2 independent cultures	45,X
Amniotic fluid		
1° sample (Twin 1)	9 colonies from 2 independent cultures	45,X
2° sample (Twin 2)	10 colonies from 2 independent cultures	46,X,del(X)(p11.1)
Fetal fibroblasts		
1° sample (Twin1)	22 cell growth areas from 2 independent cultures	45,X
2° sample (Twin 2)	4 cell growth areas + 48 (nuclei + metaphases)	46,X,del(X).ish del(X)(p11.1) (DXZ3+,KAL-)
Placenta after termination	Short-term culture: 9 metaphases	mos 45,X.ish 45,X(DXZ3-,KAL-)[6] / 46,X,del(X)(p11.1).ish del(X)(p11.1)(DXZ3+,KAL-)[3]
	Long-term culture: 13 cell growth areas from 3 independent cultures	mos 45,X.ish 45,X(DXZ3-,KAL-)[9] / 46,X,del(X)(p11.1).ish del(X)(p11.1)(DXZ3+,KAL-)[4]

Note: Twin 1 — fetus with cystic hygroma; Twin 2 —fetus normal at ultrasound examination.

Chromosome studies from the monochorionic diamniotic placenta showed a 45,X/46,XX mosaicism revealing the discrepancy between skin fibroblasts and chorionic cells for the normal fetus. The authors of this study suggested that early in the second trimester amniotic fluid (AF), compared to chorionic villi, offers an advantage by providing a more reliable genotype-phenotype correlation.

Our case, together with previously reported cases, suggests that first trimester, single site CVS of monochorionic twins even without phenotypic differences is not appropriate because it can miss mosaicisms and, thus, be misleading in cases of selective termination. Our case indeed revealed the coexistence of two cell lines that were undetectable by both cytogenetic and molecular analysis (QF-PCR) of CVS.

We do not have enough data to establish whether missing the second cell line in the first CVS analysis was due to sampling difficulty and could have been avoided by using multiple sampling.

Our case further shows that ultrasound and cytogenetic discordances do not necessarily exclude monozygosity. It is advisable that monochorionic twins should be evaluated with a molecular analysis to define the zygosity while karyotyping should be performed on amniocytes from both amniotic sacs.

References

Bourthoumie, S., Yardin, C., Terro, F., Gilbert, B., Laroche, C., Saura, R., Vincent, M. C., & Esclaire, F. (2005). Monozygotic twins concordant for blood karyotype, but phenotypically discordant a case of ‘mosaic chimerism’. *American Journal of Medical Genetics Part A*, 135, 190–194.

Brambati, B., Oldrini, A., Simoni, G., Terzoli, G. L., Romitti, L., Rossella, F., & Ferrari, M. (1984). First

trimester fetal karyotyping in twin pregnancy. *Journal of Medical Genetics*, 21, 58–60.

Chen, C.P., Chang, T.Y., Chern, S.R., Town, D.D., Pan, C.W., Lee, M.S., & Wang, W. (2003). Early second-trimester diagnosis of monozygotic twins discordant for cystic hygroma and Turner syndrome. *Prenatal Diagnosis*, 23, 352–358.

Cheng, P.J., Shaw, S.W., Shih, J.C., & Soong, Y.K. (2006). Monozygotic twins discordant for monosomy 21 detected by first trimester nuchal translucency screening. *Obstetrics & Gynecology*, 107, 538–541.

Crane, J., & Cheung, S.W. (1988). An embryonic model to explain cytogenetic inconsistencies observed in chorionic villus versus fetal tissues. *Prenatal Diagnosis*, 8, 119–129.

Cirigliano, V., Ejarque, M., Canadas, M., Paz Lloveras, A.P., del Mar Perez, M., Fuster, C., & Egozcue, J. (2001). Clinical Application of multiplex quantitative fluorescent polymerase chain reaction (QF-PCR) for the rapid prenatal detection of common chromosome aneuploidies. *Molecular Human Reproduction*, 7, 1001–1006.

Gilbert, B., Yardin, C., Briault, S., Belin, V., Lienhardt, A., Aubard, Y., Battin, J., Servaud, M., Philippe, H. J., & Lacombe, D. (2002). Prenatal diagnosis of female monozygotic twins discordant for Turner Syndrome: implication for prenatal genetic counselling. *Prenatal Diagnosis*, 22, 697–702.

Grati, F. R., Grimi, B., Frascoli, G., Di Meco, A. M., Liuti, R., Milani, S., Trotta, A., Dulcetti, F., Grosso, E., Miozzo, M., Maggi, F., & Simoni, G. (2006). Confirmation of mosaicism and uniparental disomy in amniocytes, after detection of mosaic chromosome abnormalities in chorionic villi. *European Journal of Human Genetics*, 14, 282–8.

- Hahneman, J., & Vejerslev, L. (1997). Accuracy of cytogenetic findings in CVS: Diagnostic consequences of CVS mosaicism and non-mosaic discrepancy in centres contributing to EUCHROMIC 1986–1992. *Prenatal Diagnosis*, 17, 801–820.
- Hall, J. G. (1996). Twinning mechanisms and genetic implications. *Current Opinion in Genetics & Development*, 6, 343–347.
- Hall, J. G. (2003). Twinning Developmental Biology. *The Lancet*, 362, 735–743.
- Lewi, L., Van Shoubroek, D., Gratacos, E., Witters, I., Timmerman, D., & Deprest, J. (2003). Monochorionic diamniotic twins: complications and management options. *Current Opinion in Obstetric & Gynecology*, 15, 177–194.
- Lewi, L., Blickstein, I., Van Schoubroek, D., Gloning, K. P., Casteels, M., Brandenburg, H., Fryns, J. P., Deprest, J. (2006). Diagnosis and management of heterokaryotypic monochorionic twins. *American Journal of Medical Genetics*, 140, 272–275.
- Nicolini, U., Lalatta, F., Natacci, F., Curcio, C., & Bui, T. H. (2004). The introduction of QF-PCR in prenatal diagnosis of fetal aneuploidies: Time for reconsideration. *Human Reproduction Update*, 10, 541–8.
- Nieuwint, A., Van Zalen-Sprock, R., Hummel, P., Pals, G., Van Vugt, J., Van Der Harten, H., Heins, Y., & Madan, K. (1999). 'Identical' twins with discordant karyotype. *Prenatal Diagnosis*, 19, 72–76.
- Rogers, J. G., Voullaire, L., & Gold, H. (1982). Monozygotic twins discordant for trisomy 21. *American Journal of Medical Genetics*, 11, 143–146.
- Rohrer, T. R., Gassmann, K. F., Rauch, A., Pfeiffer, R. A., & Doerr, H. G. (2004). Growth of heterokaryotypic monozygotic twins discordant for Ulrich-Turner syndrome during the first years of life. *American Journal of Medical Genetics*, 126, 78–83.
- Shmid, O., Trautmann, U., Ashour, H., Ulmer, R., Pfeiffer, R. A., & Beinder, E. (2000). Prenatal diagnosis of heterokaryotypic mosaic twins discordant for fetal sex. *Prenatal Diagnosis*, 20, 999–1003.
- Simoni, G., Brambati, B., & Danesino, C. (1983). Efficient direct chromosome analyses and enzyme determinations from chorionic villi samples in first trimester of pregnancy. *Human Genetics*, 63, 349–357.
- Wachtel, S. S., Somkuti, S. G., Schinfeld, J. S. (2000). Monozygotic twins of opposite sex. *Cytogenetic and Cell Genetics*, 91, 293–295.
-