

## Main Article

Hisham Atef Ebada takes responsibility for the integrity of the content of the paper

**Cite this article:** Abdelmeguid AS, El-Okda MMA-F, Abozaid MAM, Ebada HA. Prognostic factors in post-Covid-19 acute invasive fungal sinusitis. *J Laryngol Otol* 2024;**138**:1176–1180. <https://doi.org/10.1017/S0022215124001142>

Received: 15 December 2023

Revised: 16 April 2024

Accepted: 30 April 2024

First published online: 21 October 2024

### Keywords:

Covid-19; invasive fungal infections; sinusitis; prognosis; survival

### Corresponding author:

Hisham Atef Ebada;

Email: [hishamebada@mans.edu.eg](mailto:hishamebada@mans.edu.eg)

## Abstract

**Objectives.** The aim of this study is to identify the prognostic factors that may have an effect on the outcome of post-coronavirus disease 2019 acute invasive fungal sinusitis in order to help optimise diagnosis and management.

**Methods.** This retrospective study involved 60 patients with post-coronavirus disease 2019 acute invasive fungal sinusitis. We identified and studied several factors that may have an effect on the prognosis. These factors included patient-related factors, disease-related factors, and treatment-related factors.

**Results.** Comorbidities especially renal impairment, previous intensive care unit admission, skin involvement, and intracranial spread of infection are associated with significantly poorer outcomes. Early aggressive surgical debridement is an independent factor associated with better prognosis.

**Conclusion.** Identifying prognostic factors may have a role in prevention of invasive fungal sinusitis, predicting prognosis, and tailoring patient-specific treatment protocols.

## Introduction

Post-coronavirus disease 2019 (Covid-19) acute invasive fungal sinusitis is a new clinical entity that has been described by many authors since 2019.<sup>1–3</sup> There has been a marked increased incidence of acute invasive fungal sinusitis in post-Covid-19 patients.<sup>4</sup> Increased susceptibility of fungal infections in Covid-19 patients may be due to overexpression of inflammatory cytokines and impairment of cell-mediated immunity with a decrease in T-helper cell count, elevated blood glucose (diabetes, new-onset hyperglycaemia, steroid-induced hyperglycaemia), hypoxia, acidic medium (metabolic acidosis, diabetic ketoacidosis), decreased phagocytic activity of white blood cells, and immunosuppression (Covid-19 mediated, steroid-mediated, or background comorbidities).<sup>5,6</sup>

Acute invasive fungal sinusitis is a life-threatening condition in which the mucous membrane of the nose and sinuses is invaded by a fungus that has a high risk of invasion and destruction of the adjacent structures.<sup>7</sup> Reported mortality rates in the literature are variable (14–80 per cent),<sup>8–12</sup> and ranging up to almost 100 per cent in disseminated infections despite medical and surgical treatments.<sup>13</sup>

Factors that may affect the prognosis of acute invasive fungal sinusitis remain not fully understood. Some factors include advancing age,<sup>14,15</sup> early aggressive surgical debridement,<sup>15,16</sup> type of fungus,<sup>9,15</sup> presence of haematologic malignancy,<sup>17</sup> and orbital and intracranial extensions.<sup>13</sup> However, there is a paucity of literature regarding precise prognostic factors. The aim of the current study is to identify the prognostic factors that may have an effect on the outcome of acute invasive fungal sinusitis and the survival of this patient population, in order to help optimise diagnosis and management.

## Patients and methods

This retrospective study was conducted in a tertiary referral centre; Otorhinolaryngology Department, Mansoura University Hospitals, Egypt, over two years duration (October 2020–October 2022). Informed written consents were obtained from all participants, and the study was approved by the Mansoura Faculty of Medicine Institutional Research Board (MFM-IRB: MS.22.02.1870).

After reviewing patients' records, all patients with post-Covid-19 acute invasive fungal sinusitis managed at our institute during the study duration ( $n = 60$ ) were included in the study. All patients in the study had definite diagnosis of previous Covid-19 infection. The interval between the diagnosis of Covid-19 and acute invasive fungal sinusitis was 13–42 days (mean = 23.7 days). Diagnosis and management of Covid-19 followed the national management protocol.<sup>18</sup>

Patients' management included detailed histories and clinical examinations. All patients in the study underwent high-resolution, contrast-enhanced computed tomography (CT) scans. Additionally, patients with intra-orbital or intra-cranial extension of infection underwent magnetic resonance imaging. Diagnosis and management followed

the global guideline for the diagnosis and management of acute invasive fungal sinusitis.<sup>19</sup> Diagnosis relied upon endoscopic endonasal findings of mucosal pallor, blackening, gangrene, and/or palatal ischemia, gangrene, and/or orbital findings as proptosis, ophthalmoplegia, or vision loss. Additionally, histopathological examination confirmed the diagnosis by presence of fungal invasion within sinus mucosa, submucosa, or bone.

Antifungal therapy with surgical debridement was the main line of treatment for acute invasive fungal sinusitis. Upon clinical diagnosis, we started treatment immediately without waiting for histology or culture results because delay in treatment is associated with significant morbidity and mortality.

Antifungal drugs included liposomal amphotericin B, voriconazole, and posaconazole. The choice of antifungal agents followed the national management protocol<sup>18</sup> under supervision of the infectious disease department. Duration of the antifungal treatment was 19–62 days (median 33 days), until complete resolution of signs and symptoms, with monitoring of renal functions, liver functions, complete blood count, and blood-sugar levels.

We tailored surgical procedures according to the disease extension. We performed endoscopic, open, and combined approaches. Furthermore, we performed serial debridement until complete eradication of infection. After surgical debridement, histopathological examination of tissues was of utmost importance to confirm acute invasive fungal sinusitis as well as to determine the causative fungus based on the morphology of the hyphae using haematoxylin and eosin, periodic acid-Schiff, and Grocott–Gömöri's methenamine silver staining. Moreover, specimens were sent for fungal culture for determination of the type of growth.

After discharge of the patients, we scheduled follow-up visits in the outpatient department on a weekly basis for three months. The follow-up period was 6–30 months (average 21.5 months). The authors of this work considered the outcome as successful when patients were symptom free, and serial examinations revealed adequate healing with no evidence of disease (ischemia or gangrene) in the follow up visits.

We identified and studied several factors that may have had an effect on the prognosis. These factors included patient-related factors (age, gender, medical comorbidities), disease-related factors (type of fungus, extension of infection) and treatment-related factors (history of intensive care unit (ICU) admission, type of antifungal drug, type of surgical treatment).

## Results

This study included 60 patients with post-Covid-19 acute invasive fungal sinusitis, whether admitted from the outpatient clinic ( $n = 24$ ), from the emergency department ( $n = 19$ ), or

referred from other centres ( $n = 17$ ). Patients mean age was 56.23 years. Medical comorbidities occurred in 59 of 60 patients (98.3 per cent). Diabetes mellitus was the commonest (95 per cent). Other comorbidities included hypertension (55 per cent), hepatic impairment (13.3 per cent), renal impairment (11.7 per cent) and cardiac disease (3.3 per cent).

Diminution of vision was the most frequent patient presentation (38.3 per cent), followed by palatal necrosis (28.3 per cent). Other presentations included facial pain (16.7 per cent), sino-nasal symptoms (nasal obstruction and discharge) (11.7 per cent) and facial swelling (8.3 per cent).

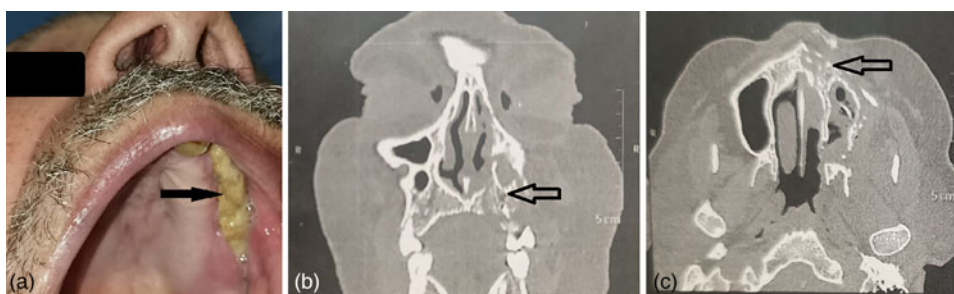
The extension of infection among the studied group was sino-nasal in 58 of 60 (96.7 per cent), orbital in 28 of 60 (46.7 per cent), and palatal in 21 of 60 (35 per cent) (Figure 1). Intracranial involvement occurred in nine patients in the form of cavernous sinus thrombosis (11.7 per cent) and brain abscess (3.3 per cent). Additionally, skin affection in the form of gangrene occurred in two cases (3.3 per cent) (Figure 2), and frontal sinus osteomyelitis occurred in two patients (3.3 per cent) (Figure 3).

Based on the national protocol<sup>18</sup> and recommendations of the infectious diseases specialists, we prescribed empirical IV liposomal amphotericin B (1 mg/kg/day) immediately, before waiting for the results of the culture. Consequently, 58 out of 60 patients received empirical amphotericin. The remaining two cases had a history of liver transplant, and therefore amphotericin B was contra-indicated. After consultation of gastroenterologists, we used posaconazole.

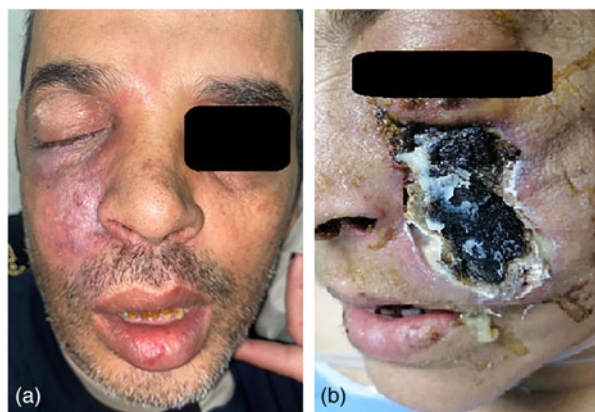
After obtaining culture results, we immediately prescribed voriconazole (200 mg 12 hourly) instead of amphotericin. In two patients the culture revealed mixed infection with both mucor and aspergillus. Therefore, those patients received a combination of liposomal amphotericin B and voriconazole. All patients ( $n = 60$ ) completed the course of antifungal drugs with no reported major complications of treatment.

Fifty-seven patients (95 per cent) underwent surgical debridement. Three patients received only medical treatment due to poor anaesthetic fitness ( $n = 2$ ) and patient refusal of surgery ( $n = 1$ ). We performed endoscopic endonasal debridement in 54 cases. Repeated surgical debridement was necessary in 21 patients until endoscopic examination revealed healthy tissues without evidence of ischemia, necrosis, or gangrene (2 sessions in 17 patients, 3 sessions in 3 patients, and 4 sessions in 1 patient).

We utilised external approaches in 23 patients. After multidisciplinary consultations of ophthalmology, neurosurgery, and maxillofacial surgery, we performed orbital exenteration in 13 patients (21.7 per cent), palatotomy and/or maxillectomy in 11 patients (18.3 per cent), debridement and sequestrectomy for frontal sinus osteomyelitis in 2 cases (3.3 per cent), skin debridement in 2 cases, and craniotomy for evacuation of a brain abscess in 1 patient.



**Figure 1.** A: Osteomyelitis and sequestrum in the right side of the palate (arrow). B, C: Coronal and axial CT scan of the same patient showing osteomyelitis (arrows).



**Figure 2.** Skin affection in two patients. A: Ischemia and blackening in the right cheek. B: More-severe necrosis and gangrene in the left cheek.

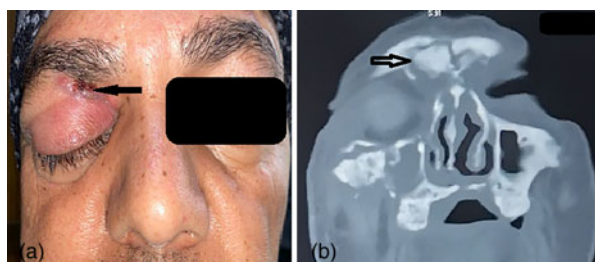
At the end of treatment, the overall success rate was 91.7 per cent. In five patients (8.3 per cent), the prognosis was poor despite medical and/or surgical treatment. All five of these patients died from the disease or its complications and were listed as failed outcomes.

In the current study, we analysed multiple variables that may have affected the success rate (Table 1). Patients' age and gender did not have an effect on prognosis. Similarly, the type of fungus, whether mucor, aspergillus, or mixed infection, as well as the antifungal agent were not associated with a significant effect on the outcome.

Regarding co-morbidities, renal impairment was detected in 4 of 55 cases (7.3 per cent) in the successful group and in 3 of 5 (60 per cent) in the failed group ( $p=0.041$ ). Consequently, renal impairment showed a significant poor effect on the outcome. Other co-morbidities (diabetes mellitus, hypertension, hepatic disease, cardiac disease) did not have a significant effect on the outcome. Additionally, history of ICU admission was associated with a statistically significant poor effect on the prognosis, as it was noted in 5 of 60 cases (9.1 per cent) in the successful group and in 5 of 5 (100 per cent) in the failed group ( $p \leq 0.001$ ).

Similarly, extension of infection was one of the significant prognostic factors. Intracranial extension (cavernous sinus thrombosis and brain abscess) had a negative effect on the prognosis ( $p \leq 0.001$ ). Additionally, skin affection was associated with a significant poor outcome ( $p \leq 0.001$ ). However, orbital and palatal involvement did not have a statistically significant effect on the outcome ( $p=0.754$  and  $0.449$ , respectively).

Three patients in the current study received only medical antifungal treatment without surgical debridement, and the



**Figure 3.** Right frontal osteomyelitis with a fistula formation (arrow). B: CT scan of the same patient showing osteomyelitis and sequestrum formation in the right frontal sinus.

outcome was poor in those three patients with reported mortality. Consequently, medical treatment alone was associated with a poor effect on the prognosis.

## Discussion

Acute invasive fungal sinusitis is a highly morbid disease. It can directly invade intracranial and intra-orbital spaces with a potentially fatal outcome. The reported mortality rates are variable (14–100 per cent).<sup>8–13</sup> In the large meta-analysis conducted by Turner *et al.*<sup>15</sup> on 807 patients with acute invasive fungal sinusitis, the overall survival rate was 49.7 per cent. Few data are available regarding the prognostic factors that may determine the survival rate.

Nearly all patients with acute invasive fungal sinusitis involve immunosuppression, most commonly related to diabetes mellitus, haematologic malignancy, or organ transplantation.<sup>20</sup> In the current study, comorbidities occurred in 98.3 per cent of patients. Diabetes mellitus was the commonest (95 per cent). A diabetic patient is more susceptible to invasive fungal infections due to derangement of granulocyte-phagocytic activity, altered polymorphonuclear leukocyte response, microangiopathy and peripheral vascular diseases, with subsequent local-tissue ischemia and increased susceptibility to infections. Additionally, the acidic environment, low oxygen, and high glucose levels facilitate germination and growth of fungal spores.<sup>21,22</sup>

Comorbidities have been identified as a negative prognostic factor. Previous reports found that underlying haematologic malignancy as well as liver and renal failure are associated with a poor outcome.<sup>15,23</sup> In the current study, patients with renal impairment had a statistically significant poor prognosis.

Similarly, some authors have reported that advanced age results in decreased survival, independent of other factors.<sup>14,15</sup> Not surprisingly, such patients can be assumed to have additional comorbidities and are generally more vulnerable to aggressive infections and other medical problems. However, in the present work, age did not have a significant effect on the outcome.

History of ICU admission in the current study had a negative effect on the prognosis. Eldsouky *et al.*<sup>24</sup> reported that patients with severe Covid-19, who are admitted in the ICU, are especially vulnerable to bacterial and fungal infections.

Disease extension is an additional significant prognostic factor. Progression from limited disease or isolated nasal lateral wall involvement to involvement of the hard palate and orbit has been observed to portend a poorer prognosis.<sup>16,25</sup> In one retrospective series, orbital involvement increased mortality nearly four-fold compared to isolated sinonasal involvement.<sup>10</sup> However, other studies have shown that only intracranial and cavernous sinus extension is a negative prognostic factor and that dissemination is a better indicator of morbidity.<sup>15,26</sup> Orbital and palatal extensions in the current study were not associated with poor outcomes or mortality. Nevertheless, patients with brain abscess, cavernous sinus thrombosis, and skin affection had statistically significant poor prognosis.

Mucor species infection has been associated with higher mortality, given the more aggressive nature of these organisms.<sup>9,15</sup> In our study, no significant difference between mucor and aspergillus infections in terms of survival was reported. This may be due to the relatively small sample size and the small number of patients diagnosed with aspergillus infection (6 out of 60 patients).



**Table 1.** The effects of multiple factors on prognosis; ICU = intensive care unit;  $\chi^2$  = chi-square test, FET = Fisher's exact test, MC = Monte Carlo test,  $t$  = Student's  $t$  test

Prognostic factors	Successful outcome (n = 55)	Failed outcome (mortality) (n = 5)	Test of sig.	P value
Age	56.16 ± 12.17	57.00 ± 10.17	$t = 0.149$	$p = 0.882$
Gender	24 (43.6%)	2 (40%)		$p = 0.897$
	31 (56.4%)	3 (60%)		
Co-morbidities				
Diabetes mellitus	52 (94.5%)	5 (100%)	FET = 0.287	$p = 1.0$
Hypertension	31 (56.4%)	2 (40%)	FET = 0.496	$p = 0.645$
Hepatic disease	7 (12.7%)	1 (20%)	$\chi^2 = 0.210$	$p = 0.647$
Renal impairment	4 (7.3%)	3 (60%)	FET = 4.9	$p = 0.041$
Cardiac disease	2 (3.6%)	0 (0%)	$\chi^2 = 0.720$	$p = 0.396$
ICU admission	5 (9.1%)	5 (100%)	$\chi^2 = 27.3$	$p \leq 0.001$
Extension of infection				
Sino-nasal	53 (96.4%)	5 (100%)	FET = 0.277	$p = 1.0$
Orbital	26 (47.3%)	2 (40%)	FET = 0.365	$p = 0.754$
Palatal	10 (18.2%)	2 (40%)	$\chi^2 = 0.514$	$p = 0.449$
Cavernous sinus thrombosis	3 (5.4%)	4 (80%)	$\chi^2 = 24.29$	$p < 0.001$
Brain abscess	0 (0%)	2 (40%)	$\chi^2 = 25.78$	$p < 0.001$
Skin	0 (0%)	2 (40%)	$\chi^2 = 25.78$	$p < 0.001$
Frontal sinus osteomyelitis	2 (3.6%)	0 (0%)	$\chi^2 = 0.720$	$p = 0.396$
Type of fungus				
Mucor	48 (87.3%)	4 (80%)	MC = 0.145	$p = 0.930$
Aspergillus	5 (9.1%)	1 (20%)		
Mixed	2 (3.6%)	0 (0%)		
Type of antifungal drug				
Amphotericin B only	46 (83.6%)	4 (80%)	MC = 3.695	$p = 0.305$
Amphotericin B and voriconazole	7 (12.7%)	1 (20%)		
Posaconazole	2 (3.6%)	0 (0%)		
Surgical debridement				
No surgery	0 (0%)	3 (60%)	$\chi^2 = 26.4$	$p \leq 0.001$
Endoscopic surgery only	33 (60%)	1 (20%)	$\chi^2 = 0.598$	$p = 0.402$
Combined (endoscopic and open approach)	22 (40%)	1 (20%)	$\chi^2 = 0.302$	$p = 0.612$

According to the global guideline for diagnosis and management of invasive fungal sinusitis, 2019,<sup>19</sup> an early complete surgical treatment is strongly recommended whenever possible, in addition to systemic antifungal treatment. In the current series, relying on medical treatment only without surgical debridement was associated with a statistically significant poor outcome. Systemic antifungal treatment alone is typically insufficient for eliminating the infection because of its angio-invasive nature, which leads to obliteration of local blood supply and rapid tissue necrosis that limits the penetration of systemic therapy.<sup>15,20</sup> Therefore, debridement of necrotic tissue plays a key role in the management of acute invasive fungal sinusitis.

Many authors reported that prompt surgical debridement was associated with better outcomes.<sup>15,16,27</sup> Similarly, in patients with orbital extension, Ashraf *et al.*<sup>20</sup> reported that orbital exenteration was associated with higher survival rates. Moreover, in patients with fungal osteomyelitis in the maxilla, palate, or frontal bone, debridement and sequestrectomy is the treatment of choice.<sup>28,29</sup>

It is likely that debriding necrotic areas may lead to improved antimicrobial penetration, and that surgically decreasing the burden of fungal organisms may reduce the risk of regional and systemic spread of disease. In the current work, the survival rate was 91.7 per cent. The relatively low mortality (8.3 per cent) among patients with acute invasive fungal sinusitis in the current study may be attributed to early diagnosis and timely intervention. In the late post-Covid-19 era, increased public awareness of this disease (black fungus disease) has prompted earlier patient referrals from other specialties and facilities, as well as patients seeking their own medical attention upon any disease suspicion. Furthermore, in the late post-Covid era, subsequent variants and mutants of the Covid-19 virus are known to have lower virulence and mortality than the ancestor ones.<sup>30</sup>

Additionally, improved learning curve and experience at our tertiary referral centre, as well as the multidisciplinary team approach has led to better decision making and patient care. Early aggressive surgical debridement with variable combinations of endoscopic endonasal techniques, orbital exenteration,

maxillofacial approaches (frontal, maxillary, and palatal osteomyelitis) and neurosurgical craniotomy approaches according to the disease extension, may have a role in achieving better disease control.

- Although post-coronavirus disease 2019 acute invasive fungal sinusitis recently has been described by many authors, there is a paucity of relevant literature regarding the precise prognostic factors that have an effect on the prognosis of acute invasive fungal sinusitis.
- Researchers have identified some factors that affect acute invasive fungal sinusitis including advancing age, early aggressive surgical debridement, type of fungus, presence of haematologic malignancy and orbital and intracranial extensions
- The current study concluded that comorbidities, especially renal impairment, previous intensive care unit admission, skin involvement, and intracranial spread of infection, are associated with significantly poor outcomes
- Early aggressive surgical debridement was an independent factor associated with better prognosis in this study

Identifying prognostic factors may have a role in predicting prognosis, and tailoring patient-specific treatment protocols. Furthermore, prophylactic antifungal use in high-risk groups such as immunocompromised patients in intensive care units may be warranted to protect against this life-threatening invasive fungal infection.

## Conclusion

The current study concludes that comorbidities, especially renal impairment, previous ICU admission, skin involvement, and intracranial spread of infection, are associated with significantly poorer outcomes. Early aggressive surgical debridement is an independent factor associated with better prognosis.

**Conflicts of interest and financial support.** There are no conflicts of interest or financial disclosures to be made.

## References

- 1 El-Kholy NA, Abd El-Fattah AM, Khafagy YW. Invasive fungal sinusitis in post COVID-19 patients: a new clinical entity. *Laryngoscope* 2021;**131**:2652–8
- 2 Mekonnen ZK, Ashraf DC, Jankowski T, Grob SR, Vagefi MR, Kersten RC et al. Acute invasive rhino-orbital mucormycosis in a patient with COVID-19-associated acute respiratory distress syndrome. *Ophthalm Plast Reconstr Surg* 2021;**37**:e40–80
- 3 Sebastian SK, Kumar VB, Gupta M, Sharma Y. Covid associated[*sic*] invasive fungal sinusitis. *Indian J Otolaryngol Head Neck Surg* 2022;**74**(suppl 2):2883–6
- 4 Ismaiel WF, Abdelazim MH, Eldsoky I, Ibrahim AA, Alsobky ME, Zafan E et al. The impact of COVID-19 outbreak on the incidence of acute invasive fungal rhinosinusitis. *Am J Otolaryngol* 2021;**42**:103080
- 5 Singh AK, Singh R, Joshi SR, Misra AJ. Mucormycosis in COVID-19: a systematic review of cases reported worldwide and in India. *Diabetes Metab Syndr* 2021;**15**:102146
- 6 Song G, Liang G, Liu W. Fungal co-infections associated with global COVID-19 pandemic: a clinical and diagnostic perspective from China. *Mycopathologia* 2020;**185**:599–606
- 7 Wandell GM, Miller C, Rathor A, Wai TH, Guyer RA, Schmidt RA et al. A multi-institutional review of outcomes in biopsy-proven acute invasive fungal sinusitis. *Int Forum Allergy Rhinol* 2018;**8**:1459–68
- 8 Gardner JR, Hunter CJ, Vickers D, King D, Kanaan A. Perioperative indicators of prognosis in acute invasive fungal sinusitis. *OTO Open* 2021;**5**:2473974X211002547
- 9 Deutsch PG, Whittaker J, Prasad S. Invasive and non-invasive fungal rhinosinusitis – a review and update of the evidence. *Medicina (Kaunas)* 2019;**55**:319
- 10 Trief D, Gray ST, Jakobiec FA, Durand ML, Fay A, Freitag SK et al. Invasive fungal disease of the sinus and orbit: a comparison between mucormycosis and *Aspergillus*. *Br J Ophthalmol* 2016;**100**:184–8
- 11 Baghel SS, Keshri AK, Mishra P, Marak R, Manogaran RS, Verma PK et al. The spectrum of invasive fungal sinusitis in COVID-19 patients: experience from a tertiary care referral center in northern India. *J Fungi (Basel)* 2022;**8**:223
- 12 Sen M, Honavar SG, Bansal R, Sengupta S, Rao R, Kim U et al. Epidemiology, clinical profile, management, and outcome of COVID-19-associated rhino-orbital-cerebral mucormycosis in 2826 patients in India – collaborative OPAI-IJO Study on Mucormycosis in COVID-19 (COSMIC), Report 1. *Indian J. Ophthalmol* 2021;**69**:1670–92
- 13 Jung SH, Kim SW, Park CS, Song CE, Cho JH, Lee JH et al. Rhinocerebral mucormycosis: consideration of prognostic factors and treatment modality. *Auris Nasus Larynx* 2009;**36**:274–9
- 14 Sun HY, Forrest G, Gupta KL, Aguado JM, Lortholary O, Julia MB et al. Rhino-orbital-cerebral zygomycosis in solid organ transplant recipients. *Transplantation* 2010;**90**:85–92
- 15 Turner JH, Soudry E, Nayak JV, Hwang PH. Survival outcomes in acute invasive fungal sinusitis: a systematic review and quantitative synthesis of published evidence. *Laryngoscope* 2013;**123**:1112–18
- 16 Wandell GM, Miller C, Rathor A, Wai TH, Guyer RA, Schmidt RA et al. A multi-institutional review of outcomes in biopsy-proven acute invasive fungal sinusitis. *Int Forum Allergy Rhinol* 2018;**8**:1459–68
- 17 Chen CY, Sheng WH, Cheng A, Chen YC, Tsay W, Tang JL et al. Invasive fungal sinusitis in patients with hematological malignancy: 15 years experience in a single university hospital in Taiwan. *BMC Infect Dis* 2011;**11**:250
- 18 Masoud H, Elassal G, Hakim M, Shawky A, Zaky S, Baki A et al. *Management Protocol for COVID-19 Patients*. COVID-19 Ministry of Health and Population, Egypt. Version 1.5/September 2021
- 19 Cornely OA, Alastruey-Izquierdo A, Arenz D, Chen SCA, Dannaoui E, Hochhegger B et al. Global guideline for the diagnosis and management of mucormycosis: an initiative of the European Confederation of Medical Mycology in cooperation with the Mycoses Study Group Education and Research Consortium. *Lancet Infect Dis* 2019;**19**:e405–21
- 20 Ashraf DC, Idowu OO, Hirabayashi KE, Kalin-Hajdu E, Grob SR, Winn BJ et al. Outcomes of a modified treatment ladder algorithm using retrobulbar amphotericin B for invasive fungal rhino-orbital sinusitis. *Am J Ophthalmol* 2022;**237**:299–309
- 21 Kheirkhah L, Asoubar S, Abdi A, Mahmoudi AJICPJ. Rhinocerebral mucormycosis in a patient with diabetes type 1 presenting as ptosis and facial palsy report from Alborz Hospital of Karaj from Iran. *Int Clin Pathol J* 2017;**5**:211–13
- 22 Tugsel Z, Sezer B, Akalin T. Facial swelling and palatal ulceration in a diabetic patient. *Oral Surg Oral Med Oral Pathol Oral Radiol Endod* 2004;**98**:630–6
- 23 Cho HJ, Jang MS, Hong SD, Chung SK, Kim HY, Dhong HJ. Prognostic factors for survival in patients with acute invasive fungal rhinosinusitis. *Am J Rhinol Allergy* 2015;**29**:48–53
- 24 Eldsouky SM, Shahat AK, Al-Tabbakh ASM, El Rahman SMA, Marei YM, Mohammed LA et al. Clinical and mycological investigations of post-COVID-19 acute invasive fungal sinusitis. *Laryngoscope Investig Otolaryngol* 2022;**7**:1780–9
- 25 Valera FCP, do Lago T, Tamashiro E, Yassuda CC, Silveira F, Anselmo-Lima WT. Prognosis of acute invasive fungal rhinosinusitis related to underlying disease *Int J Infect Dis* 2011;**15**:e841–4
- 26 DelGaudio JM, Clemson LA. An early detection protocol for invasive fungal sinusitis in neutropenic patients successfully reduces extent of disease at presentation and long-term morbidity. *Laryngoscope* 2009;**119**:180–3
- 27 Malleshappa V, Rupa V, Varghese L, Kurien R. Avoiding repeated surgery in patients with acute invasive fungal sinusitis. *Eur Arch Otorhinolaryngol* 2020;**277**:1667–74
- 28 Srivastava A, Mohapatra M, Mahapatra A. Maxillary fungal osteomyelitis: a review of literature and report of a rare case. *Ann Maxillofac Surg* 2019;**9**:168–73
- 29 Ebada HA, Abd El-Fattah AM, Tawfik A. Management of frontal sinus fungal osteomyelitis in the COVID 19 era: a case series. *J Craniomaxillofac Surg* 2022;**50**:692–8
- 30 El-Shabasy RM, Nayel MA, Taher MM, Abdelmonem R, Shoueir KR, Kenawy EL. Three waves[*sic*] changes, new variant strains, and vaccination effect against COVID-19 pandemic. *Int J Biol Macromol* 2022;**204**:161–8