

SHORT REPORT

Mechanical transmission of lumpy skin disease virus by *Rhipicephalus appendiculatus* male ticks

E. S. M. TUPPURAINEN¹*, J. C. LUBINGA², W. H. STOLTSZ², M. TROSKIE²,
S. T. CARPENTER¹, J. A. W. COETZER², E. H. VENTER² AND C. A. L. OURA¹

¹ Institute for Animal Health, Pirbright, Surrey, UK

² Department of Veterinary Tropical Diseases, Faculty of Veterinary Science, University of Pretoria, Onderstepoort, South Africa

Received 2 February 2012; Final revision 3 April 2012; Accepted 4 April 2012;
first published online 30 April 2012

SUMMARY

Lumpy skin disease (LSD) is an economically important, acute or sub-acute, viral disease of cattle that occurs across Africa and in the Middle East. The aim of this study was to investigate if lumpy skin disease virus (LSDV) can be transmitted mechanically by African brown ear ticks (*Rhipicephalus appendiculatus* Neum.). Laboratory-bred *R. appendiculatus* males were fed on experimentally infected viraemic ‘donor’ cattle. Partially fed male ticks were then transferred to feed on an uninfected ‘recipient’ cow. The recipient animal became viraemic, showed mild clinical signs of LSD and seroconverted. Additionally, *R. appendiculatus* males were found to transmit LSDV through feeding on skin lacking visible lesions, demonstrating that viraemic animals without lesions at the feeding site of ticks may be a source of infection. This is the first time that transmission of poxviruses by a tick species has been demonstrated and the importance of this mode of transmission in the spread of LSDV in endemic settings is discussed.

Key words: Capripoxvirus, lumpy skin disease virus, tick vector transmission, poxvirus, *Rhipicephalus appendiculatus*.

Lumpy skin disease (LSD) is an economically devastating disease of cattle that occurs across Africa and in the Middle East region. The causal organism is LSD virus (LSDV) which belongs to the genus *Capripoxvirus* within the family Poxviridae [1]. LSD inflicts serious constraints on livestock production in its endemic range, but poor rural communities without proper access to veterinary services are disproportionately affected during outbreaks of the disease. LSD causes severe production losses in infected herds, largely through sharp drops in milk yield and weight gain, infertility in both male and female stock and

abortions. In addition, the decreased value of hides due to permanent scarring caused by the skin lesions contributes to the economic impact [2–5]. While reports on the overall socioeconomic impact of LSD in developing countries are limited, losses due to decreased milk production alone were estimated to be in the range of 40–65% in an intensive milk-producing unit of 3200 cattle during a LSD outbreak that occurred in the Sultanate of Oman in 2010 [4].

It is widely agreed that the most important mode of transmission of LSDV is likely to be through mechanical transmission of the virus by a variety of blood-feeding vectors. This hypothesis is supported by the observation that LSD outbreaks are correlated with warm and wet seasons [5]. Previous studies have

* Author for correspondence: Ms. E. S. M. Tuppurainen, Institute for Animal Health, Ash Road, Pirbright, Surrey, GU24 0NF, UK. (Email: eeva.tuppurainen@iah.ac.uk)

demonstrated the transmission of sheeppox and goatpox virus by *Stomoxys calcitrans* (L.) stable flies [6] and LSDV by *Aedes aegypti* (L.) mosquitoes [7], respectively. More recent epidemiological investigations have additionally presented molecular evidence for a potential role of ixodid (hard) ticks as vectors for LSDV [8]. The transmission of LSDV by direct contact is considered to be inefficient [9, 10], while transmission may also occur, to a lesser extent, via common water troughs or feed contaminated by infected saliva or nasal discharge. Similarly, LSDV has also been isolated from bovine semen [11], but the importance of transmission via natural mating or artificial insemination is not yet fully understood. The role of wild ruminants as potential reservoirs for LSDV is currently unknown.

R. appendiculatus ticks are widespread and abundant in Africa. There are three host ticks (i.e. larvae, nymphs and adults feed on different hosts), which have been implicated in the transmission of many livestock pathogens, e.g. *Theileria* spp. (East Coast fever, Corridor disease, Zimbabwe theileriosis), *Ehrlichia* (*Cowdria*) *ruminantium* (heartwater), *Rickettsia conorii* and Nairobi sheep disease virus. In the subtropical, central and southern regions of Africa the occurrence of different *R. appendiculatus* life stages is seasonal: most adult *R. appendiculatus* ticks are found from mid- to late summer, coinciding with the peak of LSD cases. *R. appendiculatus* ticks prefer to feed on the ears of the host where the skin is thinner than other parts of the body, which allows them to feed in very close proximity to blood vessels. Adult *R. appendiculatus* ticks have been found to prefer to feed on large and medium-sized ruminants, whereas larvae and nymphs, in addition to feeding on most domestic and wild ruminant species, also feed on other mammalian species [12]. Interrupted feeding is a natural behavioural pattern of *R. appendiculatus* males and has been investigated as an evolutionary response in part to intra-species competition [13, 14]. This pattern of behaviour, especially when hosts are in close contact, enhances the likelihood for mechanical transmission of the virus.

In this study three seronegative Bonsmara cattle were used from a herd in which vaccination against LSD was not practised. The heifers were aged about 13 months and around 250 kg in body weight. Two individuals were used as donors (DR1, DR2) and one animal (RR1) was used as a recipient animal. The experiment was conducted in the insect-proofed, high-containment bio-security animal facility of the

University of Pretoria's Biological Research Unit (UPBRC), Faculty of Veterinary Science, Onderstepoort, South Africa. The donor and the recipient animals were housed and handled separately and all experimental procedures were approved by the Animal Use and Care Committee of the University of Pretoria.

Donor animals were infected by both the intravenous and intradermal routes using a virulent South African LSDV field isolate (248/93). The isolate had been passaged 5–6 times on primary bovine dermis cell cultures and was used at a final titre of 5.95 log TCID₅₀/ml. A volume of 2.5 ml of LSDV was inoculated into the jugular vein and 0.25 ml was injected intradermally at four sites on the back of the donor animals. The donors were then monitored closely for clinical signs and body temperatures were recorded daily using a rectal thermometer. Blood samples (EDTA and serum) were collected on days 0, 4, 7, 9, 11, 14, 15, 16, 17, 18, 21, 22, 23, and 24 days post-inoculation (dpi).

'Clean', i.e. uninfected *R. appendiculatus* adult ticks were reared at the Agriculture Research Council's Onderstepoort Veterinary Institute (OVI) in South Africa. The ticks were placed to feed on donor and recipient animals inside cotton cloth bags which were fixed to shaved skin at the base of the ears of the cattle using Genkem Contact Adhesive glue. About 200 *R. appendiculatus* adults were placed in the ear bags to feed on the donor animals (DR1, DR2). To ensure that the feeding of the ticks occurred during viraemia, *R. appendiculatus* adults were placed on the two donor cattle (DR1, DR2) from 4 to 11 dpi. The ticks were then harvested and females and males were separated from each other by eye. Sorted, partially fed male ticks were subsequently transferred to feed on the uninfected recipient animal (RR1) (~70 ticks per ear bag). The time lag between the collection of *R. appendiculatus* from the donor cattle and the placement of ticks to feed on the recipient animal did not exceed 24 h. Due to the interrupted feeding pattern of *R. appendiculatus* males, the actual feeding time of individual males may, however, have significantly varied from tick to tick.

After transfer of the potentially infected *R. appendiculatus* male ticks from the donors, the recipient animal was closely monitored for clinical signs. Body temperature was recorded daily and blood samples (EDTA and serum) were collected on 0, 3, 4, 5, 6, 7, 10, 11, 12, 13, 14, 15, 16, 17, 18, 19, 20, 21, 24 and 26 dpi after the transfer of partially fed ticks. Serum

samples were tested for neutralizing antibodies using a constant-virus/varying-serum neutralization test [8]. The positive control serum, collected at 37 dpi from cattle experimentally infected with LSDV that exhibited severe clinical disease, was produced at the Institute for Animal Health, Pirbright, UK. The negative control serum was collected from uninfected cattle in the UK. Titres were determined as the last dilution that gave a 50% endpoint [8].

The LSDV DNA present in blood samples was quantified using a real-time polymerase chain reaction (PCR) method. Briefly, DNA was extracted using QIAamp[®]All Nucleic Acid kit MDx kit (Qiagen, UK) and robotic extraction techniques (Qiagen BioRobot Universal System). Primers and a probe, designed by Bowden *et al.* [15], were used in combination with a commercially available QuantiFast[™] Probe PCR Kit (Qiagen, UK) in a Mx3005p Multiplex Quantitative PCR system (Stratagene, The Netherlands). This real-time PCR assay targets an 89-bp region within the P32 gene and utilizes forward primer 5'-AAA ACG GTA TAT GGA ATA GAG TTG GAA-3', reverse primer 5'-AAA TGA AAC CAA TGG ATG GGA TA-3' and TaqMan probe 5'-6FAM-TGG CTC ATA GAT TTC CT-MGB/NFQ-3'. The thermal profile was 1 × 50 °C for 2 min, 95 °C for 10 min, and 45 × 95 °C for 15 s and 60 °C for 1 min. Samples were examined with reference to cycle threshold (C_t) values [15, 16].

The donor cattle (DR1, DR2) did not exhibit severe clinical signs of disease at any time-point post-infection, but both animals became viraemic. DR1 had a mild form of LSD but did not develop any skin lesions other than local lesions at the intradermal inoculation sites. DR2 showed multiple lesions in the skin on the side of the neck and on the muzzle and some ulcerative lesions in the mucous membranes of the mouth. No skin lesions were detected in the skin of the ear lobes or at the base of the ears in either donor cattle. Precrural and subscapular lymph nodes were, however, noticeably enlarged in both donor animals.

The two donor cattle (DR1, DR2) became viraemic at 7 and 4 dpi, respectively, and EDTA blood samples from both animals tested positive for LSDV in real-time PCR for up to 24 dpi (Fig. 1). This indicated that the *R. appendiculatus* male ticks had fed on the donor animals during the viraemic period. For both DR1 and DR2 the onset of viraemia was associated with a short peak in body temperatures, but neither had a high fever lasting for more than 2 days (Fig. 2). Both

donor cattle had seroconverted by the end of the experiment (24 dpi).

The recipient animal (RR1) did not develop any visible skin lesions post-infection by partially fed *R. appendiculatus* males. Markedly swollen precrural and subscapular lymph nodes were, however, detected from 6 dpi onwards and the onset of viraemia (measured by PCR) was detected 10 days after the first batch of *R. appendiculatus* males were transferred to it from the donor animals. The incubation period in the recipient animal was consistent with previous reports [17–19]. The onset of the viraemic stage correlated with a transient peak in body temperature (Fig. 2), and the animal remained viraemic until 23 dpi by *R. appendiculatus* ticks (Fig. 1). The difference in C_t values between the donor and recipient animals (Fig. 1) indicated that the level of viraemia in the experimentally infected donor animals was slightly higher than that in the tick-infected recipient animal. However, the incubation period was longer (10 days) in the recipient animal compared to that of each of the donor animals (4 and 7 days). The recipient animal began to seroconvert 20 days after the attachment of the infected *R. appendiculatus* ticks and remained seropositive until the last serum sample was collected at 26 dpi by *R. appendiculatus* ticks. Antibody titres in the recipient animal varied from 1:5 to 1:10, which is typical for animals suffering from mild clinical LSD [5].

The implication that *R. appendiculatus* ticks are able to act as mechanical transfer vectors for LSDV is of significant importance for several reasons, not least the wide distribution and abundance of this species of tick in Africa. Any situation where high densities of cattle come into close contact, such as at watering holes, in *bomas* or in markets, enhances the possibility of *R. appendiculatus* males being transferred between cattle. If environmental and climatic factors are favourable for the survival of ticks, different life stages dropping off from viraemic animals, either accidentally or on purpose, may lead to the contamination of communal pastures by infected ticks, particularly if the transmission of the virus by ticks is biological, but also if the virus is transmitted mechanically. This hypothesis is strengthened by a recent study demonstrating that communal grazing and watering points were significantly associated with the occurrence of LSD [20]. However, the real importance of the transmission of LSDV by tick vectors under field conditions remains to be investigated in detail.

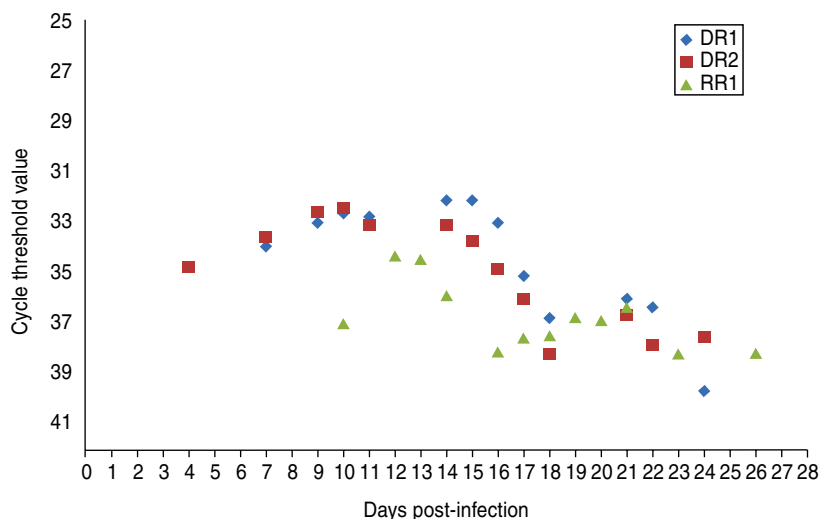


Fig. 1 [colour online]. Real-time polymerase chain reaction results of EDTA blood samples collected from donor animals (DR1, DR2) after experimental infection with lumpy skin disease virus and recipient animal (RR1) after attachment of *Rhipicephalus appendiculatus* males previously fed on donor animals.

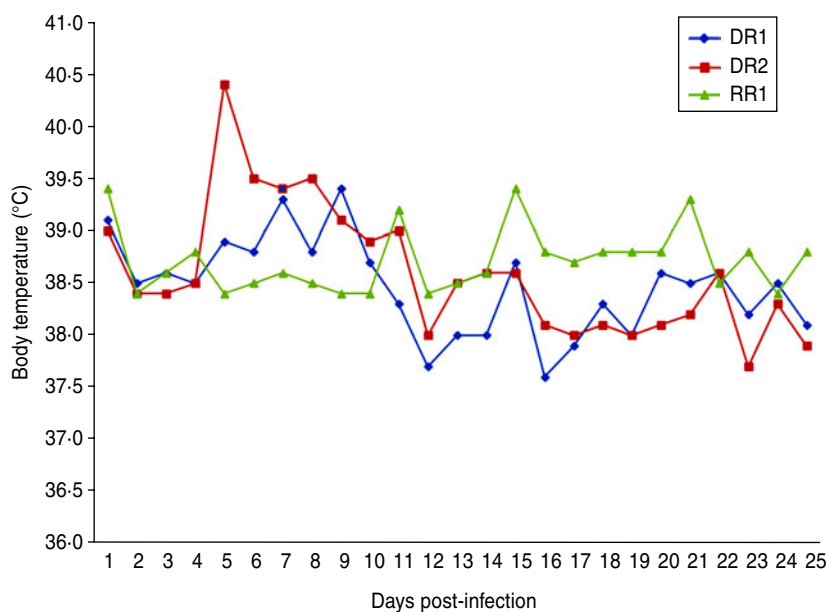


Fig. 2 [colour online]. Body temperature of donor animals (DR1, DR2) after experimental infection with lumpy skin disease virus and recipient animal (RR1) after infection by partially fed *Rhipicephalus appendiculatus* males.

The host range of *R. appendiculatus* is thought to be wide, including, in addition to domestic ruminants, a diverse range of wildlife species, such as African buffalo (*Syncerus caffer*), impala (*Aepyceros melampus*), bushbuck (*Tragelaphus scriptus*), eland (*Taurotragus oryx*), greater kudu (*Tragelaphus strepsiceros*), nyala (*Tragelaphus angasii*) and sable antelope (*Hippotragus niger*) [12]. If any of these wildlife hosts for *R. appendiculatus* were a reservoir for LSDV then situations where domestic cattle share grazing land with wildlife

species would significantly increase the risk of domestic cattle being exposed to LSDV. In a serological study in Kenya LSDV antibody-positive African buffalo were detected in areas adjacent as opposed to distant from LSD outbreaks [21].

The duration of the persistence of LSDV on tick mouthparts following detachment from the infected host requires further investigation. In a recent study LSDV DNA was detected, using a conventional PCR, in the mouthparts of partially fed *R. appendiculatus*

male ticks after feeding on the skin lesions of an experimentally infected donor animal [8]. Further studies are ongoing to investigate both the presence of LSDV in tick salivary glands and the potential for biological transmission of the virus by *R. appendiculatus* through saliva.

Viraemia and seroconversion detected in the recipient animal in this experiment proved the infective nature of the virus when transmitted by the tick vector. *R. appendiculatus* males tested PCR positive after feeding on a second host [8] but further studies are required to investigate how long these males can remain infective.

It is known during vaccination campaigns that all animals do not develop absolute protective immunity against LSDV [22, 23] and that LSD vaccination coverage in many countries, endemic to LSDV, is inadequate to prevent the spread of the disease [20]. The findings of this study emphasize the importance of the implementation of effective tick control programmes as well as vaccination in order to successfully control LSD in endemic areas.

The current study is the first to report the transmission of a poxvirus by *R. appendiculatus* or any other tick species. The number of experimental animals used in this study was, however, insufficient to provide valid statistical data on the transmission of LSDV by tick vectors. Mechanical transmission of LSDV occurred through feeding on normal healthy-looking skin, rather than on skin lesions, which demonstrated that infected animals without skin lesions, may be an important source of infection through mechanical transmission via tick vectors and possibly other insect vectors. Further studies are required in order to investigate the transmission of LSDV by tick vectors in more detail, in particular whether biological as well as mechanical transmission may occur and to determine the infection rate of LSDV in *R. appendiculatus* ticks.

ACKNOWLEDGEMENTS

This collaborative study was between the Department of Veterinary Tropical Diseases, Faculty of Veterinary Science, University of Pretoria, South Africa and the Institute for Animal Health, Pirbright, UK. The authors acknowledge the Combating Infectious Diseases of Livestock for International Development (CIDLID) research programme, the Department of International Biotechnology and Biological Sciences Research Council (BBSRC), the UK Government,

the Department for International Development (DFID) and the Scottish Government (CIDLID project no. BB/H009361/1). We also thank Ms. Rebone Mahlare and Karin Ebersohn for technical assistance and Onderstepoort Veterinary Institute (ARC-OVI) for providing this study with different life stages of *R. appendiculatus* ticks.

DECLARATION OF INTEREST

None.

REFERENCES

1. **Buller RM, et al.** Poxviridae. In: Fauquet CM, Mayo MA, Maniloff J, Desselberger U, Ball LA, eds. *Virus Taxonomy: Eight Report of the International Committee on the Taxonomy of Viruses*. Oxford: Elsevier Academic Press, 2005, pp. 117–133.
2. **Ahmed WM, Zaher KS.** Observations on lumpy skin disease in local Egyptian cows with emphasis on its impact on ovarian function. *African Journal of Microbiology Research* 2008; **2**: 252–257.
3. **Green HF.** Lumpy skin disease: its effect on hides and leather and a comparison on this respect with some other skin diseases. *Bulletin of Epizootic Diseases of Africa* 1959; **7**: 63.
4. **Somasundaram MK.** An outbreak of lumpy skin disease in a Holstein dairy herd in Oman: a clinical report. *Asian Journal of Animal and Veterinary Advances* 2011; **6**: 851–859.
5. **Weiss KE.** Lumpy skin disease virus. *Virology Monographs* 1968; **3**: 111–131.
6. **Kitching RP, Mellor PS.** Insect transmission of capripoxvirus. *Research in Veterinary Science* 1986; **40**: 255–258.
7. **Chihota CM, et al.** Mechanical transmission of lumpy skin disease virus by *Aedes aegypti* (Diptera: Culicidae). *Epidemiology and Infection* 2001; **126**: 317–321.
8. **Tuppurainen ESM, et al.** A potential role for ixodid (hard) tick vectors in the transmission of lumpy skin disease virus in cattle. *Transboundary and Emerging Diseases* 2011; **58**: 93–104.
9. **Carn VM, Kitching RP.** An investigation of possible routes of transmission of lumpy skin disease virus (Neethling). *Epidemiology and Infection* 1995; **114**: 219–226.
10. **Magori-Cohen R, et al.** Mathematical modelling and evaluation of the different routes of transmission of lumpy skin disease virus. *Veterinary Research* 2012; **43**: 1.
11. **Irons PC, Tuppurainen ESM, Venter EH.** Excretion of lumpy skin disease virus in bull semen. *Theriogenology* 2005; **63**: 1290–1297.
12. **Norval R, Horak I.** Vectors: ticks. In: Coetzer J, Tustin R, eds. *Infectious Diseases of Livestock*, 2nd edn.

- Cape Town: Oxford University Press Southern Africa, 2004, pp. 3–42.
13. **Wang H, Henbest PJ, Nuttall PA.** Successful interrupted feeding of adult *Rhipicephalus appendiculatus* (Ixodidae) is accompanied by reprogramming of salivary gland protein expression. *Parasitology* 1999; **119**: 143–149.
 14. **Wang H, et al.** Male ticks help their mates to feed. *Nature* 1998; **391**: 753–754.
 15. **Bowden TR, et al.** Capripoxvirus tissue tropism and shedding: a quantitative study in experimentally infected sheep and goats. *Virology* 2008; **371**: 380–393.
 16. **Stubbs S, et al.** Validation of a high-throughput real-time polymerase chain reaction assay for the detection of capripoxviral DNA. *Journal of Virological Methods* 2012; **179**: 419–422.
 17. **Babiuk S, et al.** Quantification of lumpy skin disease virus following experimental infection in cattle. *Transboundary and Emerging Diseases* 2008; **55**: 299–307.
 18. **Coetzer JAW.** Lumpy skin disease. In: Coetzer JAW, Tustin RC, eds. *Infectious Diseases of Livestock*, 2nd edn. Cape Town: Oxford University Press Southern Africa, 2004, pp. 1268–1276.
 19. **Tuppurainen ESM, Venter EH, Coetzer JAW.** The detection of lumpy skin disease virus in samples of experimentally infected cattle using different diagnostic techniques. *Onderstepoort Journal of Veterinary Research* 2005; **72**: 153–164.
 20. **Gari G, et al.** Risk factors associated with observed clinical lumpy skin disease in Ethiopia. *Epidemiology and Infection* 2010; **138**: 1657–1666.
 21. **Davies FG.** Observations on the epidemiology of lumpy skin disease in Kenya. *Journal of Hygiene (London)* 1982; **88**: 95–102.
 22. **Brenner J, et al.** Appearance of skin lesions in cattle populations vaccinated against lumpy skin disease: Statutory challenge. *Vaccine* 2009; **27**: 1500–1503.
 23. **Kitching RP.** Vaccines for lumpy skin disease, sheep pox and goat pox. *Vaccines for OIE List A and Emerging Animal Diseases. Proceedings of a symposium.* Ames, Iowa, USA, 16–18 September 2002; 2003, pp. 161–167.