

Image 2:

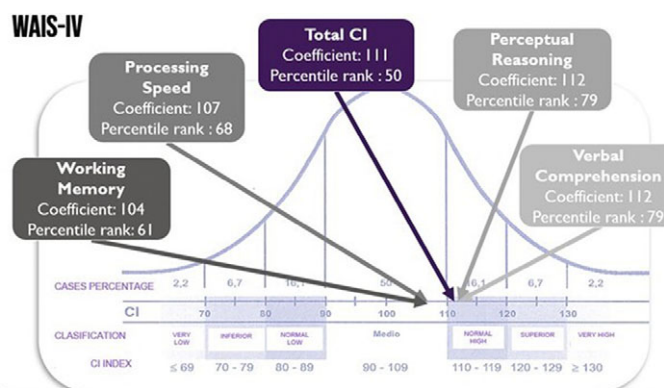


Figure 2. Wechsler Adult Intelligence Scale | Fourth Edition

Conclusions: Neurocognitive alterations are one of the most frequent manifestations of neurolupus, although its diagnosis and treatment may be delayed in the absence of clinical suspicion, mainly in multi-comorbid patients.

In the case, the patient presented multiple diseases that can explain a picture of neurocognitive impairment, such as epilepsy, depression, hypothyroidism. However, in these cases, a multidisciplinary approach is imperative, requiring to rule out the different causes of the patient's symptoms.

Disclosure of Interest: None Declared

EPV0813

Subpopulation composition of monocytes and inflammation markers in schizophrenia

S. A. Zozulya^{1*}, Z. V. Sarmanova¹, I. N. Otman¹, I. V. Oleichik² and T. P. Klyushnik¹

¹Laboratory of Neuroimmunology and ²Department of Endogenous Mental Disorders and Affective States, Mental Health Research Centre, Moscow, Russian Federation

*Corresponding author.

doi: 10.1192/j.eurpsy.2023.2117

Introduction: Taking into account the role of the immune system in the pathogenesis of schizophrenia, it is important to study the peculiarities of innate immunity in the development of the disease. A special role in these processes belongs to monocytes, which play an integral role in the inflammatory reactions and perform regulatory and effector functions to other immunocytes.

Objectives: To analyze the subpopulation composition of monocytes and other inflammatory markers in patients with schizophrenia

Methods: The study included 36 women with schizophrenia (F20, ICD-10) (30±12 years) in the acute stage of the disease and 20 healthy donors. Flow cytometry was used to determine the relative number of monocyte subpopulations. The activity of leukocyte elastase (LE) and α 1-proteinase inhibitor (α 1-PI) in blood was determined by spectrophotometric method. The level

of autoantibodies to S100b and CRP concentration were assessed by ELISA.

Results: A decrease in "classical" monocyte subpopulation ($p=0.02$) was accompanied by an increase in cells of the pro-inflammatory phenotype ($p=0.03$) "Transitional" and "non-classical" subpopulations did not differ from controls. A negative correlation was found between the proportion of "classical" monocytes with "transitional" and "intermediate" cells ($r=-0.66$ and $r=-0.54$, $p=0.01$). All inflammatory and autoimmune blood markers in patients were significantly elevated compared to controls ($p<0.05$).

Conclusions: The redistribution of the subpopulation composition of monocytes with an increase in "intermediate" subpopulation and an increase in other immune markers in the acute stage of schizophrenia serve as an additional link confirming the involvement of cellular immunity in the pathogenesis of the disease.

Disclosure of Interest: None Declared

EPV0814

Haloperidol-induced facial and upper limbs oedema: a case report study

S. Khayeche*, B. saguem, R. majdoub and J. nakhli psychiatry, Farhat Hached hospital, sousse, Tunisia

*Corresponding author.

doi: 10.1192/j.eurpsy.2023.2118

Introduction: Haloperidol is one of the first-generation anti-psychotics which is used widely around the world and still has its place in psychotic disorders along with his documented antimanic properties.

It acts by blocking essentially dopaminergic receptors but also serotonergic and alpha-adrenergic receptors.

Haloperidol has many side effects, especially extrapyramidal symptoms. Oedema associated with haloperidol is a rare side effect.

Objectives: The aim of this presentation is to describe the case of a young female who developed a rare side effect of haloperidol.

Methods: we conducted a review of literature on different data base about this side effect in order to discuss its potential underlying mechanisms.

Results: Here we report a case of a 24-year-old female with the history of bipolar disorder type 1, and an allergy to chlorpromazine. She was admitted to our psychiatric department for a manic episode with psychotic features and was initially treated with 50 mg of Haloperidol in addition to 30 mg of valium per day. She developed pronounced oedema of the face and upper limbs after two weeks of treatment. All of the paraclinical examinations including blood cell count, liver function tests, renal function tests, serum electrolytes, ECG, urine test didn't show any abnormalities. We solicited the opinion of both nephrology and pharmacovigilance and concluded to an allergic oedema.

The symptoms disappeared 10 days after the discontinuation of haloperidol which suggested a potential incrimination of this drug As far as we know, there are very few reports of allergic oedema with haloperidol in the literature. Potential underlying mechanisms will be discussed.

Conclusions: Through this case study, we aimed to focus attention on this very rare but still possible side effect.

Disclosure of Interest: None Declared