

## Main Article

Haytham Kubba takes responsibility for the integrity of the content of the paper

**Cite this article:** Barbour A, Penman D, Kubba H. Prevalence of thyroid gland tissue in midline neck dermoid cysts in children and a proposed new 'thyroglossal entrainment' hypothesis for their formation. *J Laryngol Otol* 2024;**138**:448–450. <https://doi.org/10.1017/S0022215123001792>

Received: 31 July 2023

Revised: 19 September 2023

Accepted: 23 September 2023

First published online: 5 October 2023

### Keywords:


Thyroglossal duct cyst; dermoid cyst; children

### Corresponding author:

Haytham Kubba;

Email: [haytham.kubba@glasgow.ac.uk](mailto:haytham.kubba@glasgow.ac.uk)

# Prevalence of thyroid gland tissue in midline neck dermoid cysts in children and a proposed new 'thyroglossal entrainment' hypothesis for their formation

Amy Barbour<sup>1</sup>, Dawn Penman<sup>2</sup> and Haytham Kubba<sup>1</sup> 

<sup>1</sup>Department of Paediatric Otolaryngology, Royal Hospital for Children, Glasgow, Scotland, UK and <sup>2</sup>Department of Pathology, Royal Hospital for Children, Glasgow, Scotland, UK

## Abstract

**Background.** Thyroglossal duct cysts and dermoid cysts both commonly present as midline neck lumps in children. They are treated as separate entities with different embryological origins. There are isolated reports of thyroid gland tissue in a dermoid cyst, concurrent thyroglossal and dermoid cysts, and cysts with mixed histology. It is not known if these are rare or common.

**Methods.** All children undergoing excision of a congenital midline neck cyst between January 2017 and December 2022 were identified. Histopathology slides were reviewed in detail.

**Results.** In 53 children, there were 26 thyroglossal duct cysts, 24 dermoids, 1 lymph node and 2 with no diagnostic material identified. Five dermoids (28 per cent) had associated thyroid gland tissue, and 1 (4 per cent) had hybrid histology with keratinising and respiratory epithelium. Infection occurred in 17 per cent of dermoids prior to excision and 8 per cent of dermoids recurred after excision.

**Conclusion.** Hybrid histology, infection and recurrence are all common in midline neck dermoids. A new theory for their embryological origin is proposed, with the suggestion that some may need more extensive surgery.

## Introduction

A midline neck lump is a common presentation in childhood. They are usually congenital cysts, either thyroglossal duct cysts or dermoid cysts, and these are considered to be completely separate clinical and pathological entities.

Thyroglossal duct cysts arise from remnants of the embryonic thyroglossal tract, formed as the thyroid gland descends from the foramen caecum of the tongue base to its adult position in the lower neck.<sup>1</sup> They are variably lined with respiratory epithelium, cuboidal epithelium or non-keratinising stratified squamous epithelium. Because they are potentially connected to the oropharynx via a patent thyroglossal tract, the infection rate is high. Recurrence is common unless a wide excision in normal tissue is performed, with en bloc resection of the pre-tracheal fascia, part of the hyoid bone and tongue base muscle.

Dermoid cysts, in contrast, are lined with keratinising stratified squamous epithelium. They have a very low risk of infection. Simple excision of the cyst is all that is usually required and recurrence is uncommon. It is generally accepted that they form as epithelial inclusions along lines of tissue fusion in the embryo.<sup>2</sup>

A recent paper from Australia<sup>3</sup> reported thyroid gland tissue in the wall of a midline neck dermoid cyst. The authors suggested that dermoid and thyroglossal duct cysts may not be so completely pathologically distinct, although they stopped short of suggesting how they might be linked.

We have reviewed our recent experience of midline neck dermoid cysts in children in order to identify how often such cysts are associated with foci of ectopic thyroid gland tissue, and we propose a novel embryological theory for how such hybrid cysts might form.

## Materials and methods

### Ethical considerations

This work is an anonymised, retrospective review of hospital records. In our institution, no formal ethics committee approval is required for such a study.

### Study population

A list of all children undergoing surgical excision of a congenital midline neck cyst at the Royal Hospital for Children, Glasgow, between 1 January 2017 and 31 December 2022,

was compiled from the hospital’s operating theatre database. For each child, the electronic medical record was reviewed to extract basic clinical information.

**Histological analysis**

All histological specimens were retrieved from the archive, and every section was carefully re-examined by an experienced paediatric pathologist. Cysts with sebaceous contents and keratinising stratified squamous epithelium with associated skin adnexa were classified as dermoids. Those with mucinous contents and respiratory, cuboidal or non-keratinising stratified squamous epithelium were classified as thyroglossal cysts.

**Results**

We identified 53 children who had a midline neck cyst surgically removed at the Royal Hospital for Children, Glasgow, between 1 January 2017 and 31 December 2022. The children were aged 1–16 years (median, 4 years) at the time of surgery and 24 (45 per cent) were female. Of the 53 specimens, 1 was a lymph node and 2 had no identifiable cyst material in the specimen (as a result of post-infection fibrosis).

Of those with identifiable congenital cysts, 20 were originally reported as dermoid cysts (40 per cent) and 30 as thyroglossal cysts (60 per cent). After re-examination for the purpose of this study, 4 thyroglossal cysts were reclassified as dermoid, giving a final total of 24 dermoid cysts (48 per cent) and 26 thyroglossal cysts (52 per cent). No other changes to diagnosis were made. The anatomical locations of the cysts are shown in Table 1.

In five of the children (21 per cent), ectopic thyroid gland tissue was identified in close association with the dermoid cyst. An example is shown in Figure 1. In addition, one child had a hybrid appearance on histology, with keratinising stratified squamous epithelium and eccrine glands visible in the more superficial part of the specimen and some respiratory epithelium deeper within the specimen (Figure 2).

Of the 24 dermoid cysts, 4 (17 per cent) had episodes of infection prior to surgical excision, including 2 of the 5 cysts with associated thyroid tissue (20 per cent). The four cases of infection occurred at one, two, two and four years of age. Two of the 24 dermoids (8 per cent) recurred after excision, at 5 and 26 months post-operatively; 1 of these recurrences was the cyst with the hybrid histology.

**Discussion**

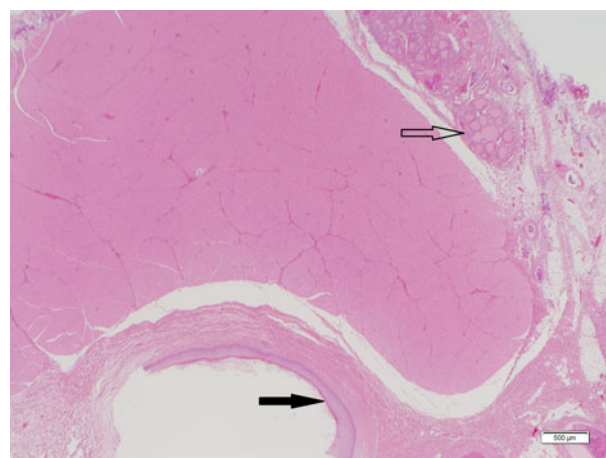
**Study strengths**

Chandiok and colleagues<sup>3</sup> reported a single case of ectopic thyroid gland tissue found in close association with a midline

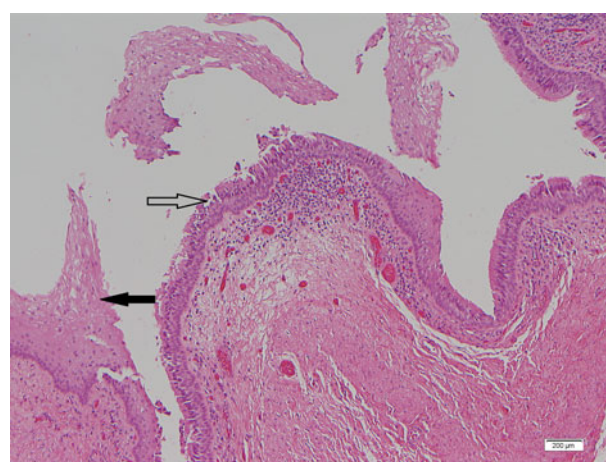
**Table 1.** Location of the cysts

Location	Dermoid cyst	Thyroglossal cyst	Total
Submental	2	2	4
Hyoid	9	11	20
Thyroid cartilage	8	10	18
Cricoid	1	2	3
Sternal notch	4	1	5
Total	24	26	50

Data represent numbers of cysts at each location



**Figure 1.** Histopathological section showing dermoid cyst (closed arrow) with associated thyroid gland tissue (open arrow). (H&E; ×10)



**Figure 2.** Histological section showing a section of the lining of a cyst with epithelium, which transitions from respiratory (open arrow) to keratinising stratified squamous (closed arrow). (H&E; ×10)

cervical dermoid cyst; however, ours is the first attempt to identify whether such findings are rare or common. We found thyroid tissue to be present in 28 per cent of our series, so it cannot be considered uncommon. Other authors have reported dermoid and thyroglossal cysts occurring together,<sup>4–7</sup> or cysts with mixed thyroglossal and dermoid features on histology.<sup>8–10</sup> This latter finding was also present in one case in our series and so it is also not rare. We suspect that these findings are common but not seen as important or clinically relevant, and are therefore not reported.

The fact that pathologists do not always agree on whether a cyst is thyroglossal or dermoid in nature, with 4 out of 50 (8 per cent) in our series being reclassified on closer re-examination, is also interesting. It is possible that, for many pathologists, the important consideration is to exclude cancer; once that has been done and the lesion is shown to be a congenital cyst then the exact nature of the cyst may be seen as a minor issue of only academic concern. Pathologists may not appreciate the importance to surgeons of distinguishing between dermoid and thyroglossal cysts. Better communication between surgeons and pathologists would lead to more detailed reporting.

**Proposed ‘thyroglossal entrainment’ theory**

Taking our findings in conjunction with these previous reports, we believe it is worth considering an alternative to

the usual assumption that dermoid cysts always form as a result of epithelial entrapment during early fetal life. We propose that at least some midline neck dermoids occur when ectoderm from the tongue base is pulled down by descent of the thyroid gland, leading to a dermoid cyst occurring along the course of the thyroglossal tract. As the tongue is covered with both keratinising and non-keratinising stratified squamous epithelium in the areas around the foramen caecum, it is quite reasonable to suggest that different types of cyst may occur depending on which epithelium is entrained by the descending thyroglossal tract. Thyroglossal duct cysts and some dermoid cysts in the midline of the neck may therefore be considered as being on a spectrum, rather than as totally discrete pathological entities.

Previous authors<sup>8</sup> have suggested an alternative hypothesis, in which mixed thyroglossal-dermoid histology occurs because of areas of squamous metaplasia in thyroglossal duct cysts. We believe that our 'thyroglossal entrainment' hypothesis provides a better, more complete explanation for all the unusual combinations of histology identified by reports, including the presence of ectopic thyroid tissue in dermoid cysts,<sup>3</sup> the presence of mixed thyroglossal-dermoid histology in some lesions,<sup>8–10</sup> and the presence of thyroglossal and dermoid cysts within the same patient.<sup>4–7</sup>

- Midline neck lumps are common in children; these are usually thyroglossal duct or dermoid cysts, considered clinically and pathologically separate, with different embryological origins
- There have been isolated reports of hybrid pathologies, suggesting some degree of overlap between these entities; it is not known if these are rare or common findings
- In 50 children with congenital midline neck cysts, there were 24 dermoids, of which 5 had associated thyroid gland tissue, and 1 had hybrid histology with both keratinising and respiratory epithelium
- Infection occurred in 17 per cent of dermoids prior to excision, and 8 per cent of dermoids recurred after excision
- A novel 'thyroglossal entrainment' hypothesis is proposed for the formation of some midline neck dermoids
- It is suggested that patients with prior dermoid infection or recurrence after simple excision be considered for more extensive surgery to remove any associated thyroglossal tract

### Implications for clinical practice

There may be some cases where a dermoid has formed from entrainment by a descending thyroglossal tract; if the tract remains patent at the foramen caecum, there is a much higher risk of both infection and recurrence after surgery, as there would be for a thyroglossal duct cyst. Surgeons are usually

taught that it is rare for dermoid cysts to be infected prior to surgery, or for them to recur after excision, but both occurred in our series with surprising frequency (17 per cent infection before surgery, 8 per cent recurrence after surgery). The majority of dermoid cysts are adequately treated by simple excision and so we do not agree with those authors who suggest a wide excision for all midline neck dermoids,<sup>8</sup> but rather only for selected difficult cases. Perhaps we should be considering whether a wide excision from the thyroid isthmus to the foramen caecum, as would be performed for a thyroglossal duct cyst, would be a more appropriate intervention than simple excision of the cyst in cases where a dermoid cyst recurs, or in cases with previous infection. We would also suggest that cases with hybrid histology should be carefully followed up for evidence of recurrence.

**Acknowledgement.** The authors would like to thank Karen Browning for providing a list of patients from the operating theatre database.

**Data availability statement.** The data that support the findings of this study are available from the corresponding author upon reasonable request.

**Competing interests.** None declared

### References

- 1 Chou J, Walters A, Hage R, Zurada A, Michalak M, Tubbs RS *et al.* Thyroglossal duct cysts: anatomy, embryology and treatment. *Surg Radiol Anat* 2013;**35**:875–81
- 2 Reissis D, Pfaff MJ, Patel A, Steinbacher DM. Craniofacial dermoid cysts: histological analysis and inter-site comparison. *Yale J Biol Med* 2014;**87**:349–57
- 3 Chandio K, Zhang M, Sulaiman B, Thomson N. Dermoid cyst or thyroglossal duct cyst? A histopathological complexity. *ANZ J Surg* 2023;**93**:381–3
- 4 Haar JG, Boulos EJ, Sadeghi MH, Sheffer J. Association of a thyroglossal duct cyst and a dermoid cyst in the neck, a case report. *Ann Otol* 1981;**90**:181–2
- 5 Bhansali SA, Chang C, Hotaling AJ. Epidermoid cyst and thyroglossal duct cyst. *Arch Otolaryngol Head Neck Surg* 1989;**115**:752–5
- 6 Drucker C, Gerson CR. Sublingual contiguous thyroglossal and dermoid cysts in a neonate. *Int J Pediatr Otorhinolaryngol* 1992;**23**:181–6
- 7 Lin RJ, Moxham JP, Chadha NK. Concurrent thyroglossal duct cyst and dermoid cyst in two pediatric patients. *Int J Pediatr Otorhinolaryngol Extra* 2012;**7**:196–9
- 8 DeMello DE, Lima JA, Liapis H. Midline cervical cysts in children: thyroglossal anomalies. *Arch Otolaryngol Head Neck Surg* 1987;**113**:418–20
- 9 Phillips PS, Ramsay A, Leighton SEJ. A mixed thyroglossal cyst. *J Laryngol Otol* 2004;**118**:996–8
- 10 Sathish C, Nyamannawar BM, Mohanty S. Atypical thyroglossal duct anomalies. *Int J Pediatr Otorhinolaryngol* 2008;**72**:1353–7